



## Original Research Article

## A clinical study of surgical management of tendoachilles rupture by various modalities

Banna Kiran Kumar<sup>1</sup>, Shenkeshi Sirish Kumar<sup>1</sup>, Bolloju Keshava Rao<sup>1,\*</sup>,  
K Kishore Kumar<sup>1</sup>, J Venkateswarlu<sup>1</sup>

<sup>1</sup>Dept. of Orthopaedics, Kakatiya Medical College & MGM Hospital, Warangal, Telangana, India



## ARTICLE INFO

## Article history:

Received 12-01-2021

Accepted 16-03-2021

Available online 24-11-2021

## Keywords:

Achilles tendon

Paratenon

Raghu ram technique

## ABSTRACT

**Background:** Acute injuries to Achilles tendon with open wounds in Tendo Achilles region is more common unlike the west, where the chronic ruptures and sport injury are more common. This is because most Indians use Indian squatting type of toilets which are common cause of open injury to Achilles tendon (closet injury).

**Aim & Objective:** This study aims to evaluate the outcomes of surgical management of Tendo Achilles rupture.

**Materials and Methods:** It is a prospective observational study, of 21 patients with Achilles tendon ruptures treated in the Department of Orthopaedics, Mahatma Gandhi Memorial Hospital, Kakatiya Medical College, Warangal, Telangana, India, between June 2019 to December 2020.

**Results:** Achilles tendon ruptures are more common in males. In elderly people, Tendo Achilles ruptures occurred most commonly due to trivial trauma. Most ruptures occur 2-6cm proximal to the calcaneal insertion of the tendon. Risk factors for Tendo Achilles rupture are usage of quinolone antibiotics, steroid, and are also seen in patients with diabetes, gout and rheumatoid arthritis. Primary surgical management if done well, produces good functional outcome without any functional deficit and chronic pain. Raghuram technique is safe and good method for chronic ruptures. Post operative evaluation is necessary in assessing final outcome with various scoring system including ultrasound and dynamometric studies.

**Conclusion:** 6 months after surgery following adequate immobilization and effective physiotherapy, unrestrained activity can be done. Patients can stand on tip toes and complete plantar flexion is achieved. Inadequate paratenon closure leads to delayed wound healing and increased rate of infection.

This is an Open Access (OA) journal, and articles are distributed under the terms of the Creative Commons Attribution-NonCommercial-ShareAlike 4.0 License, which allows others to remix, tweak, and build upon the work non-commercially, as long as appropriate credit is given and the new creations are licensed under the identical terms.

For reprints contact: [reprint@ipinnovative.com](mailto:reprint@ipinnovative.com)

### 1. Introduction

The Achilles tendon formed by tendinous contributions from Gastrocnemius and soleus, is the largest and strongest tendon in the body. It resists forces up to 2.6kN, but in spite of its tensile strength, it frequently gets injured. The loss of tendon leads to poor push off. It plays a crucial role in the bipedal human beings.<sup>1-6</sup>

Achilles Tendon rupture are the most common tendon rupture of lower extremity. Etiology of tendon injury is multifactorial. 75% of all the injuries occur during sporting (racquet sports dominates) Given the broad array of critical functions that it helps to provide, injury to Achilles Tendon can be devastating. The profound disabilities like weak plantar flexion with deficit push off and flat foot gait will alter the energy expenditure. Also flat foot leads to foot strain and tarsal arthritis. Treatment of Achilles tendon rupture was first reported in literature by Ambrose Pare in 1575. The primary goals of the management of acute

\* Corresponding author.

E-mail address: [drbkeshav@gmail.com](mailto:drbkeshav@gmail.com) (B. K. Rao).

Achilles tendon ruptures are to ensure a rapid return to full function and to prevent complications.

These are minimized by: following strict asepsis, atraumatic technique, use of less irritant suture material, and with meticulous soft tissue handling.<sup>6–8</sup>

### 1.1. Aims and objectives of the study

To study the results of surgical management of Tendo Achilles rupture

1. Time required for healing of ruptured Achilles tendon.
2. Range of plantar flexion of foot.
3. Rate of delayed healing or Re-rupture.
4. Rate of functional deficit and chronic pain.

## 2. Materials and Methods

In this prospective study, 21 patients, who attended the OPD and emergency room of MGM Hospital (affiliated to Kakatiya medical college) Warangal, and diagnosed as Tendo Achilles rupture were admitted and included in this study done between June 2019 to Dec 2020.

This study was undertaken to evaluate the cause, the clinical course, surgical management and functional outcomes of injury to Tendo Achilles.

Study included 15 males, 6 females with acute, neglected and compound Tendo Achilles rupture. The rupture was classified as early when rupture is less than 4 weeks and delayed when rupture is more than 4 weeks.

Typically patient present with pain, struck from behind, popping sound and inability to walk. Signs of ruptured tendon include limping, altered gait, palpable gap in the continuity of the tendon, plantar flexion weakness.

### 2.1. Diagnosis

According to the AAOS clinical practice guidelines, the diagnosis of acute Achilles tendon rupture is established by two or more of the following physical examination test:

1. Positive Thompson's test.
2. Decreased plantar flexion strength.
3. Presence of a palpable gap.
4. Increased passive ankle dorsiflexion with gentle manipulation.

Other tests in vogue include Matles test, O'Brien's needle test.

### 2.2. Imaging

Diagnosis of acute Achilles tendon rupture is primarily clinical, supported by imaging tests

Plain X-ray of the ankle with leg (lateral view) is taken to study for calcaneal exostosis, calcification and avulsed tendon and to rule out other ankle problems.

### 2.3. Ultrasonography

Ultrasonography examination of heel is done to note the quality, integrity of tendon fibres, hematoma, calcification and Gap.

### 2.4. Pre-operative instructions

The patient is explained about surgery, post-operative protocol and rehabilitation and taken up to surgery. Routine blood investigations are performed for preparation of anesthesia.

#### 2.4.1. Surgical steps of Raghuram et al technique

### 2.5. Surgical procedures

Surgical technique we have followed depending on type of injuries whether injury is compound or simple, rupture is acute or neglected.

At the time of surgery after the preparation, the patient is put in prone position. The incision is posterior central with slight medial deviation at the calcaneal tuberosity.

The tendon is studied for the level of rupture, the length of distal stump and the gap in the tendon is noted. Tendon ends are freshened and mobilized.

In 15 tendon rupture cases, end to end repair with Krackow sutures is done. In 4 cases, tendon repair is done with Raghuram technique with aponeurosis taken and passed through calcaneum and in remaining two cases repair was done through pull through technique.

After repair of tendon the paratenon surrounding the Achilles tendon is repaired and the wound is closed in layers. Sterile dressing is applied, a short leg cast with foot in 20° plantar flexion is applied.

### 2.6. Post-operative management

In the immediate post operative period, the patient is administered parenteral broad spectrum antibiotics and analgesics. Periodic wound inspection is done through the window in the cast. Sutures are removed between 12<sup>th</sup> - 14<sup>th</sup> post operative day. Limb is immobilized in B/K (Below Knee) cast for a maximum duration of 3 weeks.

**Follow up protocol :** patients were instructed at the time of discharge to review at OPD every 1 month for initial 3 months, and thereafter every 3 months for a period of 18 months. Functional outcomes were evaluated using leppilahti score.<sup>9</sup>

## 3. Results

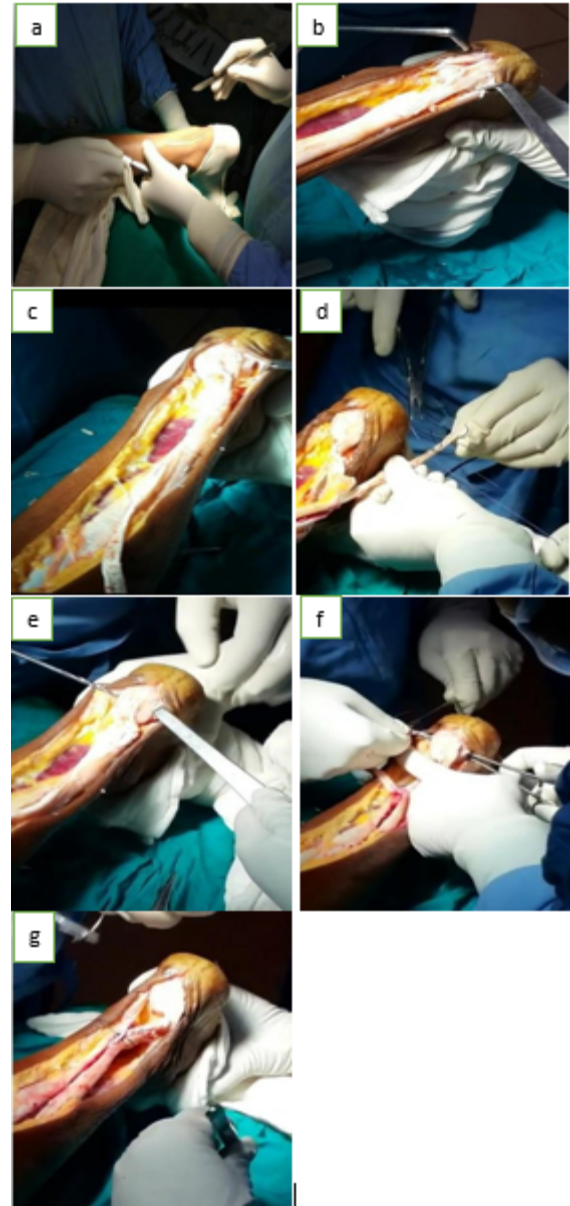
Total number of patients with rupture studied were 21

### 3.1. Duration of study

June 2019 to Dec 2020

**Table 1:** Leppilahti score

Clinical factor	Points
Pain	15
None	10
Mild, no limitations in recreational activities	5
Moderate, limitations in recreational, but not daily activities	0
Severe, limitations in recreational and daily activities	
Stiffness	15
None	10
Moderate, limitations in recreational, but not daily activities	5
Severe, limitations in recreational and daily activities	0
Calf muscle weakness	
None	15
Mild, no limitations in recreational activities	10
Moderate, limitations in recreational, but not daily activities	5
Severe, limitations in recreational and daily activities	0
Footwear restrictions	
None	10
Mild, most shoes tolerated	5
Moderate, unable to tolerate fashionable shoes, modified shoes tolerated	0
Active range of motion difference between ankles	
Normal (<6 degrees)	15
Mild (6 to 10 degrees)	10
Moderate (11 to 15 degrees)	5
Severe (>15 degrees)	0
Subjective results	
Very satisfied	15
Satisfied with minor reservations	10
Satisfied with major reservations	5
Dissatisfied	0
Isokinetic muscle strength (score)	
Excellent	15
Good	10
Fair	5
Poor	0
Leppilahti score	
Excellent	90-100
Good	75-89
Fair	60-74
Poor	<60



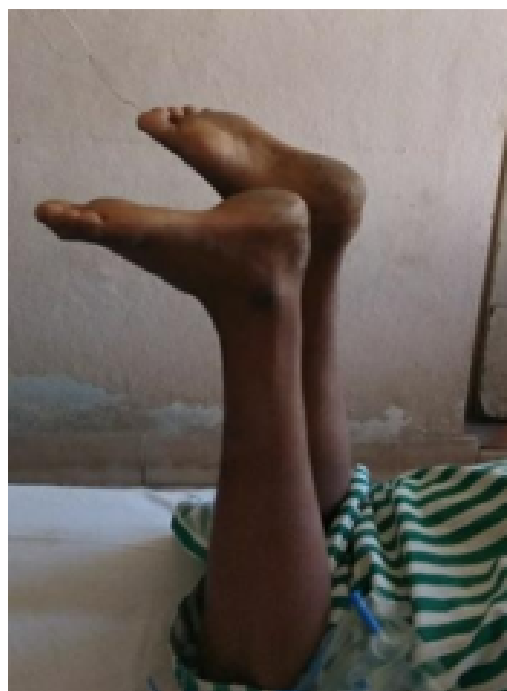**Fig. 1:** a: Surgical steps in Tendo Achilles repair; a: Surgical incision; b: Exposed parts; c: Isolated aponeurosis; d: Making aponeurosis into cord; e: Making hole in calcaneum; f: Passing cord through calcaneum; g: Suturing to proximal part

**Table 2:** Sex incidence

Sex	No. of cases	Percentage
Males	16	76.19
Females	5	23.81

**Table 3:** Age incidence:

Age	No. of cases	Percentage
21-30	6	28.57
31-40	6	28.57
41-50	4	19.04
51-60	2	9.52
61-70	3	14.28



### Preoperative

Fig. 2: Preoperative clinical photo

Table 5: Clinical evaluation

Clinical features	No. of cases	Percentage
Skin changes	4	19.04
>20% difference in calf measurement	6	28.57
>3cm palpable Gap in tendon	5	23.80
Weakness of plantar flexion	18	85.71

Table 6: Site of Rupture:

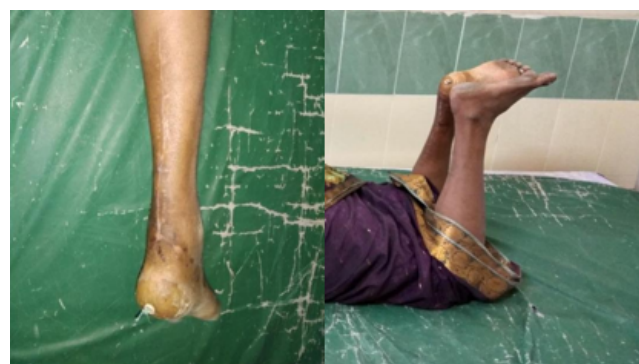Zone	No. of cases	Percentage
Zone 1	6	28.57
Zone 2	14	66.66
Zone 3	1	4.76

Table 7: Complications:

Complications	No. of cases	Percentage
Wound dehiscence	1	4.76
Infection	3	14.28
Scar hypertrophy	2	9.52

Table 8: Functional outcomes (Leppilahati score)

Functional outcome	No. of cases	Percentage
Excellent	14	66.66
Good	4	19.04
Fair	1	4.76
Poor	2	9.52



Immediate Postop

After 2 months

Fig. 3: Postoperative clinical photograph

Table 4: Aetiology

Aetiology	No. of cases	Percentage
Stepping into commode hole	10	47.61
Blunt and penetrating injury	4	19.04
Trivial trauma	7	33.33

### 4. Discussion

In our series, majority of cases were seen in age group of 21-40 years. There are 2 patients in age group between 51-60 years and 3 patients in >61 years age group.

Number of males were 16 (76.19%) and females were 5 (23.80%). The most common cause that led to Tendo Achilles rupture in our series was sudden forceful dorsiflexion at ankle due to stepping into the commode followed by trivial trauma in 7 (33.33%) patients.

There were 7 cases of rupture due to trivial trauma above 40 years age group without any history of local steroid injection.

In our study, there were 13 cases of compound Tendo Achilles rupture, of which 10 cases were due to stepping into the commode hole and 2 cases were due to road traffic accident and 1 due to sharp instrument injury.

In our series, 15 cases presented within 4 weeks of trauma and 6 cases presented after 4 weeks. According to Allen et al,<sup>10</sup> it was called early repair when presented before 4 weeks.

Most patients complained of pain and disturbances in gait which was mainly due to inability to plantar flex during gait cycle.

Thompson Test was positive in almost all cases but it loses its efficacy after one week because plantar flexion may result from other plantar flexors or bridging fibrous tissue. There was difference in calf muscle measurement after prolonged period due to relative inactivity of gastrosoleus. Weakness of plantar flexion was seen in almost all cases due to absence of gastrosoleus action.<sup>11–14</sup>

In our series, rupture are more commonly (66.66%) seen in zone 2 (Lindholm).

In patients, who presented to the hospital more than 4 weeks after the injury, we have repaired with Raghuram technique.

Among all the complications there was no re-rupture till date. There was increased incidence of infection and delayed wound healing in distal part of the wound. This was due to inadequate paratenon closure and increased plantar flexion postoperatively, which resulted in crumpling of skin which leads to delayed wound healing.<sup>14</sup>

We achieved good to excellent results in 86% patients with surgical repair in all types of ruptures.

## 5. Conclusion

Primary surgical management if done well produces good functional outcome without any functional deficit and chronic pain. Raghuram et al technique is safe and good method for chronic ruptures. Post operative evaluation is necessary in assessing final outcome including ultrasound and dynamometric studies.

## 6. Acknowledgment

The author is thankful to Department of Orthopaedics for providing all the facilities to carry out this work.

## 7. Conflict of Interest

The authors declare that there are no conflicts of interest in this paper.

## 8. Source of Funding

None.

## References

1. Diab M. Lexicon of Orthopaedic Etymology. Singapore: Harwood Academic Publishers; 1999.
2. Kirkup J, Chapter. Mythology and history. In: Helal B, Wilson D, editors. The Foot. Edinburgh: Churchill Livingstone; 1999.
3. Pare A. Workes. (Translated by T. Johnstone.). London.; p. 1665.
4. The Workes of that Famous Chirurgion Ambrose Parey. (Translated out of Latin and compared with the French by T. London: Richard Cotes.; p. 1649.
5. Arner O, Lindholm A. Subcutaneous rupture of the Achilles tendon; a study of 92 cases. *Acta Chir Scand Suppl.* 1959;116(239):1–51.
6. Leppilahti J. Achilles tendon rupture with special reference to epidemiology and results of surgery. Thesis, University Oulu, Finland. of Oulu; 1996.
7. Maffulli N. Rupture of the Achilles tendon. *J Bone Joint Surg Am.* 1999;81(7):1019–36. doi:10.2106/00004623-199907000-00017.
8. Hattrup SJ, Son KAJ. A review of ruptures of the Achilles tendon. *Foot Ankle.* 1985;6(1):34–8. doi:10.1177/107110078500600107.
9. Leppilahti J, Puranen J, Orava S. Incidence of Achilles tendon rupture. *Acta Orthop Scand.* 1996;67(3):277–9. doi:10.3109/17453679608994688.
10. Allen E, Turk JL, Murley R. The Case Books of John Hunter FRS. London: Royal Society of Medicine Services Limited; 1993.
11. Stoianovich QJ. Les ruptures du tendon Achille. *Rev de Chirurg.* 1929;67:647–78.
12. Platt H. Observations on some tendon ruptures. *Br Med.* 1931;1(3666):611–5.
13. Lawrence GH, Cave EF, and HO. Injury to the Achilles' tendon. *Am J Surg.* 1955;89(4):795–802. doi:10.1016/0002-9610(55)90146-x.
14. Simmonds FA. The diagnosis of the ruptured Achilles tendon. *The Practitioner.* 1957;179(1069):56–8.

## Author biography

**Banna Kiran Kumar**, Assistant Professor

**Shenkeshi Sirish Kumar**, Assistant Professor

**Bolloju Keshava Rao**, Assistant Professor

**K Kishore Kumar**, Associate Professor

**J Venkateswarlu**, Professor and HOD

**Cite this article:** Kumar BK, Kumar SS, Rao BK, Kumar KK, Venkateswarlu J. A clinical study of surgical management of tendoachilles rupture by various modalities. *Panacea J Med Sci* 2021;11(3):401-405.