

## Dorsal Versus Ventral Oral Mucosal Graft Urethroplasty

Jalil Hosseini, Ali Kaviani, Mokhtar Hosseini, Mohammad Mohsen Mazloomfard, Abdollah Razi

**Purpose:** To evaluate success rate of dorsal versus ventral oral mucosal graft for anterior urethroplasty.

**Materials and Methods:** In a retrospective study, the results of the ventral and dorsal oral mucosal graft (OMG) anterior urethroplasty were assessed in 24 and 29 patients, respectively. Demographic and clinical characteristics of subjects were gathered from the medical records.

**Results:** Patients were followed up for a mean duration of 32 months (range, 25 to 51 months). The success rates of dorsal and ventral anterior OMG urethroplasty were 83.3% and 75.8%, respectively ( $P = .5$ ). At penile site, dorsal and ventral OMG were done for 9 and 10 patients with stricture lengths of  $3.7 \pm 1.1$  cm and  $3.9 \pm 1.2$  cm, respectively ( $P = .7$ ). Success rates of dorsal and ventral penile OMG were 88.9% and 70%, respectively ( $P = .3$ ). At the bulbar site, dorsal and ventral OMG were performed on 15 and 19 patients with stricture lengths of  $4.1 \pm 1.1$  cm and  $4.2 \pm 1.5$  cm, respectively ( $P = .7$ ). The success rates of dorsal and ventral bulbar OMG were 80% and 79%, respectively ( $P = .94$ ).

**Conclusion:** Oral mucosal graft is a versatile and an effective procedure for management of strictures throughout the anterior urethra, and in experienced hands, the outcomes are similarly favorable whether a dorsal or ventral approach is taken.

*Keywords: mouth mucosa, transplantation, urethral stricture, reconstructive surgical procedures, postoperative complications*

*Urol J. 2011;8:48-53.  
www.uj.unrc.ir*

### INTRODUCTION

The urethra is divided into anterior and posterior (membranous and prostatic) parts. The anterior part is surrounded by the corpus spongiosum, and includes two segments; the bulbar urethra, which is surrounded by the bulbospongiosus muscle, and the penile urethra that runs from the distal margin of the bulbospongiosus muscle to the fossa navicularis and external meatus.<sup>(1)</sup> Each of these areas is prone to strictures of its own particular type.

Urethral stricture is a complicated disease representing a therapeutic

challenge.<sup>(2)</sup> Buccal mucosal grafting (BMG) has gained widespread acceptance for urethroplasty of both urethral stricture and hypospadias repair during the past 10 years.<sup>(3)</sup> Initial success with the oral mucosal graft (OMG) to repair anterior urethral strictures has been noticeable.<sup>(4-7)</sup> However, follow-up in most series is short and techniques vary with series reporting ventral and dorsal onlay grafts.<sup>(4,6)</sup> In this retrospective study, we report the long-term follow-up of the ventrally and dorsally placed oral mucosal onlay graft in the anterior urethral reconstruction.

*Infertility and Reproductive Health Research Center, Department of Reconstructive Urology, Shohada-e-Tajrish Hospital, Shahid Beheshti University of Medical Sciences, Tehran, Iran*

*Corresponding Author:  
Jalil Hosseini, MD  
Infertility and Reproductive Health Research Center, Department of Reconstructive Urology, Shohada-e-Tajrish Hospital, Shahid Beheshti University of Medical Sciences, Tehran, Iran  
Tel: +98 21 2243 2558  
Fax: +98 21 2203 8462  
E-mail: jhosseinee@gmail.com*

*Received August 2009  
Accepted May 2010*

## MATERIALS AND METHODS

A total of 53 patients with anterior urethral (penile or bulbar) stricture longer than 3 cm underwent OMG urethroplasty between January 2000 and January 2006. The results were obtained from medical records.

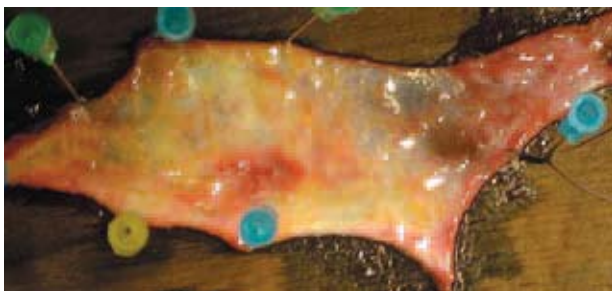
The etiologies of the strictures were trauma in 9, infection in 9, iatrogenic in 8, failed hypospadias in 7, and unknown etiologies in 20 patients. Patients with Lichen sclerosus, previous failed open urethroplasty, unwillingness to participate, and who needed complicated surgeries were excluded from the study. All of the operations have been done by the same surgical team.

Anterior urethroplasty has been performed using two methods: ventral and dorsal OMG groups. According to the location of the urethral stricture, ventral and dorsal OMG were further categorized to penile and bulbar segments.

### Surgical Technique

After providing nasal tube general anesthesia, oral mucosa was harvested from the inner side of the patient's cheek. Graft bed was sutured using 4-0 plain sutures. After trimming the graft and removing any remaining fat, buccal graft was used for urethroplasty (Figure 1). Urethral plate preparations were performed by delicate dissection of the penile or bulbar urethra from surrounding tissue followed by an adopted technique, which provided a ventral or dorsal cut with appropriate calibration of the distal and proximal urethral lumen.

In ventral BMG technique, graft was sutured to the urethral plate using 5-0 vicryl sutures. Thereafter, the graft was covered by dartos fascia in the penile group or spongiosum tissue



**Figure 1.** Buccal graft harvesting and trimming.

in the bulbar group (Figure 2). In dorsal OMG technique, the graft was put and sutured to cavernous bed and after that, graft was sutured to margin of the opened urethra using 5-0 vicryl sutures (Figure 3).

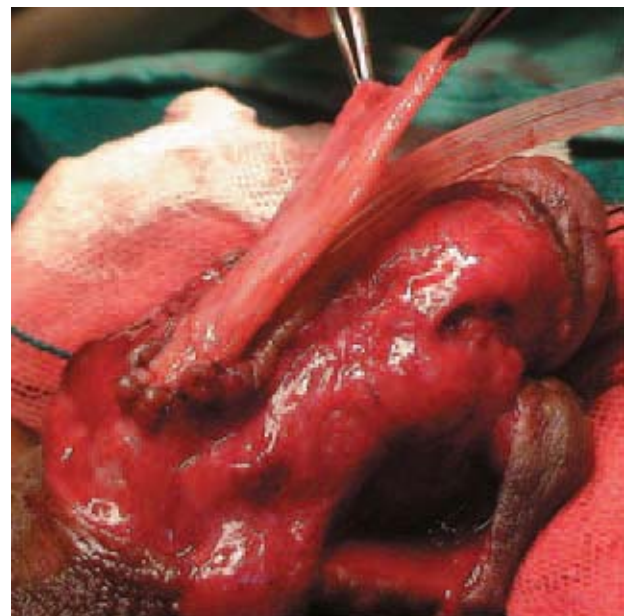
All the patients had urethral catheter for 14 days after the surgery. The patients were put on regular follow-up at 3, 6, 12, 18, and 24-month clinical visits, and urethrocystoscopy was performed at 6 and 18 months postoperatively. If patients had any recent voiding problems, they underwent immediate cystoscopy.

Demographic characteristics, stricture length based on intra-operative measurement, etiology of urethral stricture, success rate, and complications of both ventral and dorsal OMG were compared between two groups. The clinical outcome was considered a failure if any postoperative procedure was needed, including dilation.

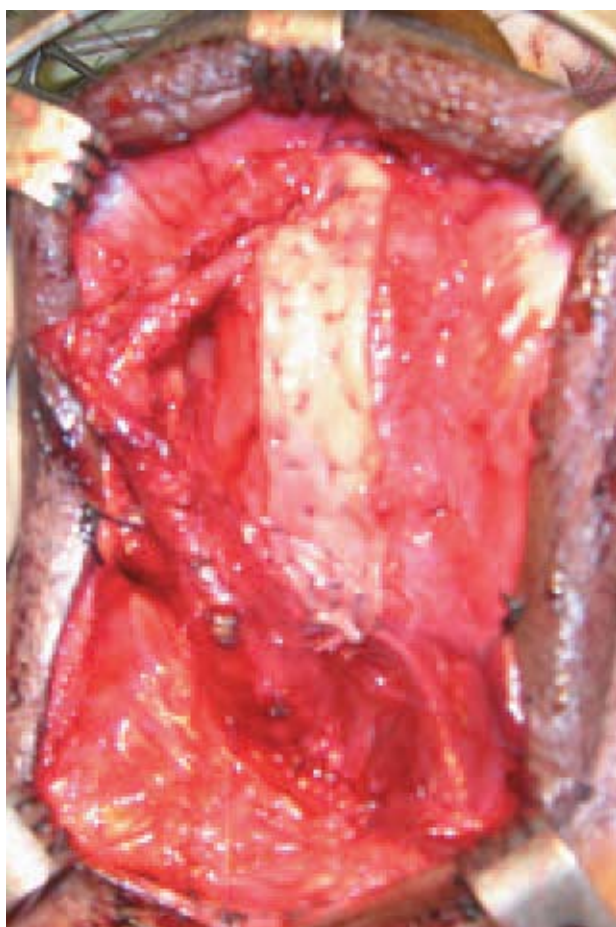Data were analyzed using SPSS (Statistical Package for the Social Sciences, Version 14.0, SPSS Inc., Chicago, Illinois, USA) software. Mann-Whitney, Chi-square, and Fisher's exact tests were performed, if appropriate, with a significance level set at  $P < .05$ .

## RESULTS

The mean age of the patients was 23 years (range,



**Figure 2.** Ventral onlay buccal mucosal grafting in penile urethra.



**Figure 3.** Dorsal only buccal mucosal grafting in bulbar urethra.

17 to 81 years) and they had been followed up for a mean of 32 months (range, 25 to 51 months). There were no significant differences in the two groups and their subgroups in terms of mean patients' age, mean stricture length, or etiology. Total success rates of dorsal and ventral anterior OMG urethroplasty were 83.3% and 75.8%, respectively ( $P = .5$ ). Early complications of oral graft harvesting consisted of cheek swelling and perioral numbness in 4 (7.5%) patients, with spontaneous resolution.

As it can be observed in Table 1, at penile site, dorsal and ventral OMG were done for 9 and 10 patients with stricture lengths of  $3.7 \pm 1.1$  cm and  $3.9 \pm 1.2$  cm, respectively ( $P = .7$ ). Etiologies of stricture in the penile urethra are also listed in Table 1. There were no early postoperative complications, such as wound infections, hematomas, and bleeding requiring transfusion. In the dorsal OMG group, stricture developed in 1 patient with a previous failed hypospadias repair, at 3 months after the operation, which was managed with periodic urethral dilation. Conversely, in the ventral OMG group, urethrocutaneous fistula developed in 2 subjects, who were successfully treated by another OMG urethroplasty; and stricture developed in 1 patient. Success rates of dorsal and ventral penile

**Table 1.** Demographic, operation, and complication data of dorsal versus ventral OMG with respect to bulbar or penile origin\*

Site of anterior urethral stricture	Penile			Bulbar		
	Dorsal	Ventral	<i>P</i>	Dorsal	Ventral	<i>P</i>
Site of OMG						
Number (%)	9 (47.3)	10 (52.7)	-	15 (44.1)	19 (55.9)	-
Age (year $\pm$ SD)	42.1 $\pm$ 8.4 (19 to 75)	41 $\pm$ 7.5 (17 to 71)	.84	44.3 $\pm$ 9.7 (21 to 73)	44.7 $\pm$ 8.9 (22 to 81)	.9
Stricture Length (cm $\pm$ SD)	3.7 $\pm$ 1.1 (3.0 to 5.5)	3.9 $\pm$ 1.2 (3.0 to 5.0)	.7	4.1 $\pm$ 1.1 (3.5 to 6.0)	4.2 $\pm$ 1.5 (3.5 to 6.5)	.7
Etiologies						
Idiopathic (%)	3 (33.3)	3 (30)	.88	6 (40)	8 (42.1)	.9
Trauma (%)	0 (0)	0 (0)	-	4 (26.6)	5 (26.3)	.69
Instrumentation (%)	1 (11.1)	1 (10)	.93	3 (20)	3 (15.7)	.75
Infection (%)	2 (22.2)	2 (20)	.91	2 (13.3)	3 (15.7)	.84
Failed hypospadias repair (%)	3 (33.3)	4 (40)	.76	0 (0)	0 (0)	-
Total Complications (%)	1 (11.1)	3 (30)	.31	3 (20)	4 (21)	.94
Stricture (%)	1 (11.1)	1 (10)	.93	2 (13.3)	3 (15.7)	.84
Fistula (%)	0	2 (20)	.47	0 (0)	0 (0)	-
Graft infection (%)	0	0	-	0 (0)	0 (0)	-
Wound hematoma (%)	0	0	-	1 (6.6)	1 (5.2)	.86
Success rate (%) <sup>†</sup>	88.9	70	.3	80	79	.94

\*OMG indicates oral mucosal graft.

<sup>†</sup>Total success rate: Dorsal OMG: (20/24) 83.3% and Ventral OMG: (22/29) 75.8%

OMG were 88.9% and 70%, respectively ( $P = .3$ ).

On the other hand, at the bulbar site, dorsal and ventral OMG were performed on 15 and 19 patients with stricture lengths of  $4.1 \pm 1.1$  cm and  $4.2 \pm 1.5$  cm, respectively ( $P = .7$ ). No significant difference was detected between etiologies of bulbar stricture in these groups (Table 1). There were 5 strictures in patients that underwent bulbar urethroplasty, including 2 subjects in dorsal and 3 in ventral group. All of them developed at 6 months after the surgery and were managed by urethral dilatation with an acceptable urine flow. Wound hematoma was detected in 1 patient of each group and was treated by dressing without any graft infection. The success rates of dorsal and ventral bulbar OMG were 80% and 79%, respectively ( $P = .94$ ).

## DISCUSSION

Treatment of urethral stricture diseases includes numerous reconstructive surgical techniques. The urologist must be familiar with all of these different techniques to be able to deal with any type of urethral stricture.<sup>(8)</sup> The choice of reconstructive technique depends on the stricture length, degree of spongiofibrosis, and surgeon's preference and experience.<sup>(9)</sup>

Innovation of an ideal urethroplastic donor tissue was initially challenging. Previously, full thickness skin grafts from hair-bearing sites of the body showed promising results. However, these grafts were associated with complications.<sup>(10)</sup> The use of OMG as a donor tissue in urethroplastic reconstruction consists of autologous transplantation of nonkeratinized oral mucosa to the urethra for repair of a variety of urological defects.<sup>(10)</sup> Oral mucosal graft has a thick epithelium rich in elastin, making it durable and easy to handle. The lamina propria is thin compared to that of the bladder mucosa and skin, facilitating inosculation and neovascularization. It has a high capillary density and is easily harvested, with immunologic properties similar to that of the urothelium.<sup>(3,11,12)</sup>

The gold standard treatment for stricture of the bulbar urethra of  $\geq 2$  cm in length, where the urethral lumen is relatively well-preserved, is OMG urethroplasty.<sup>(1)</sup> Recent controversy has

surrounded whether to insert this tissue in a ventral or dorsal position.<sup>(13)</sup> Suggested benefits of dorsal onlay graft consist of less bleeding from the thinner dorsal spongiosum, application of the graft to the tunica albuginea of the corpora cavernosa providing a more stable base to allow better fixation of the graft, facilitating the acquisition of a richer blood supply, and reducing contracture during healing.<sup>(14)</sup>

Pansadoro and colleagues reported a success rate of 98% for 56 patients who received dorsal onlay BMG. Only 1 patient having a recurrence was found on postoperative urethrography.<sup>(5)</sup> Dubey and associates reported a success rate of 87% in 16 patients undergoing dorsal onlay BMG.<sup>(15)</sup> Andrich and coworkers compared results of ventral onlay with dorsal onlay buccal mucosal bulbar urethroplasty. After a follow-up of 48 to 60 months, success rates of 86% and 95% were reported in ventral and dorsal onlay groups, respectively.<sup>(6)</sup> In 2005, Barbagli and colleagues repaired 50 bulbar urethral strictures with BMG. The graft was placed on the ventral, dorsal, and lateral bulbar urethral surface in 17, 27, and 6 patients, respectively. The ventral, dorsal, and lateral graft provided success rates of 83%, 85%, and 83%, respectively. The authors suggested that different position of the grafts showed no difference in the success rate.<sup>(13)</sup> In our study, the surgery was successful in 27 (79.5%) patients. The 19 ventral grafts provided success in 15 (79%) subjects and failure in 4 (21%). The 15 dorsal grafts provided success in 12 (80%) patients and failure in 3 (20%). Our lower success rates in comparison with other studies could be due to consideration of wound hematoma or postoperative urethral dilation as a failure. Therefore, if we do not take wound hematoma into account, our trials success rates rise to 86.6% and 84.2% for dorsal and ventral grafting, respectively. The results of both ventral and dorsal OMG reported in the literature are summarized in Table 2.

To repair the glandular and penile shaft urethra, buccal mucosa of the inner lip and cheek are preferred, respectively.<sup>(17)</sup> Both ventral and dorsal grafting were applied for penile stricture, but because of the relative deficiency of covering tissues in the penile urethra, there is reduced

**Table 2.** Outcomes of ventral and dorsal onlay oral mucosal bulbar urethroplasty

Study	Participants	Follow-up, month	Success rate, %
Ventral onlay oral mucosal bulbar urethroplasty			
Current study	19	24	79
Andrich et al <sup>(6)</sup>	29	60	86
Barbagli et al <sup>(13)</sup>	17	42	83
Fichtner et al <sup>(3)</sup>	15	72	87
Pansadoro et al <sup>(5)</sup>	9	41	89
Dubey et al <sup>(15)</sup>	7	45	77.8
Dorsal onlay oral mucosal bulbar urethroplasty			
Current study	15	24	80
Pansadoro et al <sup>(5)</sup>	56	41	98
Dubey et al <sup>(15)</sup>	15	22	87
Andrich et al <sup>(6)</sup>	42	60	95
Barbagli et al <sup>(13)</sup>	27	42	85
Xu et al <sup>(16)</sup>	12	57	75

potential for the survival of ventrally applied free grafts.<sup>(18)</sup> Metro and colleagues reported their 8-year experience of using buccal mucosa to treat both hypospadias and urethral strictures. Six of 14 patients had recurrent stricture requiring further intervention, giving a success rate of only 57.1%.<sup>(19)</sup> Fichtner and associates published their long-term outcomes in 17 patients who underwent ventrally applied BMG with a success rate of 88.2%.<sup>(3)</sup> Dubey and coworkers reported a series of 43 patients undergoing dorsal onlay buccal mucosal urethroplasty for penile strictures; 28 underwent single-stage operations and 15 two-stage procedures. They reported success rates of 85.7% and 86.7% for single and two-stage procedures, respectively.<sup>(20)</sup>

The outcomes of penile urethroplasty using oral mucosa are summarized in Table 3. Our experience for penile OMG urethroplasty show that success rate of dorsal penile OMG was greater than the ventral one (88.9% versus 70%). Although it is not statically significant ( $P = .3$ ),

this suggests a higher potential risk of failure, especially for fistula formation in the ventral grafting group. Therefore, it is better to avoid ventral onlay of oral mucosa in the distal anterior urethra because of potential poor outcomes.

Age, urethral stricture length, number of previous operations, extent of dissection, and the primary etiology of the urethral stricture may play some roles in the recurrence of strictures.<sup>(12)</sup> In our study, 7 patients experienced initial stricture failure recurred during the first 6 postoperative months. A graft such as oral mucosa carries no blood supply of its own. Its survival depends on the absorption of nutrients from a well-vascularized recipient bed (imbibition phase) and later, on the in-growth of capillaries from the recipient bed to the graft (inosculation phase).<sup>(23)</sup> Early failure of a free graft can result from inadequacy of either phase and frequently reflects a poorly-vascularized recipient bed, infection, or hematoma. Late restricture may owe

**Table 3.** Outcomes of ventral and dorsal onlay oral mucosal penile urethroplasty

Study	Participants	Follow-up, month	Success rate, %
Ventral onlay oral mucosal penile urethroplasty			
Current study	10	24	70
Fichtner et al <sup>(3)</sup>	17	72	88.2
Metro et al <sup>(19)</sup>	14	60	57.1
Dubey et al <sup>(20)</sup>	15	24	86.7
Dorsal onlay oral mucosal penile urethroplasty			
Current study	9	24	88.9
Venn and Mundy <sup>(21)</sup>	8	36	100
Dubey et al <sup>(22)</sup>	14	32	78.6
Andrich and Mundy <sup>(17)</sup>	41	60	100

to progression of the original disease. However, initial failure in most subjects can be converted to long-term success with urethral dilatation.<sup>(24)</sup>

We realize that the study could have some weaknesses. The main bias is that the study has low number of patients, especially in the penile group. Hence, we recommend comparing of these two methods with more subjects under additional assessment and long-term follow-up.

## CONCLUSION

In summary, OMG is versatile and effective for strictures throughout the anterior urethra, and in experienced hands, the outcomes are similarly favorable whether a dorsal or ventral approach is taken.

## ACKNOWLEDGEMENTS

The authors appreciate Infertility and Reproductive Health Research Center, Shahid Beheshti University of Medical Sciences, for supporting this study, and would like to especially thank *Negin Alizadeh* for grammatical assistance.

## CONFLICT OF INTEREST

None declared.

## REFERENCES

- Andrich DE, Mundy AR. What is the best technique for urethroplasty? *Eur Urol.* 2008;54:1031-41.
- Andrich DE, Mundy AR. Outcome of different management options for full-length anterior urethral strictures. *J Urol.* 2009;181:13.
- Fichtner J, Filipas D, Fisch M, Hohenfellner R, Thuroff JW. Long-term outcome of ventral buccal mucosa onlay graft urethroplasty for urethral stricture repair. *Urology.* 2004;64:648-50.
- Barbagli G, Palminteri E, Rizzo M. Dorsal onlay graft urethroplasty using penile skin or buccal mucosa in adult bulbourethral strictures. *J Urol.* 1998;160:1307-9.
- Pansadoro V, Emiliozzi P, Gaffi M, Scarpone P. Buccal mucosa urethroplasty for the treatment of bulbar urethral strictures. *J Urol.* 1999;161:1501-3.
- Andrich DE, Leach CJ, Mundy AR. The Barbagli procedure gives the best results for patch urethroplasty of the bulbar urethra. *BJU Int.* 2001;88:385-9.
- Hosseini J, Soltanzadeh K. A comparative study of long-term results of Buccal Mucosal Graft and Penile Skin Flap techniques in the management of diffuse anterior urethral strictures: first report in Iran. *Urol J.* 2004;1:94-8.
- Peterson AC, Webster GD. Management of urethral stricture disease: developing options for surgical intervention. *BJU Int.* 2004;94:971-6.
- Berger AP, Deibl M, Bartsch G, Steiner H, Varkarakis J, Gozzi C. A comparison of one-stage procedures for post-traumatic urethral stricture repair. *BJU Int.* 2005;95:1299-302.
- Markiewicz MR, Lukose MA, Margarone JE, 3rd, Barbagli G, Miller KS, Chuang SK. The oral mucosa graft: a systematic review. *J Urol.* 2007;178:387-94.
- Duckett JW, Coplen D, Ewalt D, Baskin LS. Buccal mucosal urethral replacement. *J Urol.* 1995;153:1660-3.
- Mehrsai A, Djaladat H, Salem S, Jahangiri R, Pourmand G. Outcome of buccal mucosal graft urethroplasty for long and repeated stricture repair. *Urology.* 2007;69:17-21; discussion
- Barbagli G, Palminteri E, Guazzoni G, Montorsi F, Turini D, Lazzeri M. Bulbar urethroplasty using buccal mucosa grafts placed on the ventral, dorsal or lateral surface of the urethra: are results affected by the surgical technique? *J Urol.* 2005;174:955-7; discussion 7-8.
- Patterson JM, Chapple CR. Surgical techniques in substitution urethroplasty using buccal mucosa for the treatment of anterior urethral strictures. *Eur Urol.* 2008;53:1162-71.
- Dubey D, Kumar A, Bansal P, et al. Substitution urethroplasty for anterior urethral strictures: a critical appraisal of various techniques. *BJU Int.* 2003;91:215-8.
- Xu YM, Qiao Y, Sa YL, et al. Substitution urethroplasty of complex and long-segment urethral strictures: a rationale for procedure selection. *Eur Urol.* 2007;51:1093-8; discussion 8-9.
- Andrich DE, Mundy AR. Substitution urethroplasty with buccal mucosal-free grafts. *J Urol.* 2001;165:1131-3; discussion 3-4.
- Wessells H, McAninch JW. Current controversies in anterior urethral stricture repair: free-graft versus pedicled skin-flap reconstruction. *World J Urol.* 1998;16:175-80.
- Metro MJ, Wu HY, Snyder HM, 3rd, Zderic SA, Canning DA. Buccal mucosal grafts: lessons learned from an 8-year experience. *J Urol.* 2001;166:1459-61.
- Dubey D, Kumar A, Mandhani A, Srivastava A, Kapoor R, Bhandari M. Buccal mucosal urethroplasty: a versatile technique for all urethral segments. *BJU Int.* 2005;95:625-9.
- Venn SN, Mundy AR. Urethroplasty for balanitis xerotica obliterans. *Br J Urol.* 1998;81:735-7.
- Dubey D, Sehgal A, Srivastava A, Mandhani A, Kapoor R, Kumar A. Buccal mucosal urethroplasty for balanitis xerotica obliterans related urethral strictures: the outcome of 1 and 2-stage techniques. *J Urol.* 2005;173:463-6.
- Baskin LS, Duckett JW. Buccal mucosa grafts in hypospadias surgery. *Br J Urol.* 1995;76 Suppl 3:23-30.
- Elliott SP, Metro MJ, McAninch J. Long-term followup of the ventrally placed buccal mucosa onlay graft in bulbar urethral reconstruction. *J Urol.* 2003;169:1754-7.