

## An Unusual Complication of Suprapubic Catheter Migration into the Left Ureter

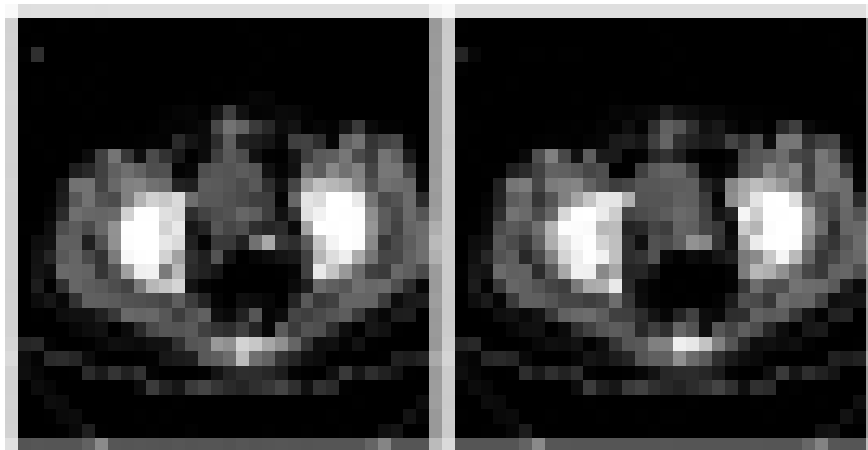
Wang Shuaibin, Mu Haiqi, Feng Qin, Yu Haifeng\*

**Keywords:** suprapubic catheter; complication; migration into ureter; pyelonephritis.

Suprapubic cystostomy is a widely employed procedure that is used to drain the bladder. Despite being a safe procedure, suprapubic cystostomy has been reported to present multiple intra- and postoperative complications. Serious and unusual complications can occur during changing of the suprapubic catheter (SPC) in patients with neuropathic bladder. In this work, we report an elderly patient with neuropathic bladder suffering from an unusual complication involving migration of the SPC into the ureter during changing of the SPC, leading to ureteric obstruction and left pyelonephritis.

### INTRODUCTION

Suprapubic catheters (SPCs) are commonly used to drain the bladder. Early studies show that suprapubic cystostomy is an effective and well-tolerated method for patients with neuropathic bladder. The method can accelerate renal deterioration and prevent urinary tract complications, including stones, recurrent infections, and blocked catheters<sup>(1)</sup>. Although suprapubic cystostomy is a safe procedure in most cases, unusual complications may occur either immediately after suprapubic cystostomy or several years after the procedure<sup>(2,3)</sup>. Herein, we report an elderly male patient with senile dementia who suffered from an unusual complication of SPC migration into the ureter during SPC change. Suprapubic cystostomy was performed on the patient 3 years prior to this report.



**Figure 1.** Computed tomography, performed on 14 May 2017, (A left picture) The dilated ureter and the tip of Foley catheter was located in ureter (white arrow). (B right picture) The balloon of Foley catheter had been inflated in distal end of dilated ureter (white arrow).

### CASE REPORT

An 80-year-old Chinese man with neurogenic bladder and benign prostatic hyperplasia was referred to the Urology Department of our hospital in October 2015. His past history included experiencing a stroke ten years prior to reporting and suffering from senile dementia. Thus, the patient exhibited difficulty in communicating with others and expressing his feelings. Preoperative ultrasound scan showed an enlarged prostate (50 mm × 39 mm × 37 mm in size). Urodynamics performed on 21 October 2015 showed weak contractility of the detrusor and moderate obstruction of the bladder neck. The patient was treated through TURP (transurethral prostate resection)

Department of Urology, The Second Affiliated Hospital of Wenzhou Medical University, Wenzhou, Zhejiang 325027, People's Republic of China.

\*Correspondence: Department of Urology, The Second Affiliated Hospital of Wenzhou Medical University, Wenzhou, Zhejiang 325027, People's Republic of China

Tel: +86-577-88002815. Fax: +86-577-88002855. E-mail: 691898478@qq.com.

Received June 2017 & Accepted October 2017

and suprapubic cystostomy. During the first month after operation, the patient continued to experience serious urinary incontinence. His SPC was changed every four weeks in the urology unit after surgery. Twelve days after a catheter change in May 2017, which was uneventful, his family noticed that the drainage catheter showed hematuria and pyuria per urethra. Moreover, the patient experienced incontinence and fever (tympanic temperature, 38.2 °C). He was brought directly to our Accident and Emergency Department, where laboratory investigations showed an elevated peripheral white blood cell (WBC) count of  $25.4 \times 10^9/L$  (normal range:  $4-10 \times 10^9/L$ ), neutrophil ratio of 96%, and elevated C-reactive protein of 186 mg/L (normal range: 0–8 mg/L). Serum creatinine and blood urea nitrogen were 104  $\mu\text{mol/L}$  (normal range: 50–133  $\mu\text{mol/L}$ ) and 8.38 mmol/L (normal range: 2.9–8.2 mmol/L), respectively. The patient developed an increasing degree of left renal pain. Computed tomography and ultrasound examination of the abdomen and pelvis revealed that the SPC tube had migrated into the ureteral orifice and ureter. The tip of the Foley catheter was lying about 4cm from the ureterovesical junction (**Figure 1**). More significantly, hydronephrosis of the left kidney without hydroureter was found. Given the findings on the CT scan and the patient's symptoms, diagnostic imaging demonstrated ureter obstruction and left pyelonephritis. The SPC (18 French) was changed under ultrasonography guidance, and the patient was prescribed 2 g of ceftriaxone administered intravenously every day for five days. Hematuria and pyuria subsided after 72 h. The patient was discharged in a stable condition after a week.

## DISCUSSION

Suprapubic cystostomy catheter drainage is considered a valid and useful adjunct in various scenarios. Most commonly applied in urology practice, this drainage is vital in patients with long-term catheters (because of various causes) and many postoperative situations<sup>(4)</sup>. A meta-analysis comparing SPC tubes with transurethral catheter drainage revealed that the suprapubic route is more acceptable to patients and reduces microbiological complications<sup>(5)</sup>. Our patient used SPC instead of urethral catheterization after transurethral resection of the prostate and did not develop any problems in the following 30 months.

Although suprapubic cystostomy is a well-established procedure, complications do occur. Multiple common complications, such as bacteriuria, bleeding, and bladder calculi, have been reported<sup>(6,7)</sup>. However, several rare and unusual complications of suprapubic cystostomy have also been reported. These complications include bowel perforation, expulsion through bladder, entero-cutaneous fistula, knotting of the catheter, and catheter migration in a gaping ureter. Vaidyanathan et al.<sup>(8)</sup> reported a serious complication during suprapubic cystostomy change in a spina bifida patient; in this case, inadvertent positioning of the SPC in the urethra led to urine drainage failure of the SPC. The patient developed an increasing degree of pain, swelling in the suprapubic region, and hematuria. Hourglass deformity of urinary bladder is another unusual late complication of suprapubic cystostomy reported in patients with neuropathic bladder. Singh and colleagues reported a case of left pyelonephritis secondary to catheter insertion for traumatic urethral stricture in a young male in 2001<sup>(9)</sup>.

Cystographic evaluation revealed the contrast entering the left ureter with bilateral hydronephrosis. The author hypothesized the possibility of catheter migration into a gaping ureter with bilateral hydronephrosis. In 2010, Dangle and colleagues<sup>(10)</sup> reported another case of SPC migration into the left ureteral orifice that led to ureter obstruction and hydronephrosis. The patient who possessed a solitary kidney with neurogenic bladder and voiding dysfunction was managed with SPC drainage. These reports suggest that, for patients with a solitary kidney, diagnosis of such a condition is crucial to provide immediate relief to the obstructed kidney. In the present paper, we report an elderly male patient with senile dementia whose SPC had migrated into a previously normal non-gaping ureter. Given the communication barrier, the drainage color and volume changes per urethra were not discovered in time by his family, leading to serious complications of ureteric obstruction, left pyelonephritis, and a slight degree of renal damage. By reviewing this case report, we can postulate that the presence of bladder dysfunction in elderly patients combines detrusor overactivity and a patulous ureteral orifice, leading to migration of the catheter tip into the ureteral orifice and ureter. Ureter obstruction could lead to unilateral upper urinary hydroceles and pyelonephritis, whereas normal ureters may cause bladder incontinence. Diagnosing such a condition is crucial to immediately rectify the incorrect placement of the SPC and relieve the obstructed kidney; prescription of antibacterial agents may help promote healing. We suggest that the SPC be anchored securely to reduce the occurrence of migration of the catheter tip into the ureter and accidental dislodgment of the catheter. In case of difficulty, ultrasound guidance should be employed when performing catheter exchange.

## CONCLUSIONS

SPC migration into ureter is a poorly reported complication that must be reported. Health professionals should be vigilant when inserting a catheter through the suprapubic track. A learning point from this case is as follows: Suprapubic catheters should be anchored securely to reduce the occurrence of the migration of the catheter into ureter and accidental catheter dislodgment.

## CONFLICT OF INTEREST

None declared.

## REFERENCES

1. Vaidyanathan Subramanian, Soni Bakul, Hughes Peter, et al. Preventable long-term complications of suprapubic cystostomy after spinal cord injury: Root cause analysis in a representative case report. *Patient Saf Surg.* 2011;5:27.
2. Szolnoki J M, Puskas F, Sweeney D M, et al. Hyponatremic seizures after suprapubic catheter placement in 7-year-old child. *Paediatr Anaesth.* 2006;16:192-4.
3. Vaidyanathan Subramanian, Soni Bakul M, Singh Gurpreet, et al. Fatality due to septicemia and hemorrhage in a patient with spinal cord injury and ischemic heart disease with the need for long-term catheter drainage.

- Adv Ther. 2006;23:354-8.
4. Ananthakrishnan Krishnan, Ayyathurai Rajinikanth, Chiran J K, et al. An unusual complication of suprapubic catheter insertion. *ScientificWorldJournal*. 2006;6:2433-5.
  5. McPhail M J W, Abu-Hilal M, Johnson C DA meta-analysis comparing suprapubic and transurethral catheterization for bladder drainage after abdominal surgery. *Br J Surg*. 2006;93:1038-44.
  6. Katsumi H K, Kalisvaart J F, Ronningen L D, et al. Urethral versus suprapubic catheter: choosing the best bladder management for male spinal cord injury patients with indwelling catheters. *Spinal Cord*. 2010;48:325-9.
  7. Nomura S, Ishido T, Teranishi J, et al. Long-term analysis of suprapubic cystostomy drainage in patients with neurogenic bladder. *Urol Int*. 2000;65:185-9.
  8. Vaidyanathan Subramanian, Hughes Peter L, Soni Bakul M, et al. Inadvertent positioning of suprapubic catheter in urethra: a serious complication during change of suprapubic cystostomy in a spina bifida patient - a case report. *Cases J*. 2009;2:9372.
  9. Vaidyanathan Subramanian, Hughes Peter L, Soni Bakul M, et al. Hourglass urinary bladder in a spinal cord injury patient - unusual late complication of suprapubic cystostomy: a case report. *Cases J*. 2009;2:6866.
  10. Dangle Pankaj P, Tycast James, Vasquez Evalynn, et al. Suprapubic cystostomy: a bizarre complication of catheter migration causing ureteric obstruction. *Can Urol Assoc J*. 2010;4:E127-8.