

## Penile Glans Necrosis Developing after Internal Pudendal Arterial Embolization: A Case Report

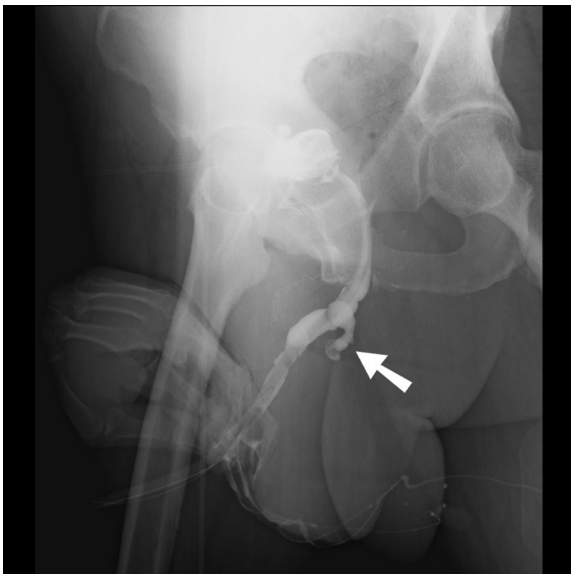
Tae Nam Kim<sup>1,2</sup>, Chan Ho Lee<sup>1,2</sup>, Seung Ryong Baek<sup>1,2</sup>, Kyung Min Lee<sup>1,2</sup>, Sangmin Choe<sup>2,3</sup>, Nam Cheol Park<sup>1,2</sup>, Hyun Jun Park<sup>1,2\*</sup>

**Keywords:** glans; penis; necrosis; embolization; phosphodiesterase 5 inhibitor.

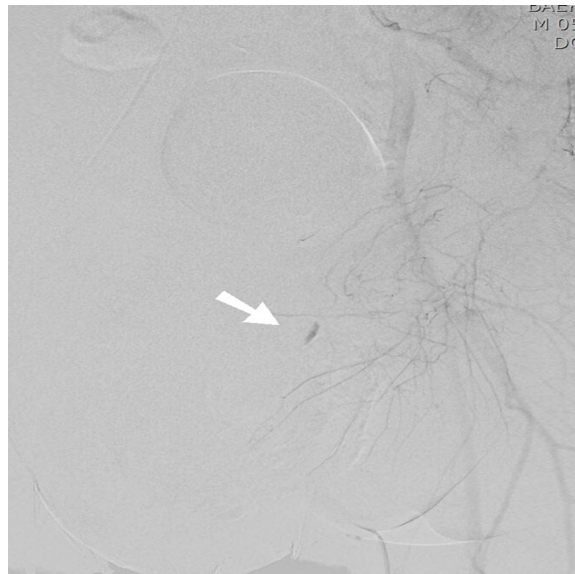Penile glans ischemia or necrosis developing after internal pudendal arterial embolization is very rare; no relevant report has yet appeared. A 53-year-old male who visited our emergency room because of massive urethral bleeding was diagnosed with an internal pudendal artery-urethral fistula; he underwent selective embolization of the internal pudendal artery. However, unexpected penile glans ischemic necrosis developed after embolization. We successfully treated the patients with intravenous infusion of alprostadil, oral pentoxifylline and tadalafil.

### INTRODUCTION

Ischemic or necrotic complications of the glans penis are very rare. The use of vasoconstricting agents, circumcision, hematoma, excessive cauterization, placement of a tight compressive bandage, and arterial vasospasm caused by needling trauma may induce the condition<sup>(1)</sup>. To the best of our knowledge, no report has yet described penile glans necrosis developing after internal pudendal arterial embolization. Selective embolization of the pudendal artery has been used to treat post-traumatic high flow priapism; internal pudendal artery-urethral fistulae; pseudoaneurysms; and arteriovenous fistulae<sup>(2-4)</sup>. However, as a side effect of this procedure, only few instances of transient erectile dysfunction (ED) have been reported<sup>(2)</sup>. Here we report a case of penile glans necrosis after internal pudendal arterial embolization successfully treated with intravenous infusion of alprostadil, oral pentoxifylline and tadalafil.



**Figure 1.** Retrograde urethrography showed a contrast media leakage at the bulbous urethra (arrow)



**Figure 2.** Left internal iliac artery angiography demonstrate active contrast leakage from left internal pudendal artery branch (arrow)

<sup>1</sup>Department of Urology, Pusan National University School of Medicine, Busan, South Korea.

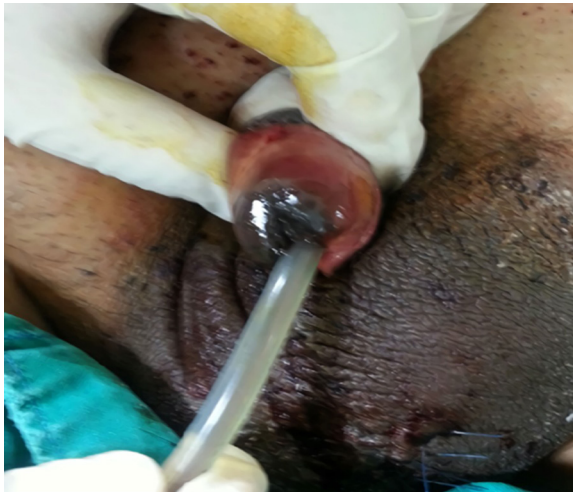<sup>2</sup>Medical Research Institute of Pusan National University Hospital, Busan, South Korea.

<sup>3</sup>Department of Clinical Pharmacology and Therapeutics, Pusan National University Hospital, Busan, South Korea.

\*Correspondence: Department of Urology and Medical Research Institute of Pusan National University Hospital, Pusan National University School of Medicine, 179 Gudeok-ro, Seo-gu, Busan 49241, South Korea.

Tel: +82 51 2407347. Fax: +82 51 2475443. E-mail: joon501@naver.com.

Received February 2017 & Accepted September 2017



**Figure 3.** Ischemic, poorly perfused, black colored glans



**Figure 4.** Recovery of the ischemic necrotic glans

### CASE REPORT

A 53-year-old male who had no history of illness such as diabetes or cardiovascular disease visited our emergency room because of massive urethral bleeding and perineal laceration. Initial evaluation and management were conducted by a traumatologist. According to the patient, he was taking a shower while sitting in a plastic chair; the chair broke and a piece of plastic became embedded in his perianal buttocks. A pelvic X-ray revealed no abnormality of the pelvic bone, but computed tomography revealed active bleeding, with a hematoma, around the site of injury in the bulbous urethral region, and air in the perianal soft tissue. Retrograde urethrography revealed leakage of the contrast medium in the region of the bulbous urethra (**Figure 1**). A 16-F Foley catheter was inserted. Emergency angiography was performed via a right femoral arterial approach. Selective arteriography combined with left internal iliac artery angiography revealed active contrast leakage from the left branch of the internal pudendal artery (**Figure 2**). Right internal iliac artery angiography revealed an intact penile artery arising from the right internal pudendal artery, without any focus of bleeding. Selective embolization of the left branch of the internal pudendal artery branch was performed using n-butyl cyanoacrylate (NBCA) mixed with iodized oil (lipiodol) at a ratio of 1:3. The extravasation disappeared on subsequent angiography. Urethral bleeding ceased after embolization. However, after 10 days, the patient was transferred to the urological department because he complained of painful glans ischemia. Physical examination revealed an ischemic, poorly perfused black glans (**Figure 3**). The urgent color doppler sonography revealed good blood flow in both intracavernosal arteries.

We commenced intravenous infusion of alprostadil 5 µcg, maintained the hospital stay (a further 10 days), and commenced oral pentoxifylline 400 mg bid for 4 weeks and tadalafil 5 mg daily for 3 months. The treatment outcome was excellent, with significant recovery of the ischemic necrotic glans (**Figure 4**). Erectile function was not fully normal immediately after embolization; however, the patient reported that his erectile function is improving as the tadalafil treatment continues.

### DISCUSSION

Ischemic necrosis of the glans penis is very rare; no optimal treatment has yet been established. However, several reports employed various treatment options<sup>(1,5)</sup>. The necrosis of the glans penis can be diagnosed easily by the black color or necrotic appearance of the glans penis, but it is helpful to perform color doppler sonography to detect the blood flow state of the intracavernosal arteries<sup>(1,6)</sup>.

The principle objective of treatment is to increase blood flow, allowing adequate oxygen delivery to, and revascularization of, ischemic tissues. Reported treatments include topical 10% testosterone undecanoate, intracavernous glycerol trinitrate and bupivacaine, intravenous infusion of iloprost (a PGI<sub>2</sub> analog), low-dose heparin infusion, and intravenous or oral pentoxifylline with hyperbaric oxygen<sup>(5)</sup>. We prescribed intravenous infusion of alprostadil 5 µcg, oral pentoxifylline 400 mg bid for 4 weeks, and daily tadalafil 5 mg for 3 months. Pentoxifyllin is a peripheral vasodilator that stimulates prostaglandin production and inhibits Phosphodiesterase (PDE) activity, thus increasing cAMP synthesis<sup>(1)</sup>. To date, PDE5 inhibitors have not been used to treat penile necrosis. However, it is useful to consider the utility of such treatment. PDE5 inhibitors can be used to treat heart ischemic/reperfusion injuries; the effects are thought to reflect activation of protein kinase C/extracellular signal-regulated kinase signaling, opening of mitochondrial adenosine triphosphate-sensitive potassium channels, and attenuation of cell death caused by necrosis and apoptosis<sup>(7)</sup>. Furthermore, an earlier report treated penile fibrosis developing after priapism with pentoxifylline and sildenafil<sup>(8)</sup>. We thus prescribed combination pentoxifylline and tadalafil (the latter drug has the longest half-life among all PDE5 inhibitors) and obtained satisfactory results. However, in order for tadalafil to be selected as a treatment for penile necrosis, more case studies and clinical trials should be supported.

The patient reported that his erectile function was reduced immediately after injury, and also shortly after the onset of penile glans necrosis, but that partial recovery was evident after 3 months of treatment, which continued over time. Takao et al. reported that erectile

function gradually recovered after embolization of a patient with post-traumatic high-flow priapism; recovery was complete 1 year after embolization<sup>(2)</sup>.

Selective embolization of the penile artery was first described by Wear et al. in 1997, and has been used to treat post-traumatic high flow priapism; internal pudendal artery-urethral fistulae; pseudoaneurysms; and arteriovenous fistulae<sup>(3,4)</sup>. No report has yet described penile necrosis developing after embolization, but ED has been recorded. It remains unclear whether embolization actually causes ED, but transient ED develops soon after embolization in 15–20% of patients. However, the ED then gradually improves from 7 days to 1 year thereafter<sup>(2,9)</sup>.

Chen et al.<sup>(10)</sup> reported a similar case with a bilateral fistula, who was treated via bilateral internal pudendal artery-urethral embolization. However, no side-effects, such as ED or necrosis, were noted. Savoca et al.<sup>(8)</sup> suggested that if a lesion is bilateral, embolization of one side could be deferred to prevent development of an erectile problem. In this report, the patient received only one side of the procedure, but penile necrosis eventually occurred. Therefore, we investigated whether or not penile necrosis was caused by other causes, but no other reason was found.

## CONCLUSIONS

Unexpected penile glans ischemic necrosis developed after internal pudendal arterial embolization of a post-traumatic internal pudendal artery-urethral fistula. To date, no report of penile glans necrosis or ischemia developing after embolization has appeared. This case report underscores that penile glans necrosis can occur as a side effect of internal pudendal arterial embolization. It is necessary to closely observe whether abnormal signs such as color change occur on the glans penis after the procedure.

## ACKNOWLEDGEMENT

None

## CONFLICT OF INTEREST

The authors report no conflict of interest.

## REFERENCES

1. Aslan A, Karaguzel G, Melikoglu M. Severe ischemia of the glans penis following circumcision: a successful treatment via pentoxifylline. *Int J Urol.* 2005;12:705-7.
2. Takao T, Osuga K, Tsujimura A, Matsumiya K, Nonomura N, Okuyama A. Successful superselective arterial embolization for post-traumatic high-flow priapism. *Int J Urol.* 2007;14:254-6.
3. Mitropoulos D, Pappas P, Baniyas C, Leonardou P, Alamanis C, Giannopoulos A. Delayed presentation of posttraumatic internal pudendal artery-urethral fistula treated by selective embolization. *J Trauma.* 2007;63:1388-90.
4. Celtikci P, Ergun O, Tatar IG, Conkbayir I, Hekimoglu B. Superselective arterial embolization of pseudoaneurysm and arteriovenous fistula caused by transurethral resection of the prostate. *Pol J Radiol* 2014;79:352-5.
5. Garrido-Abad P, Suarez-Fonseca C. Glans ischemia after circumcision and dorsal penile nerve block: Case report and review of the literature. *Urol Ann.* 2015;7:541-3.
6. Aminsharifi A, Afsar F, Tourchi A. Delayed glans necrosis after circumcision: role of testosterone in salvaging glans. *Indian J Pediatr.* 2013;80:791-3.
7. Burnett AL. Molecular pharmacotherapeutic targeting of PDE5 for preservation of penile health. *J Androl.* 2008;29:3-14.
8. Rajfer J, Gore JL, Kaufman J, Gonzalez-Cadauid N. Case report: Avoidance of palpable corporal fibrosis due to priapism with upregulators of nitric oxide. *J Sex Med.* 2006;3:173-6.
9. Savoca G, Pietropaolo F, Scieri F, Bertolotto M, Mucelli FP, Belgrano E. Sexual function after highly selective embolization of cavernous artery in patients with high flow priapism: long-term followup. *J Urol.* 2004 ;172:644-7.
10. Chen J, Wang S, Wu D, Wu J. Bilateral internal pudendal artery-urethral fistula formation by pseudoaneurysm. *Acta Orthop Traumatol Turc.* 2015;49:456-8.