

Laparoscopic-Assisted Ureterocystoplasty

BASIRI A, MAGHSOUDI R, SHADPOUR P

Urology/Nephrology Research Center, Shaheed Labbafinejad Medical Center, Shaheed Beheshti Medical Sciences University, Tehran, Iran

KEY WORDS: ureterocystoplasty, ureter, cystoplasty

Introduction

The use of intestine in order to increase bladder capacity is associated with complications such as mucosa production, infection, stone formation, bladder rupture, metabolic disorders, and changes of tissue which lead to malignancy.

Regarding these problems, investigators have used natural non-intestinal materials such as peritoneum, omentum, seromuscular grafts, dura, and de-epithelialized intestinal segment, but the results have been hopeless in long-term.⁽¹⁾

Dilated ureter was applied for the first time by Bellinger and then by Churchill to increase bladder volume and the studies indicated that this method, like intestinal segment, led to an acceptable increase of bladder capacity, but with none

of intestinal segment complications.^(2,3,4)

The use of laparoscopy has had an increasing application in surgical procedures in the recent years and most urologic procedures have been performed by this method even in children.⁽⁵⁾ Mostly, performing ureterocystoplasty needs two flank and suprapubic incisions or one large abdominal midline incision.^(2,3) A new method of ureterocystoplasty is reported in this case study in which first of all nephrectomy is conducted with freeing ureter and preserving blood vessels, then the kidney is removed by Pfannenstiel's incision and ureterocystoplasty is performed at the same site.

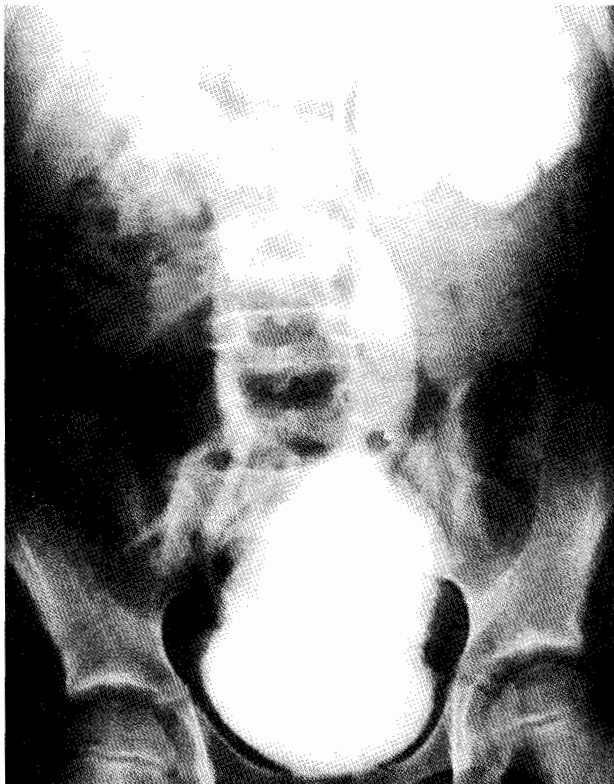


FIG. 1. VCUG before operation

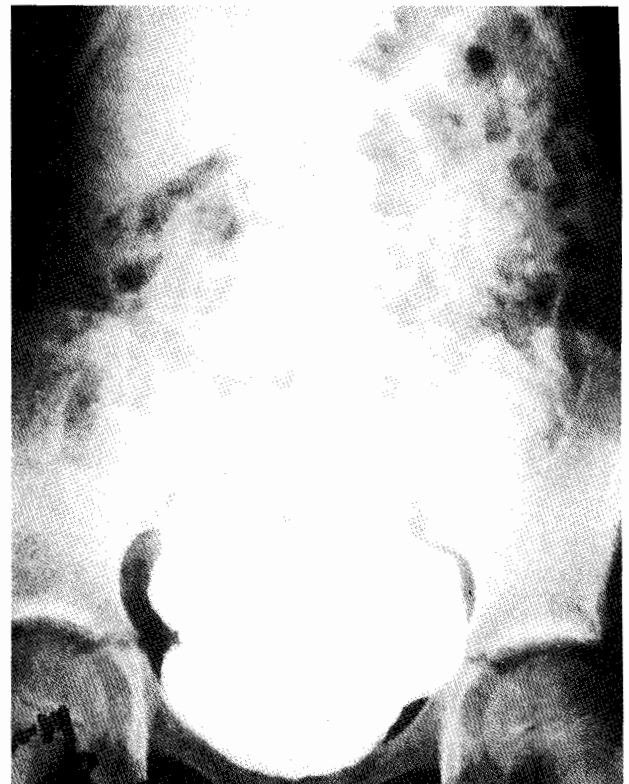


FIG. 2. VCUG after operation

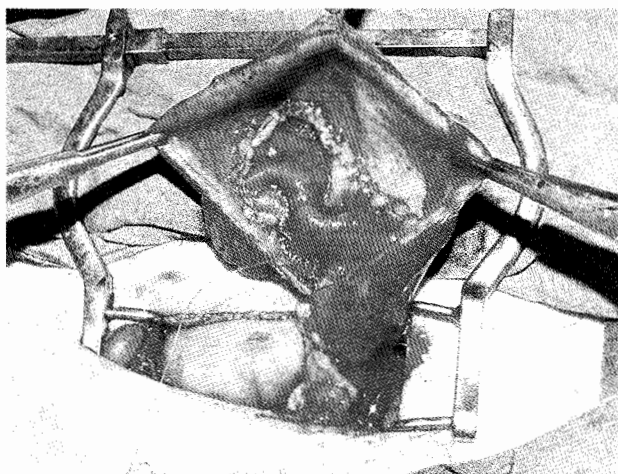


FIG. 3. Intraoperative feature of the patient and the patch made up of ureter

Case Report

A 9-year-old girl with neurogenic bladder and reflux suffered from repeated infections despite the use of prophylactic antibiotic and Baclofen. Blood tests were normal. A hydronephrotic non-functional left kidney with dilated ureter and grade IV reflux in the right kidney were observed in ultrasonography, VCUG, and DMSA scan. Severe bladder and lateral left ureteral orifice trabeculation was seen through cystoscopy. Bladder volume was 50^{CC} and urine residue was 80^{CC}. Accordingly, the patient was candidate for ureterocystoplasty. First the patient underwent nephrectomy in a semi lateral position through laparoscopy, using two 11 mm trocar at umbilicus and pararectal site and one 5 mm trocar between umbilicus and xyphoid. The ureter was longitudinally opened up to 3 cm from ureterovesical junction with preserving blood vessels and was sutured with 3.0 polyglycolic as a patch and after opening the bladder, patch was sutured to the bladder coronally. Drain and urethral catheter were placed. The patient was discharged with a good general condition and with urethral catheter, which was removed 12 days after surgery. Grade I reflux was indicated in the control VCUG which was carried out 4 months after the procedure.(fig. 1,2,3,4)

Discussion

Augmentation of bladder capacity is commonly used in the management of patients with low capacity and high-pressure bladder. The use of intestinal segment is currently considered the most common method applied to increase bladder capacity; however, this method is associated with

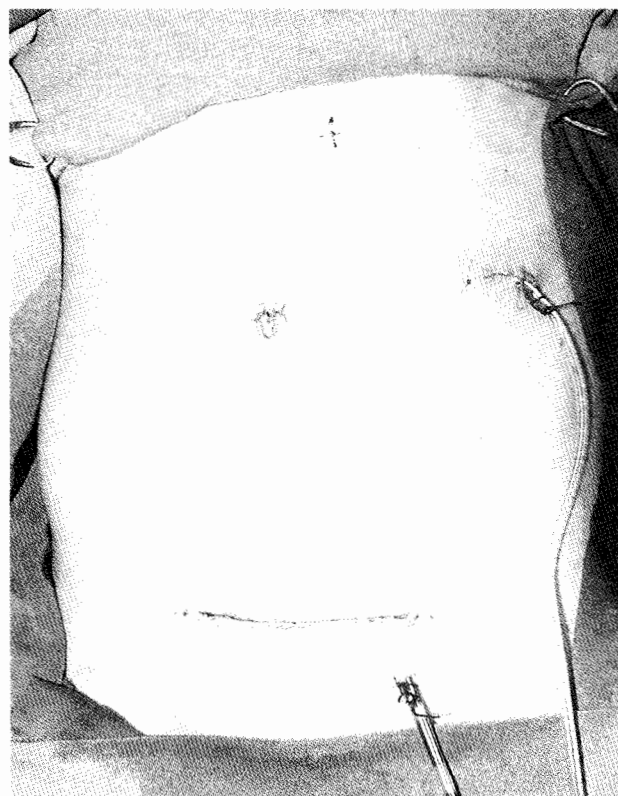


FIG. 4. patient's abdomen after the operation

multiple known complications.⁽⁶⁾

The use of dilated ureter was first reported by Bellinger, followed by Churchill in 1993 and was widely welcomed.^(2,3) The absence of mucosa, elastic surface, an epithelium similar to that of bladder, low microbial growth, and low tendency toward malignancy lead to the popularization of this method and the use of it as an elective method if needed.⁽⁷⁾ Urodynamic findings and clinical results are comparable to ileocystoplasty and there are reports confirm the effectiveness of this method even in ureters with little dilation.^(3,7,8)

Several methods are applied in ureterocystoplasty including two separate incisions and one large intra- or extra-peritoneal incision of abdomen.^(2,3)

In a study, Reinberg performed nephrectomy for which he simultaneously used one posterior incision and one Pfannenstiel's incision to get access to bladder. In comparison to flank and intraperitoneal methods, he recommended this method by which peritoneal cavity remains intact and a little muscular incision is used.⁽⁹⁾ Since patients who are candidate for cystoplasty may need several surgeries and further therapeutic measures in future due to dysplasia and probable renal failure, most surgeons tend to use methods by which less manipulation occurs.⁽¹⁰⁾

Since laparoscopy is practical and less invasive, the tendency for conducting it in children has been recently considered; as, most surgical procedures such as cystoplasty, pyeloplasty and anti-reflux surgery are performable by this method in children.⁽⁵⁾

Sanchez carried out laparoscopic cystoplasty by the use of ileum and ureter via 5 trocars in a patient who had undergone nephrectomy one month ago due to TB.⁽¹¹⁾ We have done nephrectomy and ureterocystoplasty simultaneously via 3 trocars and a 6 cm Pfannenstiel's incision. It is believed that regarding the advantages of this technique such as performing the procedure in one session with few incisions, less manipulation of intra-abdominal space, less postoperative pain, acceptable results such as cosmetic outcome, and early discharge of patient, this method could be a choice in elective cases.

References

1. Atala A, Retik A. Pediatric urology, future perspectives. In: Krane RJ, Siroky MB, Fitzpatrick JM, eds. Clinical urology. Philadelphia: Lippincott; 1994.
2. Bellinger MF. Ureterocystoplasty: A unique method for vesical augmentation in children. *J Urol* 1993; 149: 811-813.
3. Churchill BM, Aliabadi H, Landua EH, et al. Ureteral bladder augmentation. *J Urol* 1993; 150: 716-719.
4. Hanenfellner M, Dahms S, Pfitzenmaier J, Thuroff JW. Orthotopic bladder augmentation and substitution. *Curr Opin Urol* 1999 July; 9(4): 309-14.
5. Seibold J, Janetsche KG, Bartsch G. Laparoscopic surgery in pediatric Urology. *Eur Urol* 1996; 30(3): 394-9.
6. McDougal W. Metabolic complications of urinary intestinal diversion. *J Urol* 1992; 147: 1199.
7. Hitchcock RJI, Duffy PG, Malone PS. Uretero cystoplasty: The Bladder augmentation of choice. Meeting of European society of Peadiatric Urology; 1993 Apr 21.
8. Landau EH, Ayanthi VRJ, Khoury AE, Churchill BM, Gilmour RF, Steckler RE, Mclorie GA. Bladder Augmentation: Ureterocystoplasty versus ileocystoplasty. *J Urol* 1994 Aug; 152: 716-719.
9. Reinberg Y, Robert C, Allen JR, Vaughn Mand, McKenna PA. Nephrectomy combined with lower abdominal extraperitoneal ureteral bladder augmentation in the treatment of children with the vesicoureteral reflux dysplasia syndrome. *J Urol* 1995 Jan; 153: 177-179.
10. Palmer LS, Franco I, Kogan SJ, Reda E, Gill B, Levitt SB. Urolithiasis in children following augmentation cystoplasty. *J Urol* 1993; 150(Pt 2): 726.
11. Sanchezde Badujoz E, Mate Hurtado A, Jimenez Garrido A, Gutierrez de La Cruz JM. Laparoscopic-assisted cystoplasty. *J End Urol* 1995 Jun; 9(3): 269-72.