

## The Effect of Testicular Cryoablation on Testosterone Level in Rats: An Experimental Model of Histopathological Orchiectomy

Serkan Ozcan,<sup>1</sup> Emre Huri,<sup>1</sup> Omer Gokhan Doluoglu,<sup>2\*</sup> Tolga Karakan,<sup>1</sup> Elif Ozer,<sup>2</sup> Vildan Fidanci,<sup>3</sup> Muzaffer Eroglu,<sup>1</sup> Sema Hucumenoglu<sup>1</sup>

**Purpose:** To determine whether testicular cryoablation caused histopathological orchiectomy, and to show its effects on serum total testosterone (t-testosterone) levels in rats.

**Materials and Methods:** A total of 12 Wistar albino male rats were used in this study. The animals were divided into two groups, as cryoablation (9 rats) and control (3 rats) groups. Bilateral cryoablation was performed in the cryoablation group. T-testosterone levels were measured in both groups before scrotal exploration. Bilateral orchiectomy was performed in both groups 10 days after the cryoablation procedure. T-testosterone was measured immediately before orchiectomy. Mann-Whitney *U* test was used for intergroup comparisons.

**Results:** Baseline t-testosterone levels were 1.31 (0.78-2.45) ng/mL and 0.98 (0.91-2.05) ng/mL in the cryoablation and the control groups, respectively ( $P = .92$ ). T-testosterone levels were 0.23 (0.07-1.12) ng/mL and 2.87 (0.63-3.06) ng/mL in the cryoablation and the control groups, respectively, in the blood samples obtained at the time of orchiectomy ( $P = .03$ ). Histopathological examination of rat testes revealed varying degrees of paratesticular inflammation and necrosis in 13 of 18 testes in the cryoablation group. None of 6 testes showed necrosis in the control group.

**Conclusion:** Our study showed that histopathological orchiectomy could be obtained by cryoablation in rat testes.

**Keywords:** disease models; animal; male; orchiectomy; adverse effects; rats, Wistar; testosterone.

### INTRODUCTION

Prostate cells physiologically depend on androgens for stimulation of their growth, function, and proliferation. Testosterone is essential for the growth and perpetuation of tumor cells.<sup>(1)</sup> Testis is the source of most androgens, and adrenal biosynthesis provides only 5-10% of them. This is why androgen deprivation therapy (ADT) has been the main treatment option in advanced prostate cancer (PCa) after Huggins and colleagues.<sup>(2,3)</sup> ADT can be provided through medical and surgical (bilateral orchiectomy) approaches. Surgical castration has still been accepted as the gold standard when compared to the other treatment options. It provides a significant decrease in the testosterone level, and causes hypogonadism at the castration level. However, both treatment options have disadvantages. The most important disadvantage of the surgical castration is its negative psychological effect. Some men may perceive this as an insult to their masculinity. The most important drawback of medical ADT is its cost and its burden to national health assurance since the treatment is administered for a long time. This is why it is logical to investigate new treatment modalities that do not necessitate orchiectomy, and reach the castration level after just one intervention or procedure. In this study, we investigated whether testicular cryoablation resulted in histopathological orchiectomy, and showed its effects on total testosterone levels in rats.

### MATERIALS AND METHODS

#### Study Animals

After the approval of local Ethics Committee, the study was performed in Ankara Education and Research Hospital's Animal Experiment Laboratory, Ankara, Turkey, between August 1-20, 2013, in accordance with the directives on "Rules and Principles of Animal Experiment Laboratories" (NIH publication No. 85-23, revised 1985). A total of 12 Wistar albino male rats, weighing 250-350 g were used in this study. The rats were housed in a room at 20-24°C with a moisture of 60-70%. Twelve-hour light-darkness cycle (dark: 07:00 pm - 07:00 am) was provided. Standard pellets were used to feed the rats, and tap water was used as drinking water. The rats were divided into two groups, as cryoablation (9 rats) and control (3 rats) groups. First, scrotal exploration was performed in both groups. Blood was drawn to measure total testosterone (t-testosterone) levels in both groups before scrotal exploration.

#### Procedures

The genital regions of the rats were shaved and washed with diluted benzalkonium chloride solution before surgery. The surgical field was washed with povidone iodine. A single dose of intraperitoneal ketamine was used for anesthesia, at a dose of 30 mg/kg. Later, a vertical skin and subcutaneous tissue incision was done at the midline of scrotum. Testes were removed after freeing gubernaculum. Only scrotal exploration was

Departments of Urology,<sup>1</sup> Pathology,<sup>2</sup> and Biochemistry,<sup>3</sup> Ankara Training and Research Hospital, Ankara, Turkey.

\*Correspondence: Department of Urology, Ankara Training and Research Hospital, Sukriye Mahallesi Ulucanlar Caddesi.

Tel: +90 533 215 7809. Fax: +90 312 362 4933. E-mail: drdoluoglu@yahoo.com.tr.

Received November 2014 & Accepted April 2015

**Table 1.** Comparison of total testosterone (t-testosterone) levels in cryoablation and the control groups.

Variables	Cryoablation Group (9 rats)	Control Group (3 rats)	P Value
Total testosterone levels before cryoablation (ng/mL)	1.31 (0.78-2.45)	0.98 (0.91-2.05)	.92
Total testosterone levels at the time of orchiectomy (ng/mL)	0.23 (0.07-1.12)	2.87 (0.63-3.06)	.03
Total testosterone levels 72 hours after orchiectomy (ng/mL)	0.05 (0.04-0.43)	0.01 (0.01-0.01)	.38

performed in the control group. Scrotal exploration was done immediately before cryoablation in the cryoablation group, then bilateral cryoablation was performed using Brymill Cry-Ac Portable Cryo device (Figure 1). Tissue freezing procedure was done with liquid nitrogen. A 21G, green, 0.8 × 38 mm injector needle was placed on the device (Figure 1). The needle was stabbed to the testis, and the device was run for 5 minutes until an ice ball was generated. After 15-minutes of thawing, a second nitrogen application was performed. Formation of the ice ball was seen and palpated. The testes were put back, and the incision was sutured. Bilateral orchiectomy was performed in both groups 10 days after the cryoablation procedure. T-testosterone level was measured immediately before orchiectomy. A third blood sample was obtained from the survived rats for t-testosterone measurement 72 hours after orchiectomy (Figure 2, Flowchart).

After macroscopic examination, removed testes were fixed in 10% neutral formalin solution. Tissues were stained with hematoxylin & eosin, and examined by an experienced uropathologist (EO) in Pathology Clinic of Ankara Training and Research Hospital. According to our experiences and observations, the tissues were analyzed for necrosis, inflammation, hyperemia, and edema on histopathological examination, and they were graded as 0, 1+, 2+, or 3+ for active inflammation, hyperemia, edema and paratesticular inflammation, and necrosis (0: none, 1+: ≤ 10% of the included tissue, 2+: 10-49% of the included tissue, 3+: ≥ 50% of the included tissue). The blood samples were stored at -20°C until t-testosterone measurement. T-testosterone measurement was done using Siemens ADVIA Centaur XP (Siemens; Erlangen, Germany) device, with direct chemiluminescence immunoassay method. The normal range of total testosterone was 0.66-5.4 ng/mL for the male rats in this device.

**Statistical Analysis**

Data analysis was performed using the Statistical Package for the Social Science (SPSS Inc, Chicago, Illinois, USA) version 11.5. Mann-Whitney U test was used for the intergroup analysis of continuous variables. Categorical variables were analyzed with Chi square test. Pearson correlation coefficient were used to compare testosterone and degree of necrosis. P values < .05 were considered as statistically significant.

**RESULTS**

Baseline median t-testosterone levels were 1.31 (0.78-2.45) ng/mL and 0.98 (0.91-2.05) ng/mL in the cryoablation and the control groups, respectively (P = .92). The median t-testosterone levels measured at the time of orchiectomy (10 days after cryoablation) were 0.23 (0.07-1.12) ng/mL and 2.87 (0.63-3.06) ng/mL in the cryoablation and the control groups, respectively (P = .03) (Tables 1 and 2). Six rats survived after orchiectomy, and their median t-testosterone levels were 0.05 (0.04-0.43) ng/mL in cryoablation group (4 rats) and 0.01 (0.01-0.01) ng/mL in the control group (2 rats) (P = .38).

Histopathological examination of the rat testes revealed various degrees of paratesticular inflammation and necrosis in 13 of 18 testes in cryoablation group. Necrosis was seen in 100% of 10 testes. Necrosis was not found in any of the 6 testes in the control group. There was a negative correlation between testosterone levels and the degree of inflammation and necrosis (P = .02, r = 0.74). In the control group, there were no significant findings except mild hyperemia in 3, and mild to moderate edema in 3 testes. However, high degrees of active inflammation, hyperemia, and edema were seen in cryoablation group (Table 3) (Figures 3 and 4).

**DISCUSSION**

Androgens are needed for growth and proliferation of the prostate cells. Although testosterone is not tumorigenic, tumor cells need it to proliferate and survive. Androgens are mainly produced by testes. Ninety to ninety-five percent of androgens are produced in testes, and 5-10% is released by the adrenal glands. Apoptosis occurs in prostate cells if androgenic stimulation of the prostate cells is blocked (programmed cell death). Any treatment modality that suppresses androgenic stimulation is called as ADT. ADT can be performed both by suppression of androgen release and by decreasing the effects of circulating androgens (androgen blockage). The treatment is called as complete androgen blockage if both methods are used simultaneously. The standard castration level is determined as < 50 ng/mL for testosterone. Current chemiluminescence tests have found the mean testosterone level as 15 ng/mL after surgical castration. Therefore, castration level was accepted as 20 ng/mL.

ADT is the primary treatment choice in advanced PCa.

**Table 2.** Total testosterone (t-testosterone) levels at the time of orchiectomy in the cryoablation and the control groups.

Variables	Rat 1	Rat 2	Rat 3	Rat 4	Rat 5	Rat 6	Rat 7	Rat 8	Rat 9
Total testosterone levels in cryoablation group (ng/mL)	0.065	0.23	0.076	0.67	0.13	0.29	0.12	0.38	1.12
Total testosterone levels in the control group (ng/mL)	0.63	2.87	3.06	—	—	—	—	—	—

**Table 3.** Histopathological findings in study groups.

Variables	Active Inflammation				Hyperemia				Edema				Paratesticular Inflammation and Necrosis			
	0	+1	+2	+3	0	+1	+2	+3	0	+1	+2	+3	0	+1	+2	+3
Group	0	+1	+2	+3	0	+1	+2	+3	0	+1	+2	+3	0	+1	+2	+3
Cryoablation (n = 18)	0	4	2	12	0	5	8	5	0	4	13	1	5	1	1	11
Control (n = 6)	5	1	0	0	3	3	0	0	3	2	1	0	6	0	0	0
P value	.0001				.001				.003				.004			

(2,4) ADT can be performed by medical or surgical methods. Bilateral orchiectomy has currently been accepted as the gold standard among other ADT methods. The advantages of orchiectomy are its low cost, and easy application under local anesthesia. However, some men may perceive this operation as an insult to their masculinity.<sup>(5)</sup>

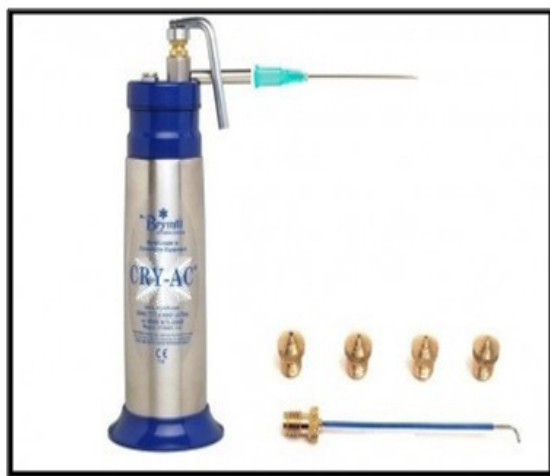Long acting luteinizing-hormone releasing hormone (LH-RH) agonists are the primary agents used for medical ADT. Continuous stimulation of the receptors by these agents caused downregulation of LH-RH receptors, and hence, testosterone levels are suppressed.<sup>(6)</sup> However, the castration levels cannot be reached in approximately 10% of the patients. If castration level is accepted as 20 ng/mL, this value reaches to 15%.<sup>(7)</sup> Flare phenomenon can be seen at the initiation of this treatment, leading to increased bone pain, bladder output obstruction, kidney obstruction and spinal cord compression. Long term use of these agents brings a large economic burden to national health insurance. In Europe, the money spent for the PCa patients diagnosed in 2006 was 106.7-179.0 million Euros.

A formal meta-analysis estimated the cost-effectiveness of different ADT methods in advanced PCa. This study showed that the most cost-effective treatment for ADT was bilateral orchiectomy. The cost-effectiveness of medical hormone therapies was found worse.<sup>(8)</sup> Therefore, it may be logical to investigate cost-effective, new treatment modalities that do not necessitate orchiectomy, and reach the castration level after just one intervention or procedure. Testicular cryoablation has not been performed before in order to suppress androgens. Cryotherapy freezes and kills the cells. Cell death occurs by protein denaturation due to dehydration, direct laceration of the cell membrane by ice crystals, and is-

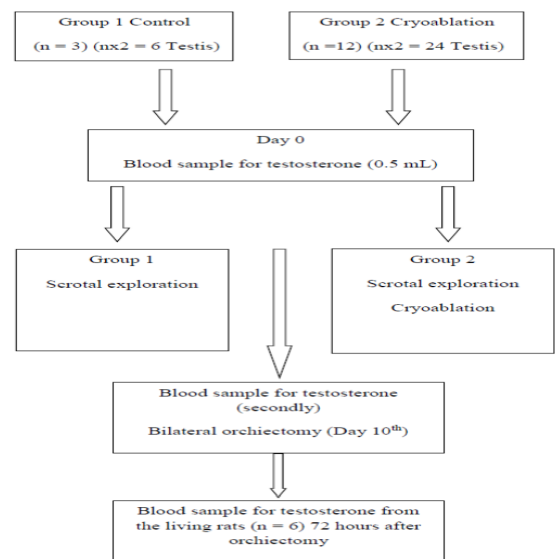
chemia caused by vascular stasis and microthrombi.<sup>(9-12)</sup> Cryotherapy was first used by Gonder and colleagues in the field of urology in 1964 for benign prostatic hyperplasia and PCa.<sup>(13)</sup> This modality has been the preferred method for treatment of localized PCa in elderly patients with comorbidities.<sup>(14)</sup>

In our study, normal testicular tissue was tried to be destroyed by cryoablation, and the histological and biochemical results of cryoablation were analyzed. The t-testosterone level measured at the time of orchiectomy was 0.23 (0.07-1.12) ng/mL in the cryoablation, and 2.87 (0.63-3.06) ng/mL in the control groups. The values obtained in the cryoablation group have suggested that t-testosterone level can be significantly reduced after cryoablation. Histopathological examination revealed varying degrees of paratesticular inflammation and necrosis in 13 of 18 rat testes in the cryoablation group. One hundred percent of 10 testes showed necrosis. Necrosis is followed by fibrosis. Since fibrotic testes will remain in their position, the patients will not have a perception of “testicular absence”. Our results suggest that cryoablation can result in histopathological orchiectomy. When cryotherapy is used for cancer, it is important to preserve neighboring tissues while destructing the cancerous tissue. Since there are no neighboring structures of testes, we suppose that cryotherapy may be a suitable option for ADT.

Systemic inflammatory response may develop after cryoablation,<sup>(15,16)</sup> and may cause hypotension, respiratory distress, multi-organ dysfunction and intravascular coagulation due to cytokine production.<sup>(17)</sup> This response usually develops after cryoablation of masses with large

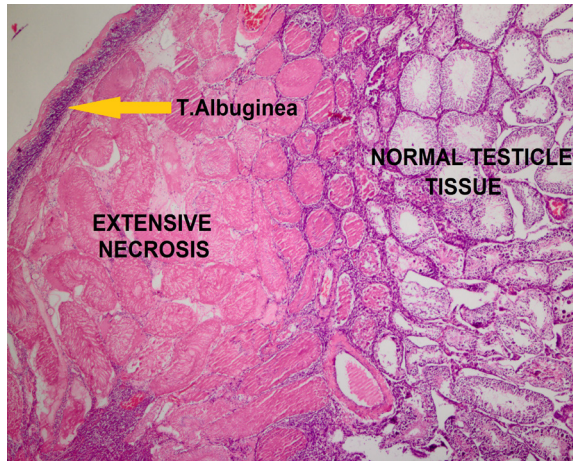


**Figure 1.** Brymill Cry-Ac Portable Cryo device.



**Figure 2.** Study flowchart.



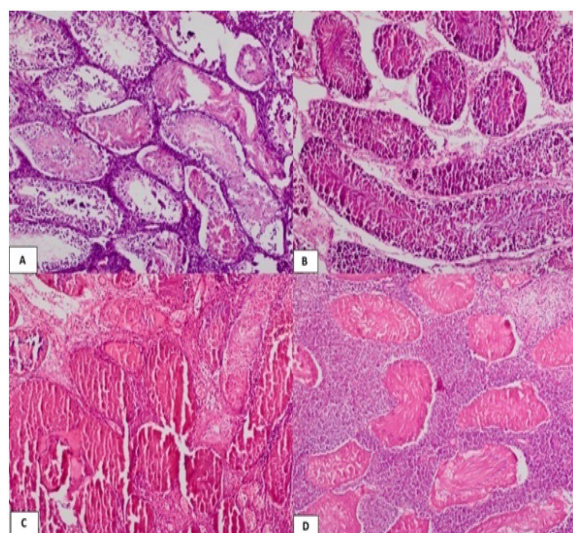


**Figure 3.** Extensive necrosis and normal histological findings in testis (Hematoxylin and eosin stain  $\times 10$ ).

volumes. None of the rats died after cryotherapy, until the time of orchietomy in our study.

### CONCLUSIONS

Our study showed that histopathological orchietomy could be obtained in testes by cryoablation. In our opinion, cryoablation can be an alternative to medical and surgical (orchietomy) castration in patients with advanced PCa. Since orchietomy is not performed, the perception of orchietomy as an insult to masculinity may not appear. In addition, the economic burden of the disease to national health assurance may decrease since castration levels can be reached by a single procedure, and the patients do not have to use LH-RH analogs for a long time. Cryoablation can be performed in the office, under local anesthesia. As we have done, if cheap and easy-to-use systems can be made available, we suppose that cryoablation can be a logical option to achieve castration. Our study is the first study one on this topic, and prospective randomized studies on a larger subject



**Figure 4.** Findings of mild (A), moderate (B), and severe necrosis (C). (D) Extensive necrosis and severe inflammation (Hematoxylin and eosin stain  $\times 40$ ).

group are needed to further clarify this issue.

### CONFLICT OF INTEREST

None declared.

### REFERENCES

1. Berman DM, Rodriguez R, Veltri RW. Development, molecular biology and physiology of the prostate. *Campbell-Walsh Urology*. 10th edn. In: Wein AJ, Kavoussi LR, Novick AC et al (eds). Elsevier 2012. p. 2533-69.
2. Huggins C, Stevens RE Jr, Hodges CV. Studies on prostate cancer. II. The effect of castration on advanced carcinoma of the prostate gland. *Arch Surg*. 1941;43:209-23.
3. Sharifi N, Gulley JL, Dahut WL. Androgen deprivation therapy for prostate cancer. *JAMA*. 2005;294:238-44.
4. Huggins C, Hodges CV. Studies on prostatic cancer. I. The effect of castration, of estrogen and of androgen injection on serum phosphatase in metastatic carcinoma of the prostate. *J Urol*. 2002;167:948-51.
5. Kordan Y. Hormone therapy in metastatic prostate cancer. *Turk Urol Sem*. 2010;1:195-200.
6. Klotz L, Boccon-Gibod L, Shore ND et al. The efficacy and safety of degarelix : a 12-month, comparative, randomized, open-label, parallel-group phase III study in patients with prostate cancer. *BJU Int*. 2008;102:1531-38.
7. Morote J, Planas J, Salvador C, Raventos CX, Cetalan R, Reventos J. Individual variations of serum testosterone in patients with prostate cancer receiving androgen deprivation therapy. *BJU Int*. 2009;103:332-35.
8. Bayoumi AM, Brown AD, Garber AM. Cost-effectiveness of androgen suppression therapies in advanced prostate cancer. *J Natl Cancer Inst*. 2000;92:1731-39.
9. Fahmy WE, Bissada NK. Cryosurgery for prostate cancer. *Arch Androl*. 2003;49:397-407.
10. Rees J, Patel B, Macdonagh R, Persad R. Cryosurgery for prostate cancer. *BJU Int*. 2004;93:710-14.
11. Han KR, Belldegrin AS. Third-generation cryosurgery for primary and recurrent prostate cancer. *BJU Int*. 2004;93:14-8.
12. Beerlage HP, Thüroff S, Madersbacher S, et al. Current status of minimally invasive treatment options for localized prostate carcinoma. *Eur Urol*. 2000;37:2-13.
13. Kim JM, Luo L, Zikrin BR. Caspase-3 activation is required for Leydig cell apoptosis induced by ethane dimethanesulfonate. *Endocrinology*. 2000;5:1846-53.
14. Batur AF, Acar C, Sozen S. Cryoablation in

prostate cancer. *Turkiye Klinikleri J Urol.* 2008;1:79-89.

15. Chapman WC, Debelak JP, Blackwell TS, et al. Hepatic cryoablation-induced acute lung injury: pulmonary hemodynamic and permeability effects in a sheep model. *Arch Surg.* 2000;135:667-72.
16. Washington K, Debelak JP, Gobbell C, et al. Hepatic cryoablation-induced acute lung injury: Histopathologic findings. *J Surg Res.* 2001;95:1-7.
17. Seifert JK, Stewart GJ, Hewitt PM, Bolton EJ, Junginger T, Morris DL. Interleukin-6 and tumor necrosis factor- alpha levels following hepatic cryotherapy: association with volume and duration of freezing. *World J Surg.* 1999;23:1019-26.