

Oculocutaneous Albinism associated with Axenfeld's Anomaly

Three case reports

*B R Keshav, Mahmood J Mohammed, Nasir Mahmood

المهق البصري - الجلدي المرتبط بشذوذ أكسينفيلد تقرير ثلاث حالات

كيشاف، محمود محمد، ناصر محمود

الخلاصة: المهق البصري الجلدي وخلل تكون الأديم المتوسّط الأمامي حالتان وراثيتان معروفتان، لكن حصولهما بنفس الوقت يعتبر نادرا كما ظهر في التقارير. ندرج هنا ثلاث حالات لعائلة بعرض متماثل قد يدل على أن حدوثهما أكثر من مجرد صدفة. هكذا ترابط يستحق الملاحظة لأنه يمكن أن يكون أحد أسباب لمرض العين وضعف البصر في المهق البصري - الجلدي.

مفتاح الكلمات: المهق، البصري - الجلدي، شذوذ أكسينفيلد، وراثية، قرابة، ترابط.

ABSTRACT: Oculocutaneous albinism and anterior mesodermal dysgenesis are well-known heritable conditions, but their occurrence in association has only been rarely reported. We present cases of three siblings of a family with identical presentation suggesting that this association may be more than just a coincidence. This association is worth noting, as this could be one of the causes of ocular morbidity and poor vision in oculocutaneous albinism.

Keywords: Albinism; Oculocutaneous; Axenfeld anomaly; Hereditary; Consanguinity; Association.

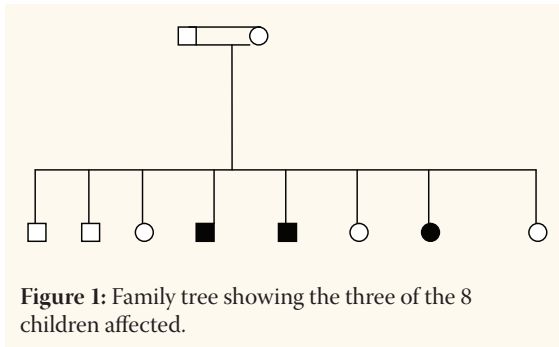
OCULOCUTANEOUS ALBINISM AND mesodermal dysgenesis of the anterior segment are two distinct disorders with different types of inheritance. Oculocutaneous albinism presents as an autosomal recessive disorder and mesodermal dysgenesis as an autosomal dominant disorder. Although there are several studies reporting an association between the two inherited disorders, in each of these case reports, only one case has been reported as having this association.^{1,2,3,4,5} In a study by Izquierdo *et al.*,⁶ four patients with Hermansky-Pudlak syndrome were described as having Axenfeld anomaly. In our cases, all the three siblings had oculocutaneous albinism with nystagmus, iris transillumination, foveal and optic nerve hypoplasia and poor vision. All of them showed Axenfeld anomaly with prominent Schwalbe's line and iridocorneal processes.

Case Reports

Three of the eight children of a family with a history of consanguinity, [Figure 1] who attended the Low Vision clinic of Sur Hospital, Oman, were diagnosed as having oculocutaneous albinism and were worked up for evaluation of low vision and management.

CASE ONE

A boy aged 13 years had been wearing high hypermetropic glasses for the previous three years. On examination, he had a best-corrected visual acuity of 0.2 in each eye. Refraction revealed the following: right eye +9.00sph/-3.0 at 15 degrees, left eye +9.50/-2.0 at 160 degrees pendular nystagmus, and poliosis. Biomicroscopy revealed an anteriorly displaced irregularly thickened posterior embryotoxon (Schwalbe's) in both eyes with iris processes extending to the peripheral cornea [Figure 2]. The iris transillumination was positive, intraocular pressure was 14mm Hg in both eyes and the fundus showed gross choroidal



hypopigmentation, small hypoplastic discs and absent foveal reflex suggestive of foveal hypoplasia [Figure 3]. His systemic history was unremarkable with regard to any evidence of bleeding diathesis or recurrent infections or respiratory problems.

CASE TWO

A boy aged 9 years presented, also with a history of wearing high hypermetropic glasses. His systemic history revealed that he had an extra digit, which was excised. On examination, he had a visual acuity of 0.1 in the right eye and 0.05 in the left one. Refraction showed: right eye +8.00/-3.00 @ 10 degrees, left eye +8.00sph/-3.00 at 165 degrees. Intraocular pressure (IOP) 15mm Hg right eye, 14mm Hg left eye. The rest of the anterior and posterior segments were remarkably similar to his brother's eyes. Blood investigations were negative for sickling. Prothrombin time (PT) and activated partial thromboplastin time (APTT) were 17.2 secs and 33.0 secs respectively and international normalised ratio (INR) was 1.38.

CASE THREE

A girl aged 6 years, sister of the two other siblings mentioned above, presented without a history of wearing glasses with other ocular findings very similar to her those of her brothers. Her uncorrected visual acuity was counting fingers 3m in both eyes. Refraction showed: right eye +8.00sph/-1.00 at 10 degrees, left eye +7.00sph/-2.00 at 160 degrees.

Discussion

Albinism refers to a group of hereditary disorders that involve an abnormality of melanin synthesis or distribution. The term albinism comes from the Latin word *albus*, which means white, and, in 1908, Garrod

first scientifically described it.⁷ Clinically, albinism presents as a pigmentation abnormality of the skin, the hair, and/or the eyes. Albinism can be divided into two broad categories, as follows: oculocutaneous albinism and ocular albinism. Oculocutaneous albinism involves both the skin and the eyes, whereas ocular albinism mainly affects the eyes with minimal to no skin involvement.

The primary morbidity of both oculocutaneous albinism and ocular albinism is eye related. Signs and symptoms include photophobia, refractive errors, monocular vision, strabismus, pendular nystagmus, iris transillumination defects, foveal hypoplasia, and abnormal decussation of the optic nerve fibres. These ocular manifestations are almost always present in both forms of albinism; however, the degree of their presentation can vary depending on the type of albinism and the racial background of the patient.⁷

Oculocutaneous albinism mostly presents in an autosomal recessive form and is mainly of two types, namely tyrosine negative and tyrosine positive albinism. Mesodermal dysgenesis is an autosomal dominant disorder characterised by iridogonio dysgenesis with iris hypoplasia and may be associated with glaucoma and systemic features.⁸ Of the various types of mesodermal dysgenesis, the Axenfeld anomaly is the least severe and presents as an anteriorly displaced Schwalbe's line and iridocorneal processes with or without glaucoma. Only a few studies in the literature have shown the association of albinism and iridocorneal dysgenesis.^{1,2,3,4,5} Lubin *et al.* published a case of a tyrosine negative albino having mesodermal dysgenesis of the Axenfeld type and thought that the association could be coincidental.¹ Another study by Hayakawa *et al.* showed an association of ocular albinism with an Axenfeld type of mesodermal dysgenesis in one Japanese patient and postulated that there could be a common defective factor leading to these two disorders.²

In our report, the occurrence of this association in three siblings in an identical fashion shows that the association is more than coincidental. It has been speculated that mesodermal deficiency is a developmental anomaly that is related to lack of pigmentation in the tissues thus connecting the two diseases.⁴ It has been postulated that a developmental arrest, in the third trimester of gestation, of tissues derived from the neural crest cells accounts for the

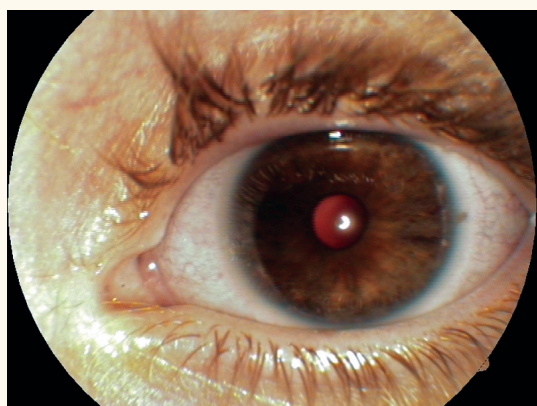


Figure 2: Anteriorly displaced irregularly thickened posterior embryotoxon (Schwalbe's) in both eyes with iris processes extending to the peripheral cornea

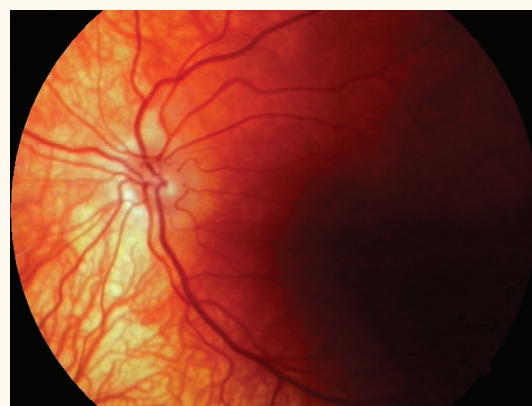


Figure 3: Fundus showed gross choroidal hypopigmentation, small hypoplastic discs and absent foveal reflex suggestive of foveal hypoplasia

ocular and most of the nonocular abnormalities in this group.⁸ Even the melanocytes are of neural crest origin thus supporting their occurrence in a single individual. Our cases also conform to other reports of the common type of mesodermal dysgenesis associated with albinism, which is the Axenfeld anomaly. It is important to be aware of this particular ocular association of anterior mesodermal dysgenesis with albinism. This is because it could be one of the causes of ocular morbidity and loss of vision in albinism, apart from other inherent factors namely: foveal hypoplasia, nystagmus, optic nerve hypoplasia, and increased number of crossed fibres in the optic tract leading to defective cortical projection and squinting.⁷

Conclusion

Several case reports have been published hitherto on the association of oculocutaneous albinism and ocular albinism with anterior mesodermal dysgenesis. Our case report of three siblings with a similar association not only supports this but also goes a step further in proving that the association is more than coincidental and could be caused by a common defective factor. A further insight into the genetics of both the disorders may throw light on the possible genetic linkage between them.

References

1. Lubin JR. Oculocutaneous albinism associated with mesodermal dysgenesis. *Am J Ophthalmol* 1981; 91:347–50.
2. Hayakawa M, Kato K, Nakajima A, Yoshiike T, Ogawa H. Nettleship–Falls X-linked albinism with Axenfeld anomaly: A Case Report. *Ophthalmic Paed Genet* 1986; 7:109–14.
3. Benson W. Oculocutaneous albinism associated with Axenfeld anomaly. *Am J Ophthalmol* 1981; 92:133.
4. Ricci B, Lazerra F. Ocular albinism and corneal mesodermal dysgenesis. *Am J Ophthalmol* 1981; 92:587.
5. Vandorp BD, Delleman JW, Loewer-Sieger DH. Oculocutaneous albinism and anterior chamber cleavage syndrome - not a coincidence. *Clin Genet* 1984; 26:440–4.
6. Izquierdo NJ, Townsend W, Hussels IE. Ocular findings in Hermansky-Pudlak syndrome. *Trans Am Ophthalmol Soc* 1995; 93:191–202.
7. Grønskov K, Jakob EK, Brøndum-Nielsen K. Ocular manifestations of albinism. *Orphanet J Rare Dis* 2007; 2:43.
8. Shields MB, Buckley E, Klintworth GK, Thresher R. Axenfeld-Rieger syndrome - A spectrum of dev disorder. *Surv Ophthalmol* 1985; 29:387–409