

# Fulminant Varicella Zoster Infection with Multiorgan Involvement

## A Case Report

\*Sudheer P S Ahamed,<sup>1</sup> Abdullah Balkhair,<sup>2</sup> Rajan Krishnan<sup>2</sup>

### مرض الفيروس النطاقي الحماقي المعدي الخاطف المصيب لعدة أعضاء تقرير حالة

سودير احامد، عبد الله بالخير، راجان كريشنان

الملخص: يعتبر عدوى الفيروس النطاقي الحماقي من الأمراض المعدية الخفيفة واسعة الانتشار والتي غالباً ما تصيب الأطفال. لكن في الكبار خاصة عند المرضى المصابين بنقص المناعة، يكون العدوى بالفيروس خاطفاً ومهدداً للحياة. ندرج هنا تقرير حالة امرأة شابة لا تعاني من نقص في المناعة والتي أصيبت أعضاء عديدة في جسدها بالفيروس النطاقي الحماقي.

مفتاح الكلمات: الحماق، فيروس الحلا ٣، إنسان، أنجلال الرئيدات، التَّخْتُرُ المُنْتَثِرُ داخل الأوعية، التهاب الرئة، عمان.

**ABSTRACT** *Varicella zoster* infections are considered to be mild and ubiquitous infections predominantly affecting the paediatric population. However, in adults and in specific groups of patients, such as those who are immunosuppressed, varicella infections can be fulminant and life threatening. We here present a case report of a young female patient with a normal immune system who had a fulminant varicella infection with multiorgan involvement.

**Key words:** Chickenpox; Herpes virus 3, human; Rhabdomyolysis; Disseminated intravascular coagulation; Pneumonia; Case report; Oman

**V**aricella virus infection in humans can result in two distinct clinical syndromes: chickenpox and *herpes zoster*. Chickenpox, which develops after initial exposure to the virus, is a common trivial illness of childhood characterised by typical exanthem and a self-limited course. However, in adults, varicella can behave differently with much more severity and involvement of different organ systems.<sup>1,2</sup> This is more common in immunosuppressed patients and those on chemotherapy.<sup>3</sup> In the following case report, we present a case of fulminant varicella infection with multiorgan involvement in an immunocompetent young adult.

## CASE REPORT

Our patient was a 22 year old, unmarried, female university student; a non-smoker with no history of any significant medical illness. The patient first presented to her local health centre in Ibri, Oman with a history of sudden onset of severe back ache radiating to both lower limbs. She also had had a mild fever of 2 days duration. The patient was prescribed analgesic medications and discharged home from the primary centre. She presented the next day to the local hospital in Ibri with the characteristic rash of chickenpox involving her face and trunk. She continued to be febrile during this presentation and also continued to have severe back ache. The patient had been exposed two weeks previously to chickenpox in her family. She was seen

<sup>1</sup>Department of Medicine, Armidale Rural Referral Hospital, Armidale, New South, Wales, Australia; <sup>2</sup>Department of Medicine, Sultan Qaboos University Hospital, Muscat, Sultanate of Oman

\*To whom correspondence should be addressed. Email: sudheerahamed@hotmail.com

**Table 1: Laboratory investigations at Ibri Hospital**

Complete Blood count	Coagulation Profile	Liver Function Tests	Renal function tests
Haemoglobin(Hb)11.2gram/ Neutrophil 80%	Prothrombin Time (PT) 18.8 seconds International Normalised Ratio (INR) 1.65	Alanine amino transferase (ALT) 1278 U/L Aspartate aminotransferase (AST) 2550 U/L	Sodium (Na ) 132mmol/l Potassium (K+ ) 4.3mmol/l
Lymphocyte 16.4%	Activated Partial thromboplastin time (APTT) 40 seconds	Alkaline phosphatase (ALP) 316 U/L	Urea 1.92 mmol/l (5.4mg/dl)
Platelets 235 cells/mm <sup>3</sup>		Bilirubin 44.6 micromol/litre (27mg/dl)	Creatinine 38.89 micromol/litre (0.44mg/dl)

by the internist on call who made a clinical diagnosis of chickenpox. Routine investigations were done and showed elevated liver enzymes with a severely altered profile. Her chest radiograph was normal. The patient was admitted to the Ibri Hospital and started on oral famcyclovir and intravenous ceftriaxone. The patient continued to be febrile throughout her stay in this secondary care institution. The repeat liver function tests showed a further rise and in her liver enzymes and worsening coagulation with high prothrombin time (PT) and activated partial thromboplastin time (APTT). Her fibrin degradation product (FDP) value was reported as very high at 640; however, there was no bleeding from any sites of the body. She received fresh frozen plasma (FFP) and the antibiotics and antiviral drug were continued. The patient was transferred the next day to our institution, Sultan Qaboos University Hospital, for further care. On arrival, she was febrile, drowsy and severely tachycardic and tachypneic with a pulse rate of 140 and respiratory rate of 30. Pulse oxymetry revealed her saturation to be 70% in room air. The polymorphic rash with vesicles and swabs was still present, but limited to the face and trunk. The chest examination revealed fine crepitations bilaterally. There were no focal neurological deficits and abdominal examination did not reveal any organomegaly. The liver span was found to be 7 cm clinically. The patient was immediately admitted to the Intensive Care Unit and was started on noninvasive ventilation. Blood investigations and an urgent chest X-ray were done revealing bilateral nonhomogenous haziness extending up to the mid zone. The liver functions revealed very high enzymes with aspartate aminotransferase in the range of 5555u/l and alanine aminotransferase 2225 u/l with normal bilirubin. The coagulation profile showed gross derangement with high PT time, APTT and thrombin time values. A complete blood count

revealed severe polymorphonuclear leucocytosis with thrombocytopenia. Her blood was sent for varicella serology and polymerase chain reaction (PCR) and also for serology for other viral haemorrhagic fevers such as dengue and Crimean-Congo. The provisional working diagnosis at this stage was fulminant varicella infection with pneumonia, hepatitis and disseminated intravascular coagulation with consumptive coagulopathy along with super added sepsis. The patient was started on acyclovir at a dose of 10 mg/kg 8 hourly and the antibiotics were upgraded to meropenem and amikacin. Cryoprecipitate, FFP and platelet concentrate were administered on suggestion of the haematologist. The patient tolerated the noninvasive ventilation for the next 24 hours, but on the second day of admission she desaturated and had to be intubated and mechanically ventilated. She also started to have fresh bleeding from the Foley catheter and the nasogastric tube. This was associated with a drop in her haemoglobin. Her coagulation profile continued to be deranged in spite of repeated cryoprecipitate and FFP transfusions. Her liver functions also continued to worsen. An ultrasound of her abdomen did not reveal any evidence of obstruction to the biliary tract or reduction in liver size. Vancomycin was added to cover the possibility of staphylococcal sepsis. Her varicella serology was negative for immunoglobulins (IgG and IgM) indicating the susceptibility for infection and the *Varicella zoster* virus polymerase chain reaction (VZV PCR) in her blood was reported as positive indicating ongoing viraemia. Other serological tests, including human immunodeficiency virus (HIV), dengue and Crimean-Congo fevers were negative. A peripheral smear examination showed evidence of disseminated intravascular coagulation (DIC) and suggested sepsis, with no underlying haematological abnormalities. On the third day of admission, the patient continued to

**Table 2: Results of laboratory investigations on the patient**

Date	Day-1	Day-2	Day-3	Day-5	Day-10	Day-12	Day-15	Day-17
<b>Complete Blood Count</b>								
Haemoglobin	10.9	6.7	8.3	8.4	8.2	10.2	11.2	9.9g/dl
Total Count	30.9	23.2	27.7	16.1	9.9	10.2	12.2	10.7cells/mm <sup>3</sup>
Neutrophil	76.6	79	88.4	77.1	61.2	72	74.9	74.9%
Lymphocyte	18.7	16.8	8.7	11.3	18.8	11.4	10.6	13.4%
Platelets	75	76	90	32	72	203	494	495 cells/mm <sup>3</sup>
<b>Liver Function Test</b>								
ALT	2524	2327	860	245	87	67	49U/L	
AST	5555	4360	2958	540	89	49	49 U/L	
ALP	357	416	185	160	161	155	170 U/L	
Albumin	280	270	310	280	300	320	350 G?L	
Bilirubin	530.1	649	906.3	2907	1333	1060	974 $\mu$ mol/litre	
Protein	520	490	540	500	600	630	710 g/l	
<b>Coagulation profile</b>								
PT	18.2	14.6	13	11	11.1	11.4	11 seconds	
INR	1.77	1.42	1.25	1.05	1.06	1.09	1.05	
APTT	76	58	48	39	38	36	32.7 seconds	
Thrombin Time	54.6	59.4	34.6	24	13.8	13.8	13.9 seconds	
<b>Varicella serology</b>	<b>-ve</b>					<b>IgM+</b>		

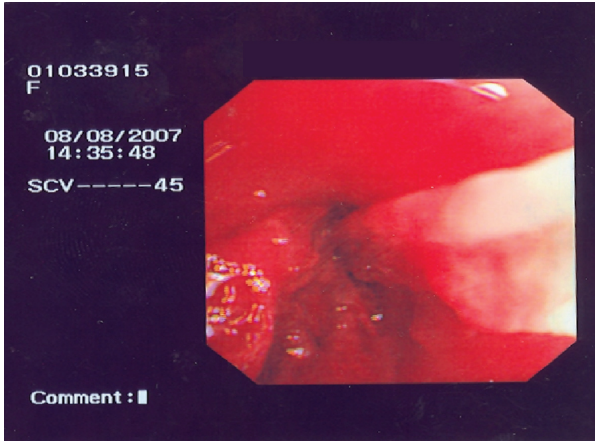ALT = alanine aminotransferase; AST = aspartate aminotransferase; ALP = alkaline phosphatase; PT = prothombin time; INR = international normalized ratio; APTT = activated partial thromboplastin time

be sick and her ventilatory requirements rose significantly. A repeat chest X-ray showed extension of the haziness bilaterally, especially on the left side. An urgent pulmonology opinion was sought and the patient underwent an emergency bronchoscopy during which thick gelatin like mucous plugs were removed from both sides. The lungs cleared significantly after this procedure and the ventilatory requirements in terms of oxygen requirement and positive end-expiratory pressure (PEEP) started decreasing over the next few days. However, her coagulation continued to be abnormal for the next 3 days although the liver function tests showed a progressive decline in the enzymes, but with a rising bilirubin level. This bilirubin was predominantly unconjugated and was thought to be a result of the ongoing haemolysis. A PCR performed on a bronchoalveolar lavage specimen revealed the deoxyribonucleic acid of the *Varicella zoster* virus. On advice of the haematologist, the patient continued to receive packed red blood cells concentrate, platelet concentrates, FFP and cryoprecipitates based on her coagulation profile. The patient started showing signs of improvement in terms of coagulation profile by the 7<sup>th</sup> day of admission and over the next few days her FFP and cryoprecipitate requirements came down. Bleeding from the catheter and nasogastric tube stopped by the 10<sup>th</sup> day and the ventilatory parameters showed a

steady improvement. The liver function test also gradually improved with normalization of her enzymes and bilirubin. She was extubated on the 14<sup>th</sup> day of admission, but had a resurgence of fever the next day and a repeat sputum culture grew *Pseudomonas aeruginosa*. She was continued on antibiotics and vigorous chest physiotherapy. She became afebrile two days later and was shifted to the ward on 17<sup>th</sup> day of admission. The patient continued to improve steadily and was discharged on the 21<sup>st</sup> day of admission. Her varicella serology was repeated in the second week and came out to be positive indicating an acute infection. A repeat VZR PCR was negative. The final diagnosis at discharge was severe *Varicella zoster* infection with varicella hepatitis, pneumonia and coagulopathy.

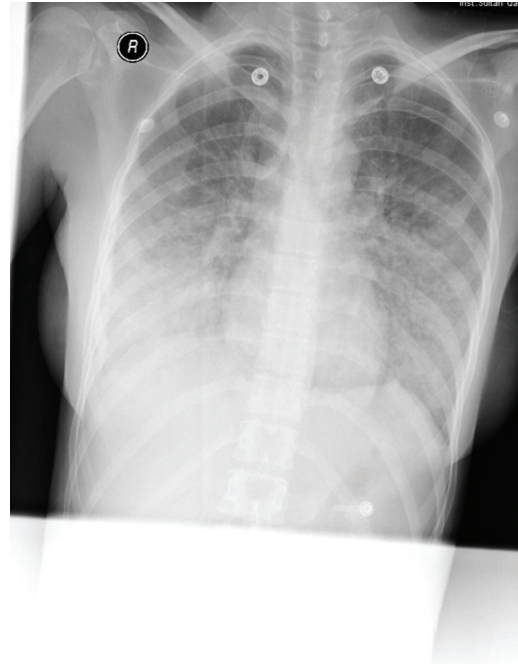
## DISCUSSION

*Varicella zoster* is a DNA virus belonging to the family of *Herpes viridae* and causes the two distinct clinical syndromes of varicella chickenpox and *herpes zoster*. The attack rate for varicella is approximately 90% in susceptible individuals. In the majority of the cases, especially in children, varicella is a very mild infection characterised by skin lesions, low grade fever and malaise. The skin lesions include maculopapules, vesicles and swabs in various stages of development and appear on the trunk and face initially, before spreading



**Figure 1:** Gelatinous plugs from the lung being removed bronchoscopically

to other parts of the body. The patient is infectious 48 hours before the onset of the rash and throughout the vesicle development until all the vesicles are crusted. The severity of rash varies from person to person. Immunocompromised patients tend to have a more severe rash and are more prone to visceral involvement.<sup>3</sup> Our patient was a 22 year old healthy female student and the reason for the fulminating nature of her varicella remains unclear. The diagnosis of varicella was confirmed serologically as well as with VZV PCR. She initially had severe back ache, which is not a characteristic presentation of varicella. The cause for this symptom could be a myeloradiculopathy which has been reported as a neurological complication of varicella infection.<sup>3</sup> The rapidity of clinical deterioration and involvement of multiple organ systems of the body was the most striking feature in this patient. The patient had a clear chest X-ray initially, only developing features of pneumonia on the 4<sup>th</sup> day of admission, followed by rapid respiratory deterioration needing urgent intubation. Special emphasis has to be placed on the role of bronchoscopy in these patients, which will help in clearing the thick gelatin like mucous plugs, especially in cases of nonresolving pneumonias. The severe coagulopathy leading to disseminated intravascular coagulation needed constant support with cryoprecipitate and FFP along with platelet concentrates. The use of appropriate antibiotics to prevent bacterial infections, especially by streptococcus and staphylococcus, also helped in controlling the features of sepsis in this patient. Our case emphasizes the fact that varicella infection in immunocompetent adults can be severely complicated and potentially fatal. Various studies have shown the rate of visceral involvement in varicella in-



**Figure 2:** Chest X-ray on the day of admission

fection in the immunocompromised to be around 30-50% and, in the absence of treatment, 15% of cases can be fatal.<sup>1,4</sup> However, there are no authoritative studies to show the magnitude of visceral involvement or fatality with varicella infection in immunocompetent individuals. In a recent study conducted in Saudi Arabia, the complication rate in varicella infection was found to be 1.5% and the overall fatality rate was found to be 0.05%.<sup>5</sup> Another study in Germany, done to assess the epidemiological pattern of varicella complications, revealed the majority as neurological with encephalitis leading the list.<sup>6</sup> This was followed by infectious complications; in particular infection by *streptococcus pyogenes* was associated with a worse outcome. Other known complications of varicella include myocarditis, hepatitis, rhabdomyolysis with renal failure, acute glomerulonephritis and arthritis.<sup>7,8</sup> The possibility of these complications and the unpredictability of the severity of varicella infection in adults indicates the need for early treatment with antivirals and immunisation in seronegative adults.<sup>9</sup>

## CONCLUSION

Our case demonstrates the fact that varicella infections can be life threatening even in immunocompetent adult patients. The pattern of involvement of multiple systems is also of interest and made the management of this patient quite challenging. The importance of supportive care and significance of early bronchos-

copy for the removal of gelatinous mucous plugs in the management of varicella pneumonia needs to be stressed in addition to antiviral therapy. Our case also rightly raises the question of the importance of vaccination against varicella virus infections at least in patients with high risk of developing a severe disease.<sup>10</sup>

### REFERENCES

1. Whitley RJ. Varicella zoster virus infections. In: Harrison's Principles of Internal Medicine. 16<sup>th</sup> ed. New York: McGraw Hill, 2006. p. 1042-1045.
2. Hollensten U, Thalahamer F, Burggmann H. DIC and rhabdomyolysis in fulminant varicella infection - case report and review of literature. *Infection* 1998; 306-308.
3. Arvin. A. Ageing, Immunity and Varicella zoster viruses. *N Eng J Med* June 2005; 352:2266-2267.
4. Brunnel PA. Varicella zoster infections. In: Cecil Text book of Medicine. Philadelphia: WB Saunders & Co, 1985. p. 88
5. Almuneef M, Memish ZA, BalkeyHH, Altoaiby B, Helmy M. Chickenpox complications in Saudi Arabia: Is it time for routine varicella vaccinations? *Int J Inf Diseases* 2006; 10:156-161.
6. Ziebold C, Vonkries R, Lang R, Weigl J, Schmitt HJ. Severe complications of varicella in previously healthy children in Germany - A 1 year survey. *Paediatrics* 2001;108:E79
7. Al Langawi M, Al-Marri MR, Al Soub H. Rhabdomyolysis associated with varicella infection. *Int J Clinical Practice* 2001; 55:484-485.
8. Cameron JC, Allan G, Johnston AGF. Severe complications of chickenpox in hospitalized children in UK and Ireland. *Arch Dis Childhood*; 2007; 92:1051-1052.
9. Gershon AA, Katz SL. Perspective on varicella vaccine. *J Infect Dis* 2008; 1:197.
10. Varicella vaccine information. Centre for Disease Control. From [www.cdc.gov](http://www.cdc.gov). Accessed December 2007.