

# Combination of Calcipotriene 0.005% Foam and Halobetasol Propionate 0.05% Foam in the Treatment of Scalp Psoriasis

Alexis Young MD<sup>a</sup> and Rhonda Schreiber MSRN<sup>b</sup>

## SYNOPSIS

Psoriasis affects ~3.2% of Americans, with plaque psoriasis being the most common manifestation on the body and scalp.<sup>1</sup> AAD guidelines recommend vitamin D<sub>3</sub> analogs and corticosteroids as front-line topical treatments for plaque psoriasis.<sup>2</sup> However, it can be difficult to treat scalp psoriasis because of the hair covering the areas of disease.<sup>1</sup> It is important to find a topical treatment vehicle that can penetrate beyond the hair to reach the plaque and penetrate the dermis effectively, while avoiding greasy residue that is likely to lead to patient non-adherence to the prescribed treatment regimen.<sup>3</sup> In recent years foam formulations of the vitamin D<sub>3</sub> analogue calcipotriene and the corticosteroid halobetasol propionate have been developed and are both indicated as monotherapies for the treatment of plaque psoriasis.<sup>4,5</sup> Both foams are perceived by patients to be non-greasy, to leave no residue in hair bearing areas, and patient adherence is high in regimens that incorporate the foams.<sup>6</sup> Vitamin D<sub>3</sub> analogues, such as calcipotriene, are believed to mimic the effect vitamin D has shown in inhibiting hyperkeratinization, normalizing epidermal cellular differentiation, and inhibiting the production of several pro-inflammatory cytokines involved in psoriasis.<sup>3</sup> The efficacy of calcipotriene is not decreased with long term use and calcipotriene 0.005% foam has a proven safety and efficacy profile in patients 4 and older.<sup>3,5</sup> Topical corticosteroids, such as halobetasol propionate, are believed to mimic the effect of natural cortisol in down-regulating the inflammatory cascade to rapidly decrease inflammation in psoriasis, but also decrease plaque size due to their skin thinning effect.<sup>2</sup> Super potent steroids, such as halobetasol propionate 0.05% foam, are recommended to be used for short periods of time or on a rotating basis due to potential local and systemic side effects.<sup>2,3</sup> For this reason, it is recommended to use topical steroids and calcipotriene concomitantly or in rotation to treat psoriasis.<sup>7</sup> While calcipotriene 0.005% foam and halobetasol propionate 0.05% foam were shown to be chemically compatible in-vitro, there have been no clinical trials assessing combination use with patients to date.<sup>8</sup> This case study documents the results of a regimen incorporating these topical foam products concomitantly in the treatment of scalp psoriasis.

## METHODS

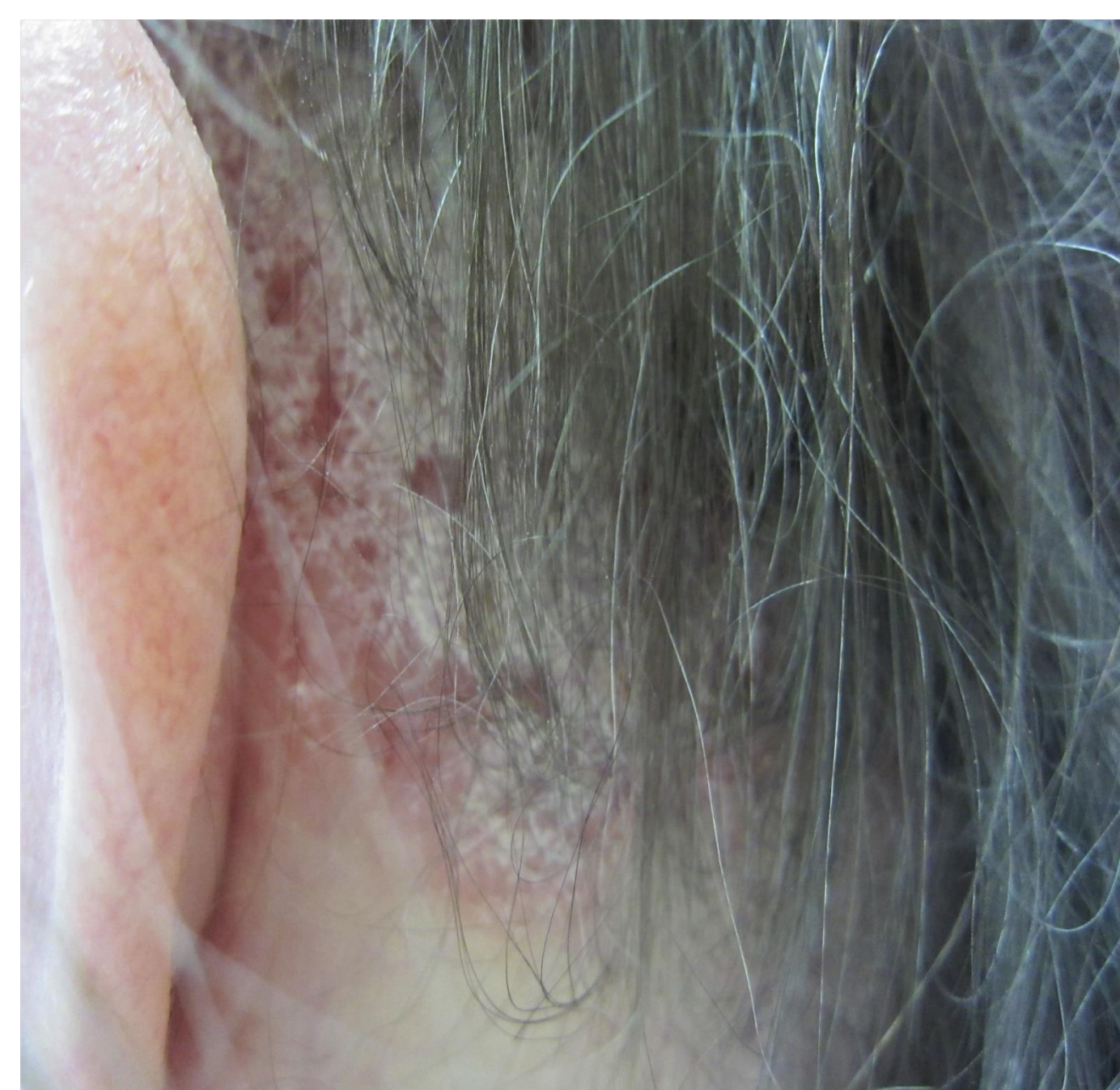- Two patients with plaque psoriasis of the scalp
- Both had tried various treatment options with limited success
  - Patient 1 had used clobetasol solution intermittently for 10 years, but was very dissatisfied with the formulation.
  - Patient 2 had tried fluocinolone solution, triamcinolone 0.1% cream, and hydrocortisone valerate 0.2% cream without improvement in her psoriasis in the 6 months her since diagnosis.
- Both were prescribed halobetasol 0.05% foam and calcipotriene 0.005% foam twice daily for two weeks followed by continued treatment with calcipotriene foam twice daily:
  - Halobetasol foam was to be applied first followed by calcipotriene foam with a 5 minute interval between application during the combination phase.
- The severity of their disease was assessed at baseline and at a 4 week follow up visit.
- Photographs to document the results were obtained at both visits for each patient.

### Patient Demographics

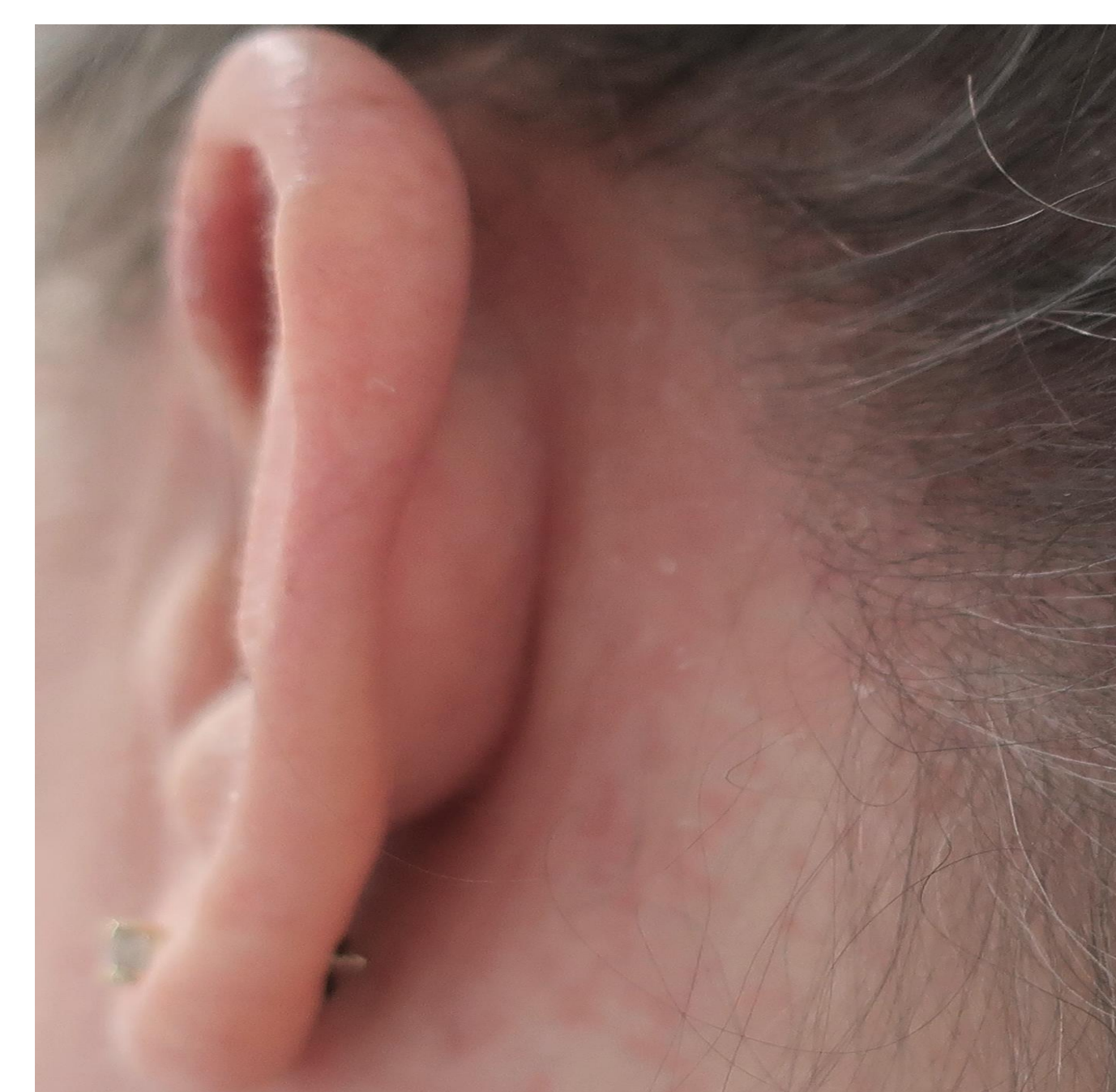Characteristic	Patient 1	Patient 2
Age (yrs)	59	59
Duration of Disease (yrs)	10	<1
Baseline Disease Severity	Moderate	Moderate
Baseline BSA	10	10
Baseline QOL Impact	High	High

## RESULTS

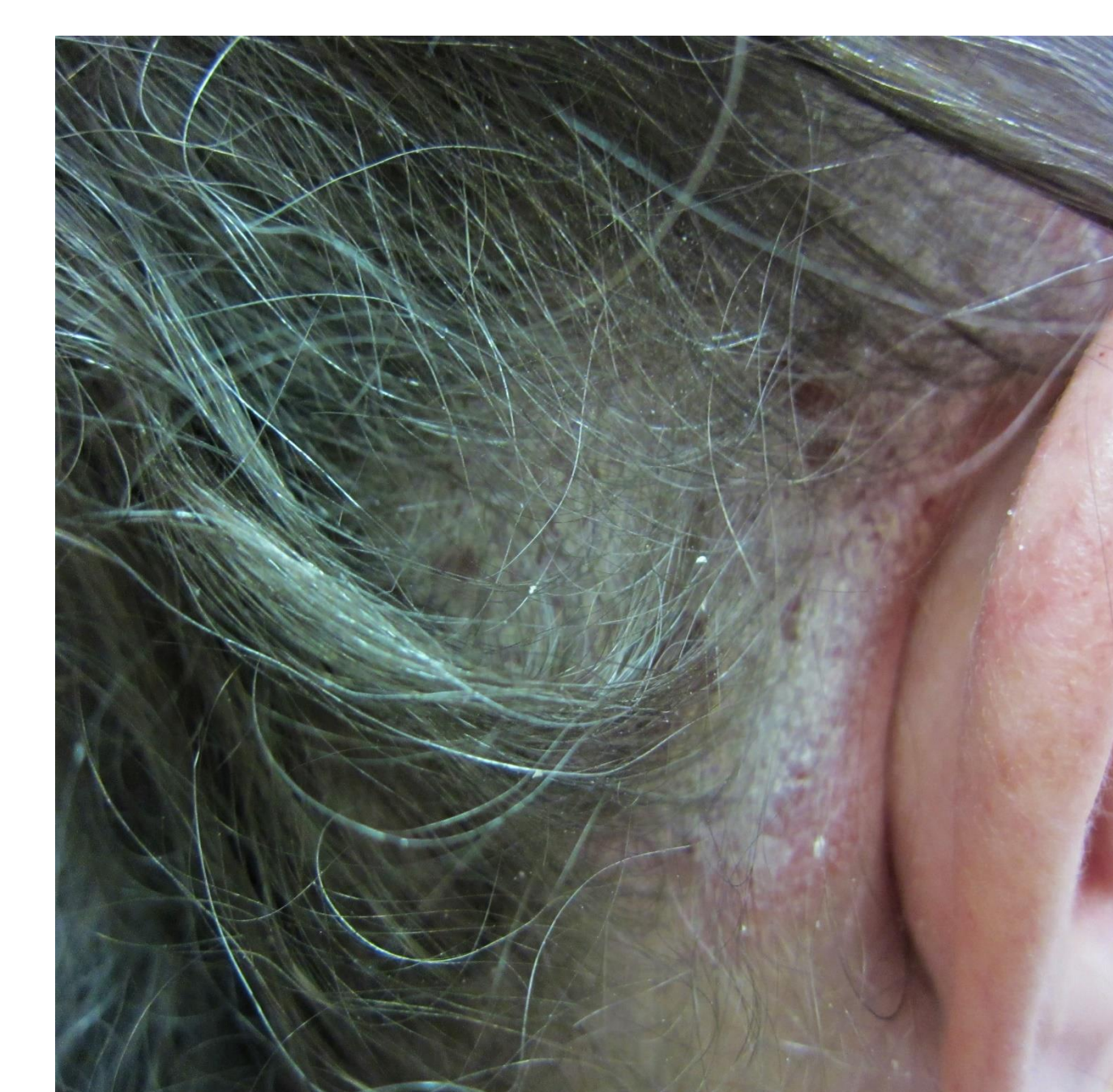**Patient One:** At the Week 4 follow-up visit the patient's psoriatic lesions on the treated areas were clear. She stated she had achieved clearance with the combination of calcipotriene and halobetasol foams after the first 2 weeks. She then stopped use of halobetasol foam, 0.05% and remained clear with the continued use of calcipotriene foam, 0.005% a few times per week in the 2 weeks leading up to her follow-up visit. She stated high satisfaction with the results achieved in the 2 week combination period and the lack of return of disease during her time using calcipotriene foam alone. She stated a higher satisfaction with the foam vehicles compared to prior treatments she had tried; noting that the foams penetrated quickly, with no burning, and left no residue. She experienced no adverse events related to combination use. She has been prescribed to continue use of calcipotriene foam, but to return to the twice daily regimen.



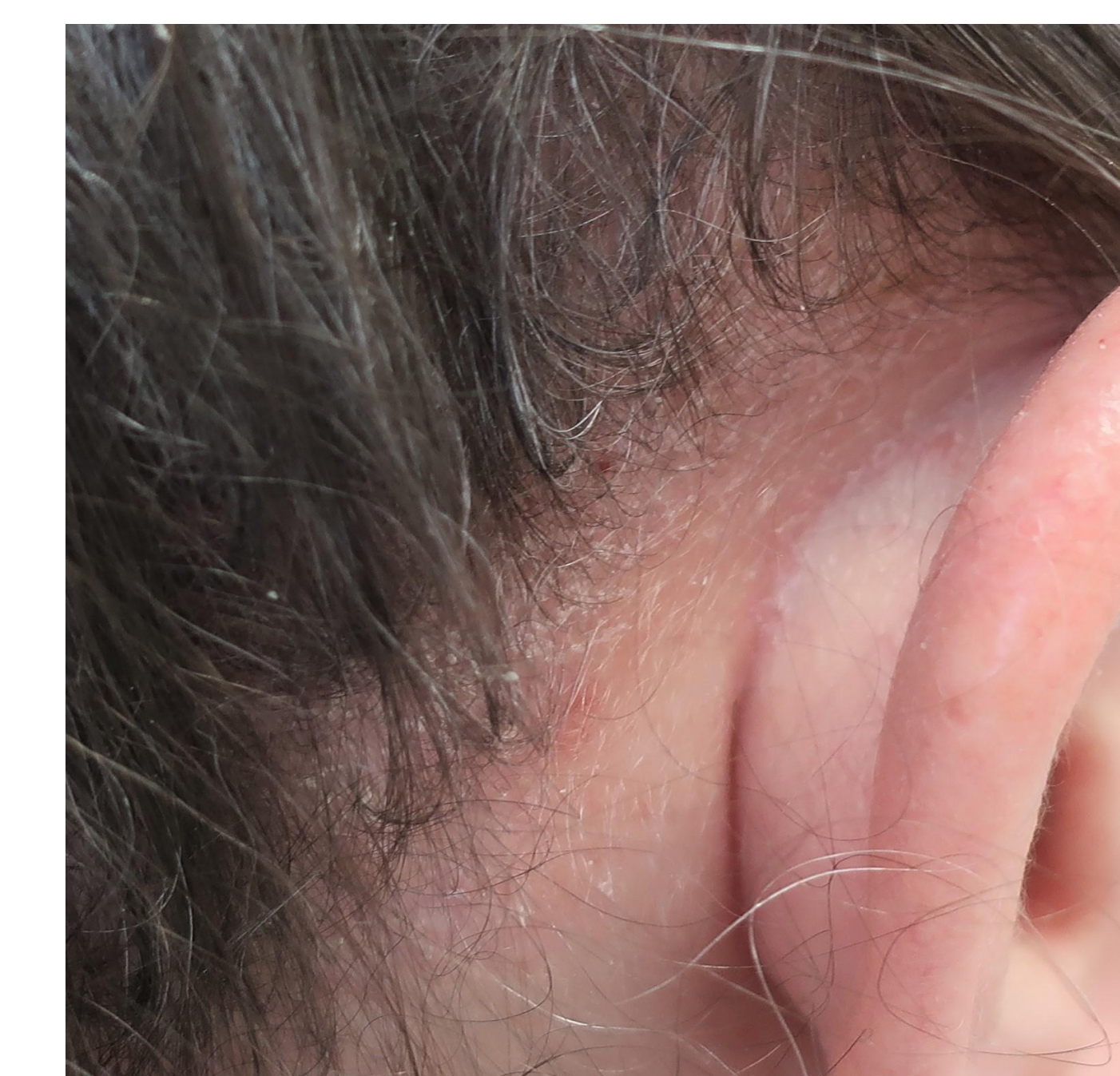**Patient 1**  
Left ear baseline



**Patient 1**  
Left ear at Week 4

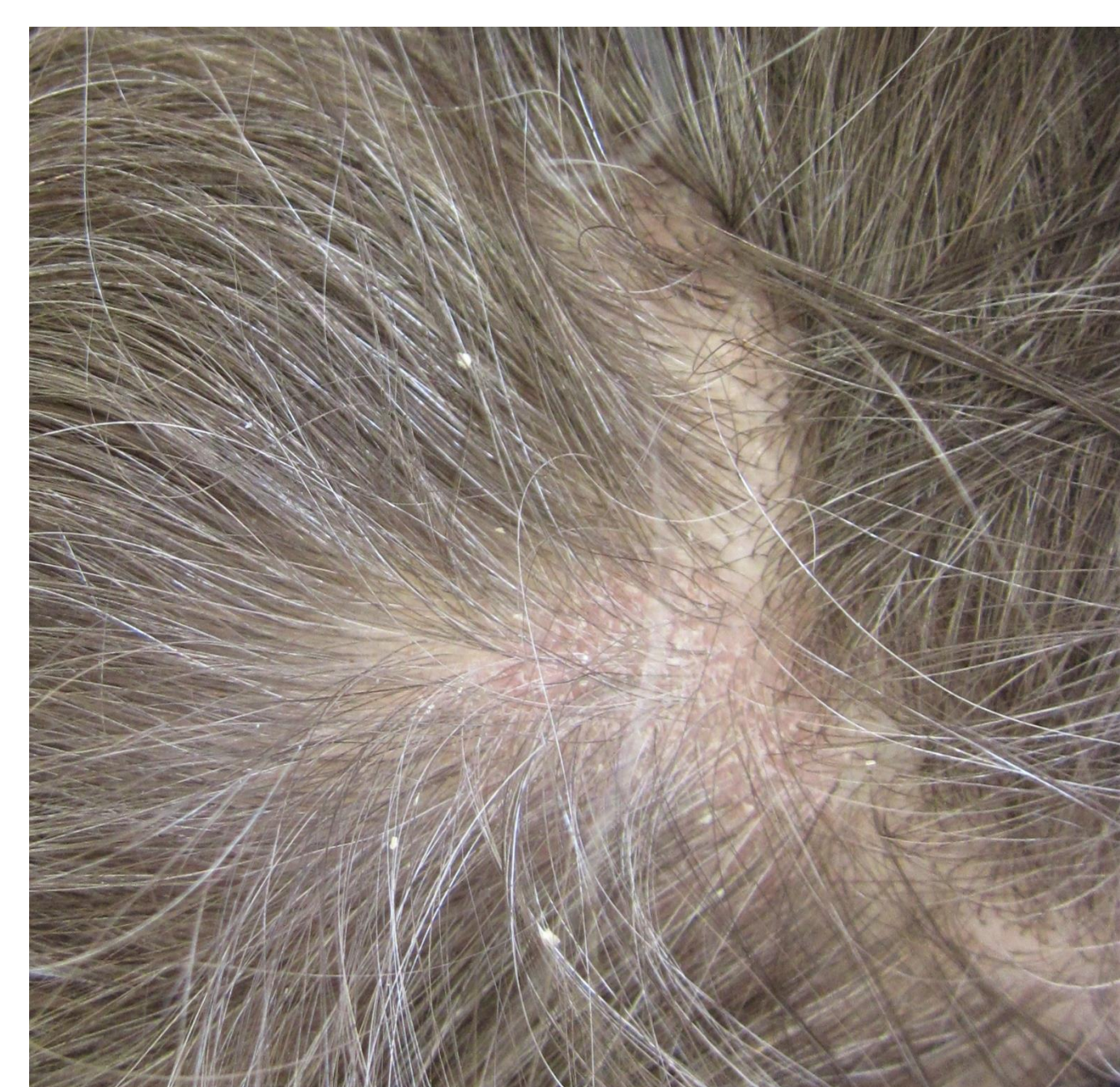

**Patient 1**  
Right ear baseline

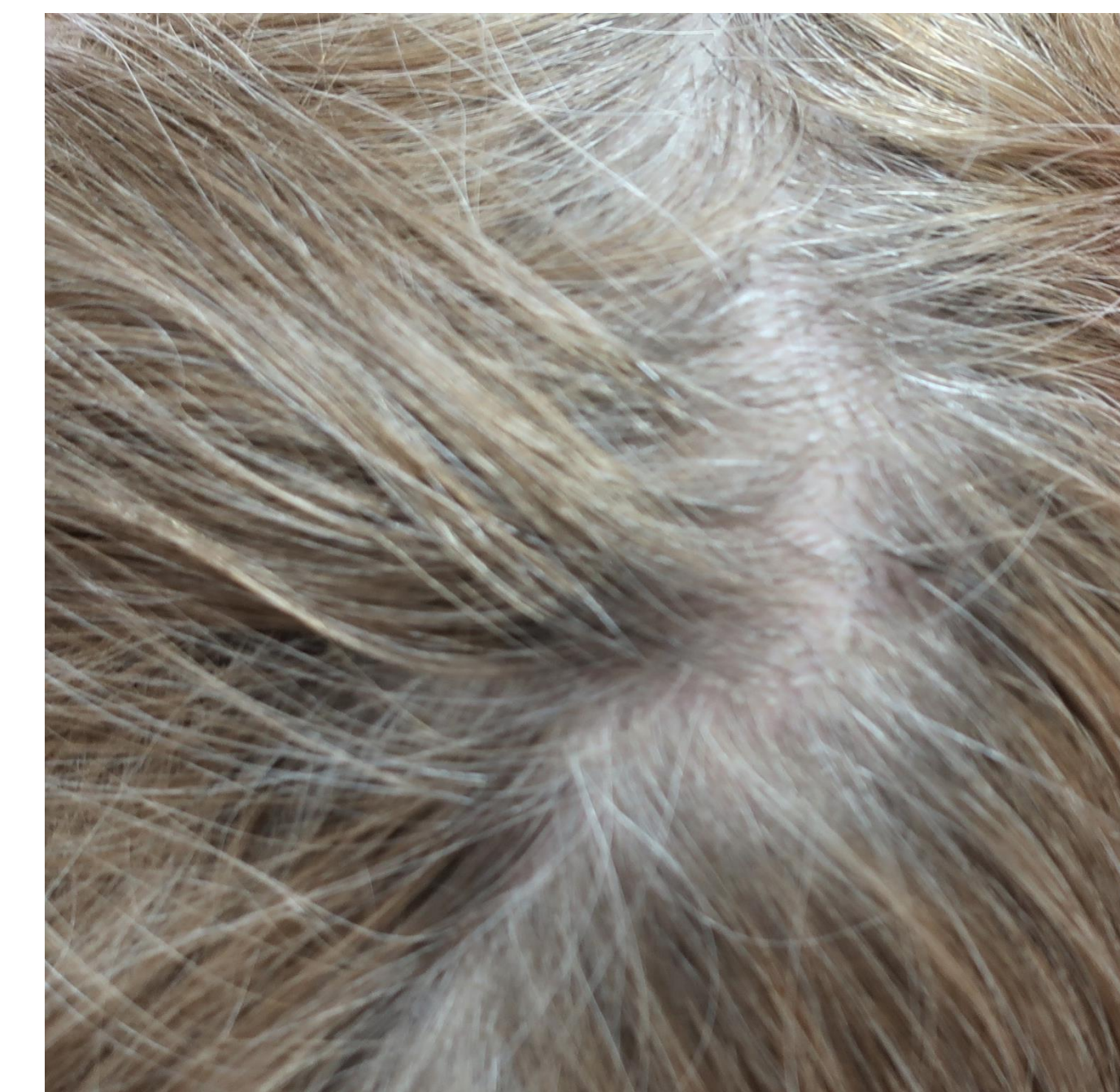


**Patient 1**  
Right ear at Week 4

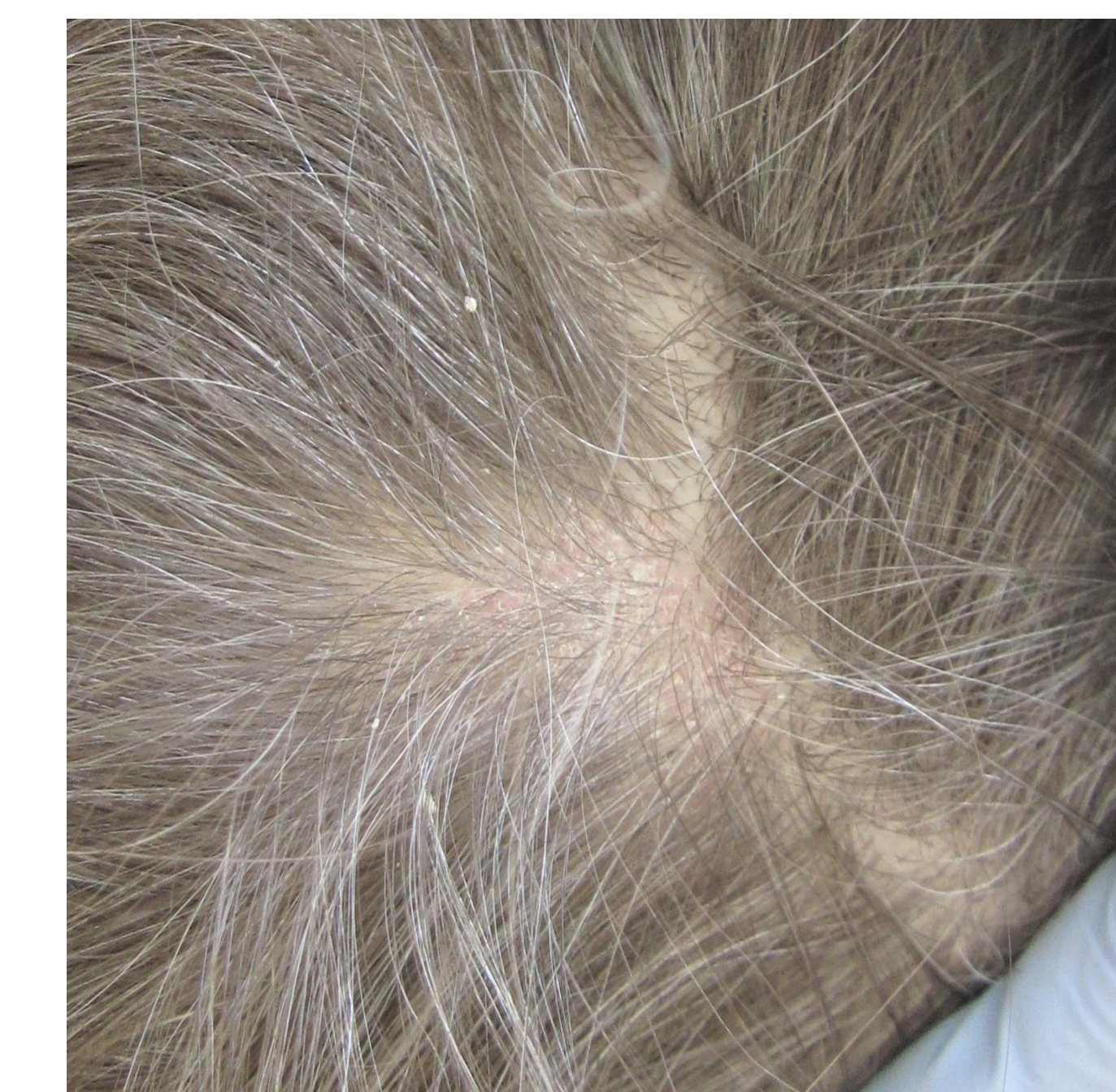**Patient Two:** The second patient stated she had achieved clearance with the combination regimen at 2 weeks, but was showing some signs of flare at week four despite continued use of calcipotriene foam, 0.005% twice daily as prescribed. She reported that she had seen signs of return of disease 1 week after stopping halobetasol foam, but continued on the prescribed regimen of calcipotriene foam twice daily until her follow-up visit. She stated very high satisfaction with the two foam vehicles and the results achieved with both in combination for 2 weeks. She attributed her compliance to the prescribed regimen to her satisfaction with the quick penetration of the foam vehicles, their lack of residue, and absence of burning upon application as compared to prior treatments. She stated she had experienced no adverse events related to combination use. She was resumed on 2 weeks of combination use to be followed a rotating regimen of calcipotriene foam twice daily with halobetasol foam twice weekly to maintain clearance.



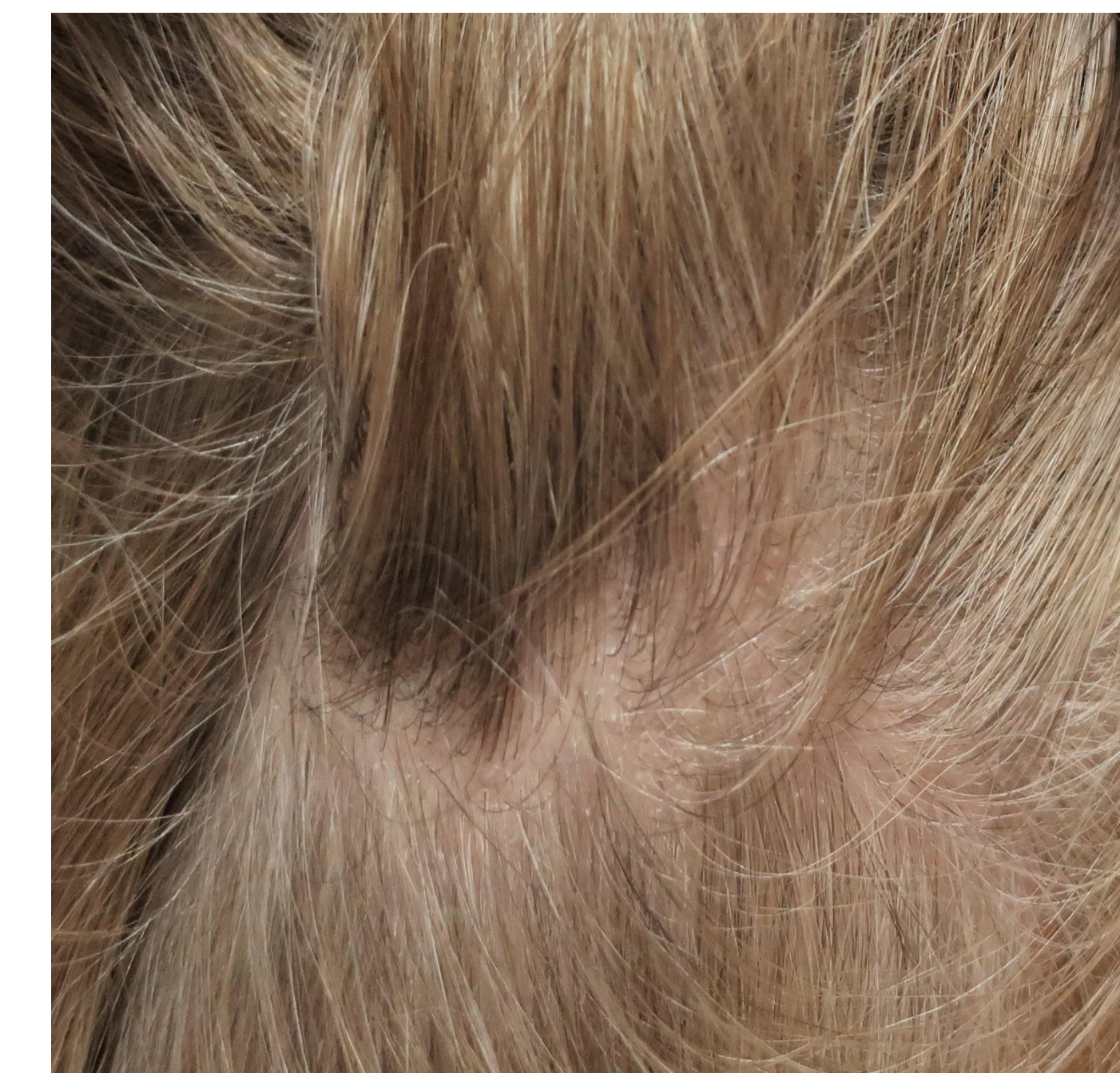**Patient 2**  
Scalp baseline



**Patient 2**  
Scalp Week 4



**Patient 2**  
Scalp baseline



**Patient 2**  
Scalp at Week 4

## CONCLUSIONS

The combination of calcipotriene 0.005% and halobetasol 0.05% foams in the treatment of plaque psoriasis of the scalp achieved good treatment outcomes in clearance at week 2 and created no mal-effect on the efficacy of either product. The variance between the two patients in maintained clearance at week 4 with continued use of calcipotriene 0.005% foam may point to the need to consider pulse treatment or as needed re-treatment with halobetasol foam for flares for some patients. The two foams were not only well tolerated, but the patients stated they were compliant with use due to their high satisfaction with the two vehicles and results achieved. These results may indicate the need for a larger study of these two products in combination use.

## REFERENCES

1. National Psoriasis Foundation. (2019, July 31). About Psoriasis. Retrieved from Psoriasis.Org: [www.psoriasis.org/parents/about-psoriasis](http://www.psoriasis.org/parents/about-psoriasis).
2. American Academy of Dermatology. (n.d.). Psoriasis clinical guideline. Retrieved December 24, 2019, from [aad.org: https://www.aad.org/member/clinical-quality/guidelines/psoriasis](https://www.aad.org/member/clinical-quality/guidelines/psoriasis).
3. Gudjonsson, J. E., & Elder, J. T. (2019). Chapter 28: Psoriasis. In S. Kang, M. Amagai, A. L. Bruckner, & et al (Eds.), Fitzpatrick's Dermatology (9 ed.). New York, NY: McGraw Hill.
4. Mayne Pharma. (2019, May 14). SORILUX Prescribing Information. Greenville, NC.
5. Mayne Pharma. (2019, April). Halobetasol Foam, 0.05% Prescribing Information. Greenville, NC.
6. Mayne Pharma. (2019). Data on file.
7. Van de Kerkhof, P. C. (2001). Therapeutic strategies: Rotational therapy and combinations. Clin Exp Dermatol, 26, 356.
8. Stein Gold, L., Horgan, A., Schreiber, R., & Ye, R. (2019). Determination of the In Vitro Chemical Compatibility of Calcipotriene Foam, 0.005%, in Combination with Halobetasol Propionate Foam, 0.05%. Winter Clinical Dermatology Conference. Kawaii, HI: FRED.

## DISCLOSURES

a. Dr. Young is a Core Assistant Professor, Department of Internal Medicine, Hackensack-Meridian School of Medicine and an Assistant Clinical Professor of Dermatology, Department of Dermatology, Columbia University Medical Center. b. Mrs. Schreiber is the Director of Medical Affairs at Mayne Pharma. Case study drug was supplied under an educational grant from Mayne Pharma.