

Low Rate of Keloid Recurrences Following Treatment of Keloidectomy Sites with a Biological Effective Dose 30 of Superficial Radiation

Brian Berman, M.D., Ph.D
Mark S. Nestor, M.D., Ph.D
Joshua Fox, M.D.
Michael Jones, M.D.
George Schmieder, D.O.
Eduardo T. Weiss, M.D.

PURPOSE

Recurrences of keloids at sites of previously excised keloids is a well-recognized common occurrence following keloidectomy, and based on review of the published literature, has been reported to occur approximately in 71% of cases. Superficial radiation therapy (SRT) reduces wound fibroblast proliferation and enhances apoptosis. In this multicenter, case series report the recurrence rate of keloids post keloidectomy with perioperative treatment with a biological effective dose 30 of superficial radiation was determined.

DESIGN

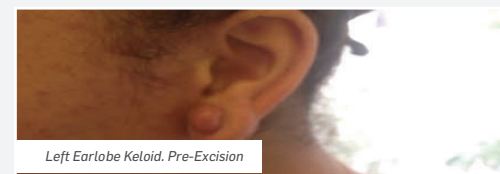
132 keloids in 104 patients were surgically excised. On postoperative day 1 the suture closure line with a 5 mm margin received a biologically effective dose 30 (BED 30), either 70 kV or 100 kV, of superficial radiation. One of the 3 following superficial radiation BED 30 fractionation protocols was employed post keloidectomy: one fraction of 13 Gy on postoperative day 1; or 2 fractions of 8 Gy on postoperative days 1 and 2; or 3 fractions of 6 Gy on postoperative days 1, 2 and 3.

Keloidectomies and superficial radiation therapy (SRT) treatments were performed at one of 5 facilities from November 2013-January 2017.

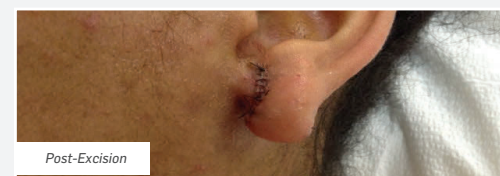RESULTS

The 132 SRT-treated keloidectomy sites were in 6 anatomical sites: ear (40), head/neck (23), arm/shoulder (17), back/buttocks (9), chest/abdomen (34), and scalp (9). The follow-up period ranged from 3 months to 3 years, with the majority (83/104) have been followed for more than 1 year.

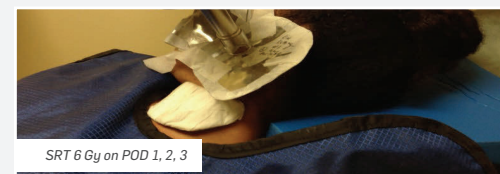Two (1.9%) keloids recurred at excision sites. One recurrence occurred in a patient who had received a single fraction of 13 Gy. The second recurrence occurred in a woman following excision of her chest keloid and SRT treatment, and wound dehiscence 10 days postoperatively and subsequently let to heal by secondary intent. Hyperpigmentation in the irradiated field was the most common adverse event, noted in a minority of patients and which tended to resolve after several months posttreatment.



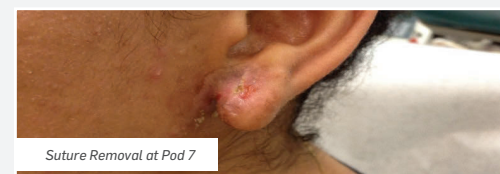Left Earlobe Keloid, Pre-Excision



Post-Excision



SRT 6 Gy on POD 1, 2, 3



Suture Removal at Pod 7

CONCLUSION

The observed 1.9% rate of keloid recurrence following keloidectomy and excision site treatment with superficial radiation therapy (BED 30) is markedly lower than that reported in the literature following keloid excision alone.