

SKINimages

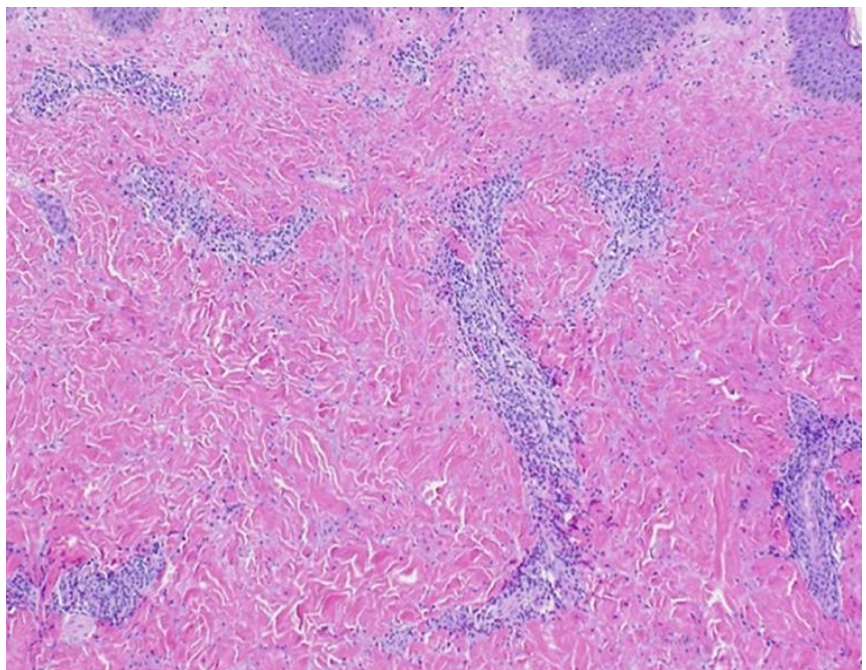
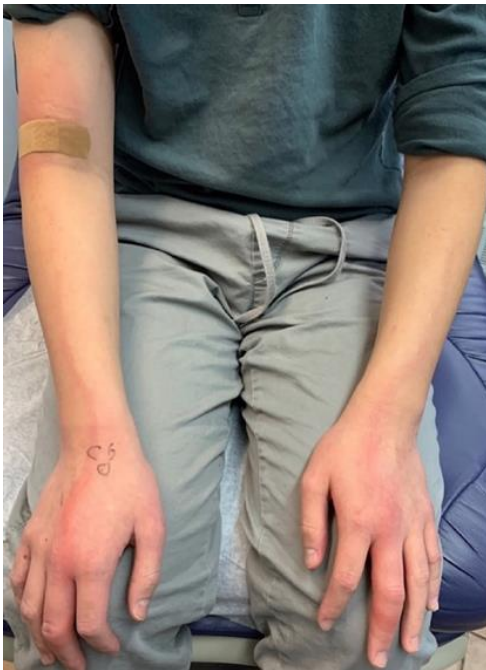Bilateral Upper Extremities Linear Eruption in a 12-Year-Old-Boy

Faraz Yousefian, DO¹, Aurel Apple, DO², Ann Lin, DO, MS, FAAD³

¹ Center for Clinical and Cosmetic Research, Aventura, FL

² St. Barnabas Hospital Department of Dermatology, Bronx, NY

³ University of South Florida Department of Dermatology and Cutaneous Surgery, Tampa, FL



Wells syndrome, eosinophilic cellulitis, is infrequently reported in children and is characterized by sudden, recurrent, painful, or pruritic edematous plaques resembling cellulitis or erysipelas most commonly seen on the extremities.¹ It also may be accompanied by systemic symptoms such as fever and arthralgia.^{2,3} Histologically, flame figures are often present but are not pathognomonic.^{2,4}

In this image, a twelve-year-old boy with a past medical history of asthma, presented with a pruritic rash for one day that started on his hands and spread to his upper extremity. No accompanied systemic symptoms. The patient's mother stated the patient has sporadically had similar episodes on the face and arms for the past 3-4 years, which improved with tapering a course of oral prednisone.

The physical exam revealed warm linear erythematous plaques located bilaterally on the patient's hands, forearms, and upper arms (**Figure 1**). Two 3 mm punch biopsies of the right upper medial arm were performed which captured the perivascular and interstitial infiltrates of lymphocytes and eosinophils in the superficial dermis on hematoxylin and eosin stain (**Figure 2**).

The exact pathogenesis of Wells syndrome is unknown.² It is proposed that this condition is due to various triggers, such as arthropod assault, medications, allergic contact dermatitis, or underlying myeloproliferative infections.¹ It is believed that IL-2 leads to eosinophil degranulation through signaling effects.⁵ Insect bites-Correct. Insect bites, vaccination, hypersensitivity reaction, fungal infections, parasite infestations, and viral infections have been most commonly reported to be associated with Wells syndrome.¹⁻³

Along with history, clinical picture, and dermatopathology examination could help confirm the diagnosis of Wells syndrome. CBC with differential cell counts can be ordered as a follow-up order since peripheral eosinophilia to a moderate degree (1500 to 5000 cells/mm³) has been reported in about half of the patients.^{2,3} Wells syndrome has a good prognosis and a spontaneous resolution of 1-2 months.^{1,3} In severe cases, the initial treatment is prednisone 10-80mg daily or a tapering course which results in drastic improvement within a few days.³

Conflict of Interest Disclosures: None

Funding: None

Corresponding Author:

Faraz Yousefian, DO
2925 Aventura Blvd Ste 205
Aventura, FL, 33180
Email: Yousefian.faraz@gmail.com

References:

1. Šajn M, Luzar B, Zver S. Wells' syndrome possibly caused by hematologic malignancy, influenza vaccination or ibrutinib: A case report. *World J Clin Cases.* 2022;10(30):10997-11003.
2. Safran T, Masckauchan M, Maj J, Green L. Wells syndrome secondary to influenza vaccination: A case report and review of the literature. *Hum Vaccin Immunother.* 2018;14(4):958-960.
3. Heinig B, Vojvodic A, Lotti T, Tirant M, Wollina U. Wells Syndrome - An Odyssey. *Open Access Maced J Med Sci.* 2019;7(18):3002-3005.
4. Watanabe Y, Yamamoto M, Igari S, Yamamoto T. Two Cases of Wells Syndrome with Marked Swelling in the Hands. *Indian Dermatol Online J.* 2020;11(6):979-982.
5. Simon HU, Plötz S, Simon D, et al. Interleukin-2 primes eosinophil degranulation in hypereosinophilia and Wells' syndrome. *Eur J Immunol.* 2003;33(4):834-839.