

Retrospective audit of serum vitamin D levels in patients who underwent Latarjet procedure for anterior shoulder instability

Archie P Rachuene,¹  Roopam Dey,^{1,2*}  Shaun de Villiers,¹ Kirsty Berry,¹ Mike Mulder,¹ Jean-Pierre du Plessis,¹ Stephen Roche¹

¹ Department of Surgery, Division of Orthopaedic Surgery, Groote Schuur Hospital, Cape Town, South Africa

² Department of Human Biology, Division of Biomedical Engineering, University of Cape Town, South Africa

*Corresponding author: roopam.dey@uct.ac.za

Citation: Rachuene AP, Dey R, De Villiers S, Berry K, Mulder M, Du Plessis J-P, Roche S. Retrospective audit of serum vitamin D levels in patients who underwent Latarjet procedure for anterior shoulder instability. *SA Orthop J*. 2022;21(4):212-216. <http://dx.doi.org/10.17159/2309-8309/2022/v21n4a4>

Editor: Dr Cameron Anley, Stellenbosch University, Cape Town, South Africa

Received: November 2021

Accepted: May 2022

Published: November 2022

Copyright: © 2022 Rachuene AP. This is an open-access article distributed under the terms of the Creative Commons Attribution Licence, which permits unrestricted use, distribution and reproduction in any medium, provided the original author and source are credited.

Funding: This study was funded by Johnson & Johnson (Depuy Synthes) and Smith & Nephew, through a sponsored fellowship training.

Conflict of interest: The authors declare they have no conflicts of interest that are directly or indirectly related to the research.

Abstract

Background

The aim of this study was to review vitamin D levels in patients who underwent Latarjet procedures at a tertiary teaching hospital and a private clinic.

Methods

A retrospective review of clinical and radiological records was performed for 22 patients who underwent Latarjet procedure between November 2017 and June 2019. Postoperative vitamin D levels were retrieved and classified into sufficient (> 75 nmol/L), insufficient (25–75 nmol/L), and deficient (< 25 nmol/L) groups. Two observers assessed radiographic images of the patients at six weeks and three months after surgery. Any bone resorption, fracture and nonunion were reported, and interobserver reliability was analysed using the intraclass correlation coefficient (ICC).

Results

The median age was 20.5 years and was predominantly male. A little more than two-thirds (68.1%) of the patients were found to have insufficient or deficient levels of vitamin D. One patient from the insufficient group had postoperative bone resorption. Good interobserver reliability was observed with the ICC value being 0.86.

Conclusion

This study found a prevalence of insufficient/deficient vitamin D levels in young patients undergoing a Latarjet procedure. This study serves as a reminder to orthopaedic surgeons that vitamin D deficiency is prevalent among patients undergoing Latarjet.

Level of evidence: Level 4

Keywords: vitamin D, retrospective audit, bone-block resorption, modified Latarjet, low-resource setting

Introduction

Anterior shoulder dislocation is common, and nearly 50% of these patients are younger than the age of 30 years.^{1,2} About 85% of all anterior shoulder dislocations have an associated Bankart lesion, and Hill–Sachs lesion is present in all of the cases with recurrent dislocations.² Recurrent shoulder dislocations have been reported to develop within two years of the initial injury and the risk of recurrence is higher in the younger patient population group, usually males and those who participate in contact sports or repeated overhead activities.^{2,3} Soft tissue repair (Bankart repair) and bone-block reconstruction procedures such as Latarjet are

commonly performed stabilisation procedures for anterior shoulder instability.⁴

The risk of re-dislocation following an arthroscopic Bankart repair increases with glenoid bone loss of more than 20%.⁵ The modified Latarjet procedure has become the treatment of choice in patients with associated significant anterior glenoid bone loss and contact athletes.^{6–8} A high rate of complication has been reported, with 4–10% of cases undergoing revision surgery.^{8,9} Prevalence of coracoid bone resorption is high following Latarjet procedure, with up to 90% reported by CT scan-based studies; however, this appears to be of minimal clinical significance.¹⁰

Vitamin D deficiency is a problem that commonly affects postmenopausal females and it is estimated to affect over 1 billion people globally.¹¹ Vitamin D has been reported to play a critical role in bone formation and bone healing; therefore, its deficiency can affect bone healing and bone-block incorporation post Latarjet.¹¹⁻¹³ The role of vitamin D in shoulder pathologies has been described before. Oh et al. found vitamin D deficiency to be associated with high-grade fatty infiltration in patients with rotator cuff tears.¹⁴ Reports of serum vitamin D levels in patients undergoing Latarjet surgery does not exist in current literature. This study aims at assessing vitamin D levels of patients undergoing Latarjet at clinical centres.

Materials and methods

After obtaining approval from the institutional review board, a retrospective review of the surgical database at a tertiary teaching hospital and of a private clinic was conducted. Consecutive patients who underwent the modified Latarjet procedure from 2017 to 2019 were considered for this study. These patients were operated by a single shoulder surgeon or by an associate under his direct supervision.

Patients had vitamin D levels tested following surgery. For this study, the serum vitamin D levels of these patients were retrieved. Those patients whose vitamin D levels were unavailable were excluded from the study. The serum vitamin D levels were classified into normal, insufficient and deficient, according to the Canadian Institute of Medicine recommendations.¹⁵ Normal serum vitamin D level was set as > 75 nmol/L, suboptimal or insufficient vitamin D level was set as 25–75 nmol/L, and deficient vitamin D level was set as < 25 nmol/L. Vitamin D levels were only done on patients we felt had possibly had softer bone when preparing the coracoid graft.

If the patient had deficient or insufficient serum vitamin D levels, they were supplemented with vitamin D 50 000 IU weekly for three months. As a part of this study, we wanted to find the effect this supplementation had on the postoperative bone healing. Therefore, a radiological review of the routine six-week and three-month postoperative X-rays was performed by two independent observers. The anteroposterior, lateral outlet, and modified axillary view of the X-rays were reviewed for presence of screw osteolysis (defined as radiolucency around the screws), bone-block fracture, bone-block resorption and/or bone-block nonunion (defined as clear uninterrupted lucent line between the bone block and native glenoid on at least two views at minimum three months follow-up).

Statistical analysis

All the statistical tests were done in IBM SPSS v.26 (Armonk, NY, USA). Interobserver reliability was tested using the intraclass correlation coefficient (ICC) which was calculated using the absolute agreement two-way mixed model. ICC values were reported according to the guidelines present in the literature.¹⁶ Chi-square tests were performed to find the dependency between patients' vitamin D levels, patients' age, and coracoid graft healing. The condition for statistical significance was set at $p < 0.05$.

Results

The retrospective review of patient records found 64 patients who had undergone a modified Latarjet procedure between January 2017 and April 2019. Twenty-two patients satisfied the inclusion criteria and were included in the study (Table I). The median age of this cohort was 20.5 years (range: 16–49 years), and 20 were male.

Insufficient vitamin D levels were found in 12 patients (54.5%) and three patients (13.6%) had deficient vitamin D levels. Seven

Table I: Demographic distribution and vitamin D levels of the study population

Case no.	Sex	Age (years)	25-hydroxy (OH) vitamin D level (nmol/L)
1	Male	16	70.8
2	Male	19	69.8
3	Male	17	63.5
4	Male	49	64.8
5	Male	20	28
6	Female	44	55.6
7	Male	27	21
8	Male	20	27
9	Male	16	26
10	Male	21	27
11	Male	18	40
12	Male	20	67.5
13	Male	43	39.6
14	Male	27	18
15	Male	23	18
16	Male	20	76.9
17	Male	19	82.4
18	Male	18	90
19	Female	17	122.5
20	Male	16	82.5
21	Male	36	87.5
22	Male	28	85

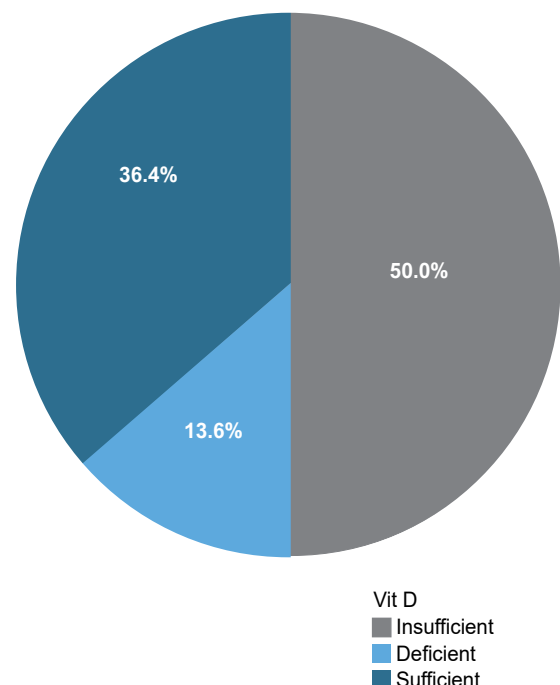


Figure 1. Prevalence of different vitamin D levels in the study cohort

patients (31.8%) had sufficient vitamin D levels (Figure 1). By categorising the patients above and below the median age of 20.5 years, we found age and vitamin D levels to be independent of age ($p = 0.80$). Patients with healed grafts had a higher average age ($p = 0.6$) compared to those without healing (Figure 2).

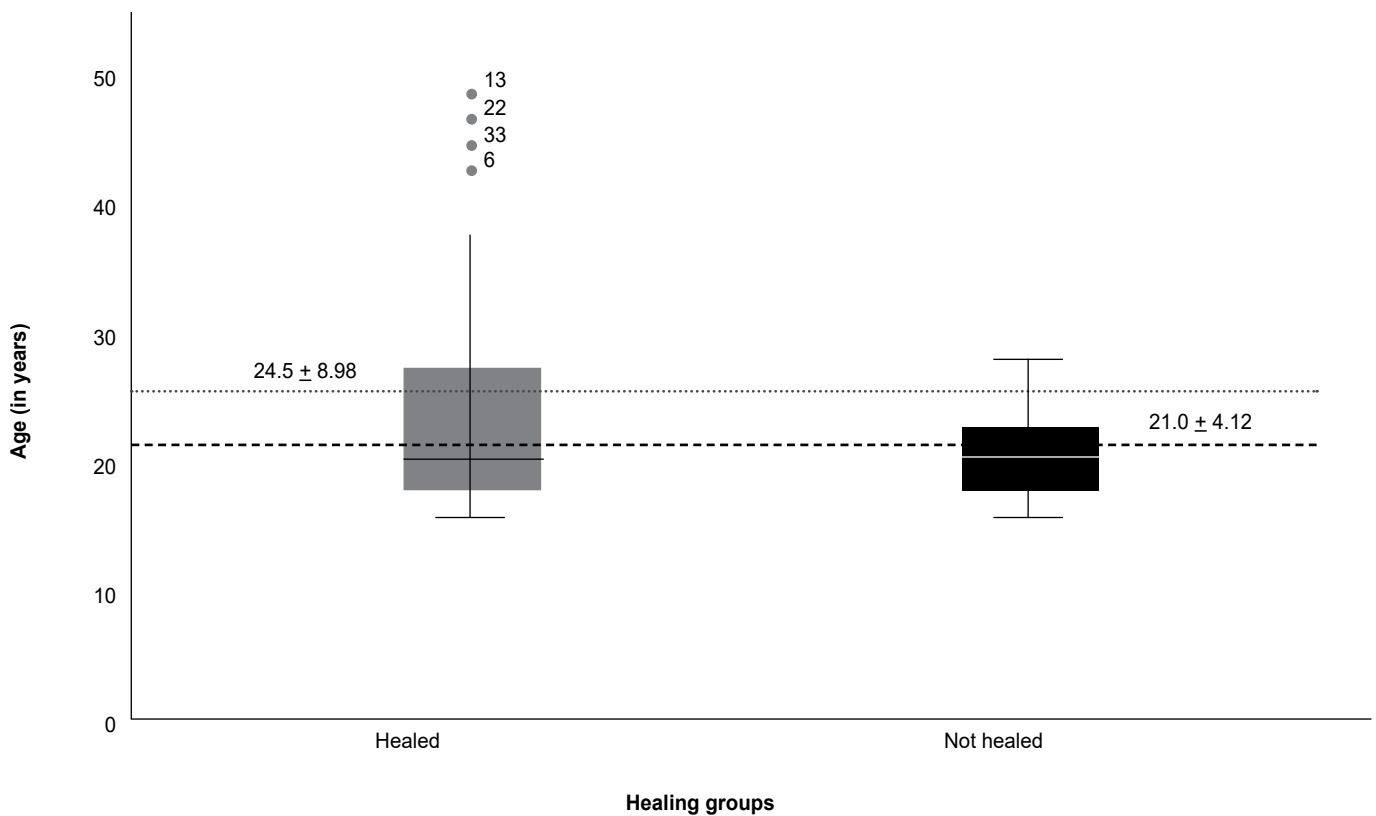


Figure 2. Distribution of age for the patients whose bone grafts healed postoperatively compared to the patients whose bone grafts were not found to be healed

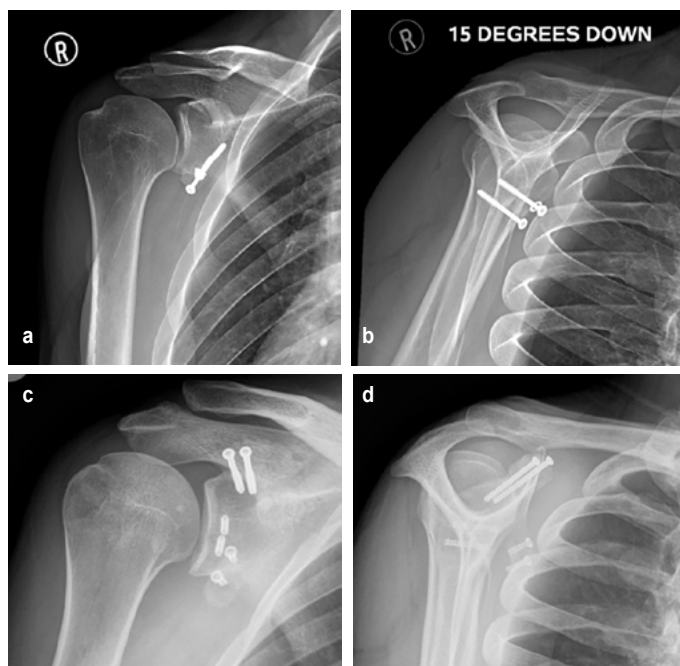


Figure 3. Postoperative X-rays of patients who underwent Latarjet procedure: a) showing bone-block resorption around the screw heads; b) showing bone-block nonunion represented by clear radiolucent line; and c) & d) AP and lateral view X-rays showing bone-block fracture with screw breakage

Inter-rater reliability between the observers was good as suggested by the ICC value of 0.86 (95% confidence interval: 0.67 to 0.94; $p < 0.0001$). One patient, 27 years of age, among the vitamin D-insufficient group showed signs of bone resorption. In the sufficient group, two patients, with ages 18 years and 28 years,

showed signs of graft resorption (Figure 3). Postoperative healing and vitamin D categories were found to be independent of each other ($p = 0.35$).

Discussion

The 22 patients believed to have a soft bone block at the time of their shoulder stabilisation procedure using a Latarjet procedure were selected for serum vitamin D testing. This retrospective study found a high prevalence of hypovitaminosis D in young adults undergoing Latarjet procedures. In this study, we found a high rate of bone graft healing in the vitamin D deficient and insufficient patients, which may be attributed to the vitamin D supplementation. A systematic review of vitamin D status among populations from 44 countries reported vitamin D insufficiency, with levels of < 75 nmol/L to be 88.1% of the samples presented. Hilger et al. reported that African and the Middle East children and adolescents had higher vitamin D levels compared to older adults.¹⁷ Vitamin D synthesis is reduced among people with dark skin pigmentation.^{18,19} There is a prevalence of vitamin D deficiency in 50% of African-American and Hispanic adolescents compared to 48% among white pre-adolescent girls in the reported literature.²⁰ Low dietary intake, poor sunlight exposure, obesity, and disorders of vitamin D metabolism remain common risk factors.¹⁸ Among orthopaedic patients, Stoker et al. reported a high prevalence of vitamin D deficiency in patients undergoing spinal fusion, with 57% of 313 patients having hypovitaminosis D. In their study, although the vitamin D-deficient patients were supplemented with oral vitamin D, the authors did not evaluate the rate of failed bone fusions.²¹

Vitamin D deficiency in South Africa has been reported to affect 41% of the general population. Among ethnic groups in the country, 28.6% of South African Indians had deficient vitamin D levels compared to 5% black Africans who had vitamin D deficiency.²² Prevalence in South African children is reported to be lower than the general population. Lisenda et al. reported a 16% vitamin D

deficiency in children with Blount's disease.²³ Similarly, Poopedi et al. reported 19% low vitamin D levels among urban South African children.²⁴ In our study, consisting of patients who have shoulder instability, it was observed that younger patients often have lower vitamin D levels, and we would recommend surgeons to be cognizant of this fact. The authors would also recommend measuring serum vitamin D levels in patients undergoing Latarjet procedure especially for those individuals whose bones appear to be softer than normal.

Laboratory rat studies have shown vitamin D, calcium and phosphorus deficiency impairs graft healing and is associated with higher infection rates.²⁵ A systematic review of 153 articles on the cellular effects of vitamin D in fractures has shown that vitamin D improves cellular production of growth factors like the platelet-derived growth factor (PDGF) and the vascular endothelial growth factor (VEGF) necessary for bone healing and bone remodelling. Vitamin D supplementation also showed improved callus formation during fracture healing, when compared to those who did not receive vitamin D.¹³ Vitamin D supplementation in postmenopausal females has shown to reduce fracture risk.^{19,20} Kwiatek et al. observed a correlation between peri-implant bone formation and serum vitamin D level in 122 healthy adults undergoing mandible implantation for missing molar teeth. Evaluation of bone loss or gain was evaluated using radiovisio-graphy on the day of implantation compared to findings at six weeks and 12 weeks.²⁶ The role of vitamin D in bone metabolism and bone healing cannot be ignored in clinical practice. We believe it possibly has an impact on bone-block union incorporation and the degree of resorption in patients undergoing anterior shoulder stabilisation. Bone-block shoulder stabilisation procedures have high complication rates which range between 15 and 30%.^{8,27} Willemot et al. reported a 42.3% nonunion rate and 26% graft resorption rate among 26 young patients who presented with failed Bristow or Latarjet procedures.²⁸ It would have been beneficial if these studies had reported on their patients' vitamin D levels. Supplementing our patients with vitamin D, postoperatively, might have been the reason for their rate of bone healing. Further research must be performed to investigate the effect of deficient and insufficient vitamin D levels on bone healing.

The retrospective nature of this study is a limitation because vitamin D levels were only available for those patients the surgeons subjectively felt to have softer coracoid at time of preparation. We acknowledge that intervention with vitamin D supplementation also prevents the ability to assess the effect of hypovitaminosis on graft healing and resorption. We could not ethically withhold treatment. Despite the limitations, we were able to shed light on the fact that younger patients undergoing Latarjet procedure suffer from low serum vitamin D levels. Further, attention should be paid to treating these patients with adequate supplementation to reduce postoperative coracoid complications, and we recommend routine testing for patients undergoing a bony procedure for instability in countries with a high prevalence of deficiency.

Our standard of care is to X-ray patients six weeks and three months post surgery to evaluate for bone-block union and osteolysis. Due to financial constraints and the potential for radiation exposure, we do not routinely assess these parameters using a CT scan. When compared to countries with more resources, this is a study limitation.²⁹ In our context, CT scans are used when there is a complication, and it is necessary to assess the bone block.

Conclusion

Vitamin D deficiency is common among young patients with anterior shoulder instability who undergo Latarjet surgery. Future studies should be focused on establishing the relationship between serum vitamin D levels and postoperative bone graft healing.

Ethics statement

The authors declare that this submission is in accordance with the principles laid down by the Responsible Research Publication Position Statements as developed at the 2nd World Conference on Research Integrity in Singapore, 2010.

Prior to commencement of the study, ethics approval was received from the University of Cape Town Faculty of Health Sciences Human Research Ethics Committee: HREC585/2019.

All procedures were in accordance with the ethical standards of the responsible committee on human experimentation (institutional and national) and with the Helsinki Declaration of 1975, as revised in 2008. Informed written consent was not obtained from all patients included in the study.

Declaration

The authors declare authorship of this article and that they have followed sound scientific research practice. This research is original and does not transgress plagiarism policies.

Author contributions

APR: study conceptualisation, data capture, first draft preparation

RD: data analysis, first draft preparation, manuscript revision

SdV: data capture, manuscript revision

KB: data capture, study design

MM: data capture, manuscript preparation

JPdP: study design, manuscript revision

SR: study conceptualisation, study design, manuscript revision

ORCID

Rachuene AP  <https://orcid.org/0000-0003-4045-5301>

Dey R  <https://orcid.org/0000-0002-3616-1995>

De Villiers S  <https://orcid.org/0000-0003-0023-5152>

Berry K  <https://orcid.org/0000-0001-8747-8995>

Du Plessis J-P  <https://orcid.org/0000-0001-6469-7765>

Roche S  <https://orcid.org/0000-0002-5695-2751>

References

1. Hasebroock AW, Brinkman J, Foster L, Bowens JP. Management of primary anterior shoulder dislocations : a narrative review. *Sport Med Open*. 2019;5(1):31. <https://doi.org/10.1186/s40798-019-0203-2%0A>.
2. Youm T, Takemoto R, Park BKH. Acute management of shoulder dislocations. *J Am Acad Orthop Surg*. 2014;22(12):761-71. <https://doi.org/10.5435/JAAOS-22-12-761>
3. Streubel PN, Krych AJ, Simone JP, et al. Anterior glenohumeral instability: A pathology-based surgical treatment strategy. *J Am Acad Orthop Surg*. 2014;22(5):283-94. <https://doi.org/10.5435/JAAOS-22-05-283>
4. Bah A, Lateur GM, Kouevidjin BT, et al. Chronic anterior shoulder instability with significant Hill-Sachs lesion: Arthroscopic Bankart with remplissage versus open Latarjet procedure. *Orthop Traumatol Surg Res*. 2018;104(1):17-22. <https://doi.org/10.1016/j.otsr.2017.11.009>
5. Gupta A, Delaney R, Petkin K, Lafosse L. Complications of the Latarjet procedure. *Curr Rev Musculoskelet Med*. 2015;8(1):59-66. <https://doi.org/10.1007/s12178-015-9258-y>
6. Bessiere C, Trojani C, Pélégri C, et al. Coracoid bone block versus arthroscopic Bankart repair: A comparative paired study with 5-year follow-up. *Orthop Traumatol Surg Res*. 2013;99(2):123-30. <https://doi.org/10.1016/j.otsr.2012.12.010>
7. Burkhart SS, De Beer JF. Traumatic glenohumeral bone defects and their relationship to failure of arthroscopic Bankart repairs: Significance of the inverted-pear glenoid and the humeral engaging Hill-Sachs lesion. *Arthroscopy*. 2000;16(7):677-94. <https://doi.org/10.1053/jars.2000.17715>
8. Du Plessis J-P, Lambrechts A, McGuire D, et al. Early and medium-term complications of the modified Latarjet procedure. *SA Orthop J*. 2014;13(3):50-56.
9. Hovelius L, Sandström B, Olofsson A, et al. The effect of capsular repair, bone block healing, and position on the results of the Bristow-Latarjet procedure (study III): Long-term follow-up in 319 shoulders. *J Shoulder Elb Surg*. 2012;21(5):647-60. <https://doi.org/10.1016/j.jse.2011.03.020>
10. Zhu YM, Jiang CY, Lu Y, et al. Coracoid bone graft resorption after Latarjet procedure is underestimated: A new classification system and a clinical review with computed tomography evaluation. *J Shoulder Elb Surg*. 2015;24(11):1782-88. <https://doi.org/10.1016/j.jse.2015.05.039>
11. Salovaara K, Tuppurainen M, Kärkkäinen M, et al. Effect of vitamin D3 and calcium on fracture risk in 65- to 71-year-old women: A population-based 3-year randomized, controlled trial - The OSTPRE-FPS. *J Bone Miner Res*. 2010;25(7):1487-95. <https://doi.org/10.1002/jbmr.48>
12. Gaston MS, Simpson AHRW. Inhibition of fracture healing. *J Bone Jt Surg - Ser B*. 2007;89(12):1553-60. <https://doi.org/10.1302/0301-620X.89B12.19671>
13. Gorter EA, Hamdy NAT, Appelman-Dijkstra NM, Schipper IB. The role of vitamin D in human fracture healing: A systematic review of the literature. *Bone*. 2014;64(2014):288-97. <https://doi.org/10.1016/j.bone.2014.04.026>

14. Oh JH, Kim SH, Kim JH, et al. The level of vitamin D in the serum correlates with fatty degeneration of the muscles of the rotator cuff. *J Bone Jt Surg - Ser B*. 2009;91(12):1587-93. <https://doi.org/10.1302/0301-620X.91B12.22481>
15. Hanley DA, Cranney A, Jones G, et al. Vitamin D in adult health and disease: A review and guideline statement from osteoporosis Canada. *CMAJ*. 2010;182(12):E610-8. <https://doi.org/10.1503/cmaj.080663>
16. Koo TK, Li MY. A guideline of selecting and reporting intraclass correlation coefficients for reliability research. *J Chiropr Med*. 2016;15(2):155-63. <https://doi.org/10.1016/j.jcm.2016.02.012>
17. Hilger J, Friedel A, Herr R, et al. A systematic review of vitamin D status in populations worldwide. *Br J Nutr*. 2014;111(1):23-45. <https://doi.org/10.1017/S0007114513001840>
18. Parva NR, Tadepalli S, Singh P, et al. Prevalence of vitamin D deficiency and associated risk factors in the US population (2011–2012). *Cureus*. 2018;10(6):e2741. <https://doi.org/10.7759/cureus.2741>
19. Rosen CJ, Abrams SA, Aloia JF, et al. IOM committee members respond to endocrine society vitamin D guideline. *J Clin Endocrinol Metab*. 2012;97(4):1146-52. <https://doi.org/10.1210/jc.2011-2218>
20. Holick MF, Binkley NC, Bischoff-Ferrari HA, et al. Evaluation, treatment, and prevention of vitamin D deficiency: An endocrine society clinical practice guideline. *J Clin Endocrinol Metab*. 2011;96(7):1911-30. <https://doi.org/10.1210/jc.2011-0385>
21. Stoker GE, Buchowski JM, Bridwell KH, et al. Preoperative vitamin D status of adults undergoing surgical spinal fusion. *Spine (Phila Pa 1976)*. 2013;38(6):507-15. <https://doi.org/10.1097/BRS.0b013e3182739ad1>
22. Du Plessis M. Vitamin D overview. *AMPATH CHAT*. 2017;(44):1-10. Available from: www.ampath.co.za. Accessed 23 November 2019.
23. Lisenda L, Simmons D, Firth GB, et al. Vitamin D status in blount disease. *J Paediatr Orthop*. 2016;36(5):e59-e62. <https://doi.org/10.1097/BPO.0000000000000607>
24. Poopedi MA, Norris SA, Pettifor JM. Factors influencing the vitamin D status of 10-year-old urban South African children. *Public Health Nutr*. 2010;14(2):334-39. <https://doi.org/10.1017/S136898001000234X>
25. Cantorna MT, Hullett DA, Redaelli C, et al. 1,25-Dihydroxyvitamin D3 prolongs graft survival without compromising host resistance to infection or bone mineral density. *Transplantation*. 1998;66(7):828-31. <https://doi.org/10.1097/00007890-199810150-00003>
26. Kwiatek J, Jaroń A, Trybek G. Impact of the 25-hydroxycholecalciferol concentration and vitamin d deficiency treatment on changes in the bone level at the implant site during the process of osseointegration: a prospective, randomized, controlled clinical trial. *J Clin Med*. 2021;10(3):526. <https://doi.org/10.3390/jcm10030526>
27. Gupta A, Thusbas C, Koch M, Seebauer L. Management of glenoid bone defects with reverse shoulder arthroplasty—surgical technique and clinical outcomes. *J Shoulder Elb Surg*. 2018;27(5):853-62. <https://doi.org/10.1016/j.jse.2017.10.004>
28. Willemot L, De Boey S, Van Tongel A, et al. Analysis of failures after the Bristow–Latarjet procedure for recurrent shoulder instability. *Int Orthop*. 2019;43:1899-1907. <https://doi.org/10.1007/s00264-018-4105-6>
29. Kordasiewicz B, Kicinski M, Małachowski K, et al. Comparative study of open and arthroscopic coracoid transfer for shoulder anterior instability (Latarjet)—computed tomography evaluation at a short term follow-up. Part II. *Int Orthop*. 2018;42(5):1119-28. <https://doi.org/10.1007/S00264-017-3739-0>

