

EXPERT OPINION ON PUBLISHED ARTICLES

Reviewer: Dr Jan de Vos

Private Practice, Wilgers Hospital, Pretoria

Tel: +27 (0) 82777 4058

jndevos@mweb.co.za

Comparison of intravenous versus topical tranexamic acid in total knee arthroplasty: A prospective randomized study

Jay N. Patel, Jonathan M. Spanyer, Langan S. Smith, Jiapeng Huang, Madhusudhan R. Yakkanti, Arthur L. Malkani
The Journal of Arthroplasty 2014;**29**(8):1528–31

The importance of blood conservation in orthopaedic surgery is beyond discussion. Blood transfusion adds cost to the procedure and risk to the patient. The risks include, but are not limited to, periprosthetic joint infection, allergic reaction and viral transmission.

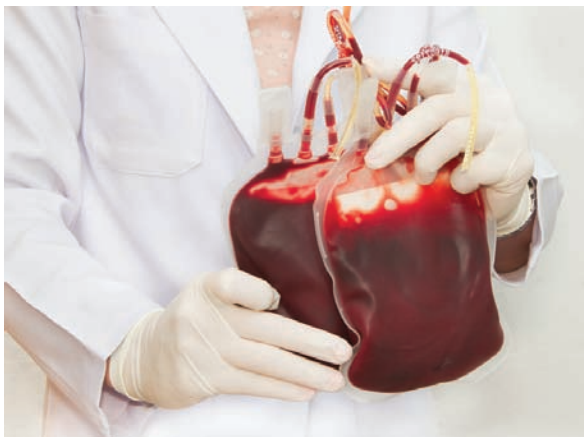An estimated 800–1 800 ml of blood is lost during and shortly after a total knee arthroplasty (TKA). Previous studies showed that 11–67% of TKA patients require a blood transfusion.

Tranexamic acid (TXA) stabilises blood clots by preventing fibrinolysis, thereby reducing bleeding. TXA is a synthetic derivative of the amino acid lysine. TXA competes with lysine to bind with the plasminogen molecule, preventing transformation of plasminogen to plasmin, which is necessary in the fibrinolysis cascade.

The antifibrinolytic agent TXA is very popular due to ease of administration, minimal impact on the flow of the surgical procedure and cost-effectiveness. But there is no consensus regarding dosage, timing, frequency and route for administration. The safety parameters for intravenous and intra-articular use have not been determined.

Although none of the studies have shown an increase in thromboembolic events, it still is a concern.

After intravenous administration TXA diffuses into the synovial membranes and fluid. Within a short time the concentration of the TXA in synovial fluid is the same as that of the serum. Its biological half-life in the joint is about 3 hours. It is eliminated via the kidney, with excretion being about 30% at 1 hour, 55% at 3 hours and 90% at 4 hours after an intravenous dose of 10 mg TXA/kg.



There seems to be a marked increase in local fibrinolysis after the release of the tourniquet. This led to the assumption that topical or intra-articular TXA should be able to inhibit local fibrinolysis more effectively than intravenous administration.

It is not advisable to use intravenous TXA in some pre-existing medical conditions, i.e. renal insufficiency, previous thromboembolic disease, cerebrovascular disease and cardiac disease. The question is rightly asked, whether the same applies to the topical use of TXA? Perhaps the contraindications are not so pertinent as Wong *et al.* found plasma levels of TXA after topical application about 70% less than an equivalent dose of IV administration.

In the study the authors compared the efficacy and safety of one intravenous administration (10 mg/kg) versus topical application (2.0 gm in 100 ml saline) of TXA. This is a therapeutic level 1 study in 89 patients. The patients were demographically matched. The study proved no inferiority regarding efficacy of topical versus intravenous administration of TXA.

The strengths of the study are:

- prospective randomised study
- blinded nature of the follow-up
- statistically adequately powered

The shortfalls or limitations of the study are:

- Haemoglobin levels and transfusion rates rather than functional outcomes were used as end-points.
- The follow-up period of 18.3 weeks is rather short, especially if outcomes were to be compared.
- The incidence of thromboembolic conditions in the study is probably lower than the true incidence, because only clinical suspicion was used as a trigger point for further investigation.
- Plasma levels of TXA were not evaluated and compared.
- The dosage of TXA used was not the same.

Message: There does not seem to be a downside to using TXA. The efficacy of intra-articular application and intravenous administration appears to be the same.

Reviewer: Dr PR Engelbrecht
 Orthopaedic Surgeon
 Wilgers Consulting Rooms
 Tel: 012 807 1298/9
 Fax: 012 807 2639

Surgical management of lumbar degenerative spondylolisthesis

Frank J. Eismont, Robert P. Norton, Brandon P. Hirsch
Journal of the American Academy of Orthopaedic Surgeons, April 2014;22(4):203–13

The authors emphasise that surgical management is to be considered in patients whose symptoms are debilitating and recalcitrant to non-surgical management. The most appropriate indications for surgery are radicular pain, neurogenic claudication as well as patients with a bowel or bladder dysfunction with progressive weakness.

Various surgical options are reviewed:

1. Decompression without fusion

The authors indicate satisfactory outcome in 69% of patients in a meta-analysis in 1994, and furthermore mention two further studies, in 2002 as well as 1998, with good to excellent outcomes in 82% and 73.5% of patients respectively. This might well be an option for an elderly patient with stable degenerative spondylolisthesis.

2. Decompression with non-instrumented fusion

A small series is mentioned: 50 patients in 1991 who underwent this procedure with autogenous iliac crest bone graft with follow-up for 3 years. Although pseudoarthrosis occurred in 36% of cases, this did not appear to affect the clinical outcome. A further study in 2007 confirmed the beneficial role of non-instrumented fusion in managing degenerative spondylolisthesis.

3. Decompression with instrumented postero-lateral fusion

The authors indicate that this should be considered as the standard of care in 2014. Data indicates improved fusion rates with the use of instrumentation. A prospective randomised study in 1997, comparing decompression laminectomy and arthrodesis, with and without spinal instrumentation, indicated that at 2-year follow-up, the instrumented group had significantly higher fusion rates, although there was no statistical significant difference in clinical outcome. A follow-up study of 47 patients however indicated significantly better outcomes if a solid fusion was obtained.

4. Degenerative spondylolisthesis and the SPORT perspective

A total of 303 patients were enrolled in this study in 2007. A high rate of crossover between patients assigned to surgery and patients assigned to non-surgical management complicated analysis of data.

However, authors were able to demonstrate substantially greater improvement in pain and function in the surgical group, at 2-year follow-up, which was maintained at 4-year follow-up.

A further subgroup analysis of 380 patients indicates that 80 patients had postero-lateral in situ fusion, 213 had postero-lateral instrumented fusion, 63 had 360° fusion and 23 had decompression alone without fusion. In this study in 2009, at 4-year follow-up, no consistent difference in clinical outcomes were found between these fusion methods. Also, the type of bone graft did not make a difference, including morcellised allograft.

5. Interbody fusion

Anterior lumbar interbody fusion, posterior lumbar interbody fusion and trans-foraminal lumbar interbody fusion are discussed under this heading. Posterior lumbar interbody fusion and trans-foraminal lumbar interbody fusion avoid the morbidity associated with an anterior approach, and less theatre time is needed.

The authors mention that the addition of interbody fusion should be considered in patients who are at risk of non-union, e.g. presence of local kyphosis, high grade slip, symptomatic instability with sagittally oriented facet joints, joint effusion on MRI and a tall intervertebral disc, emphasising load sharing in the setting of an insufficient anterior column.

6. Minimally invasive decompression

In this group, authors mention that increase in slippage was a problem and emphasise that decompression without concomitant fusion should be reserved for patients with a stable degenerative spondylolisthesis and primarily radicular symptoms. A learning curve is to be kept in mind with these kinds of procedures, although cost effectiveness is a consideration, i.e. a shorter stay in hospital.

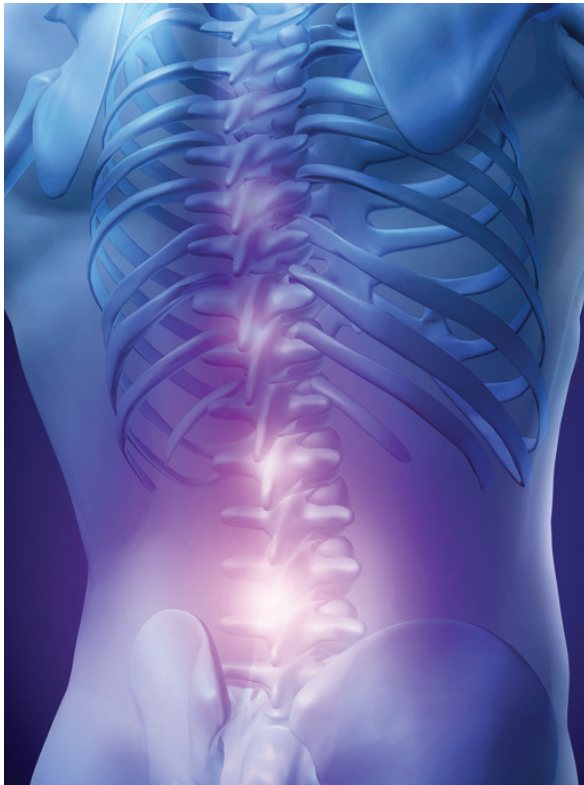7. Minimally invasive decompression and fusion

In a 2010 study, 85 patients were randomly assigned to minimally invasive trans-foraminal lumbar interbody fusion and open trans-foraminal lumbar interbody fusion. The minimally invasive group had greater X-ray exposure, but less blood loss, shorter hospital stay and less post-operative back pain. Patients were followed up for a minimum period of 5 years with an overall patient satisfaction rate of 80%. The authors conclude that minimally invasive trans-foraminal lumbar interbody fusion is a safe and effective surgical technique at 5-year follow-up.

8. Dynamic stabilisation

Twenty-six patients were evaluated in a study in 2008: at 4 years the authors concluded that dynamic stabilisation could maintain clinical improvement and radiologically stability. However, this procedure did not prevent the development of adjacent segment degeneration.

Surgical management is to be considered in patients whose symptoms are debilitating and recalcitrant to non-surgical management



9. Lumbar interspinous spacers

Clinical studies are not conclusive and long-term outcomes of these devices are not known.

10. Degenerative spondylolisthesis and the elderly

The authors note that satisfactory clinical and radiographic success with relatively low complication rates were reported in elderly patients treated with traditional decompression and instrumented posterior fusion. Age alone should not be a contra-indication to surgical intervention.

This article provides an overview of surgical options available to the treating surgeon. Laminectomy and posterior instrumented spinal fusion is the current standard of care and most commonly performed surgical procedure for degenerative spondylolisthesis. However, laminectomy alone, if the degenerative spondylolisthesis is stiff, should be kept in mind that the more technical the procedure becomes, the more of a learning curve there is. The authors quite correctly mention that, when deciding on appropriate treatment, the surgeon should always consider his or her familiarity with a specific technique, potential risks and benefits, consider the total expense of implants, surgical time, patient's length of stay in hospital and time away from work.

Reviewer: Dr MM Malan
MediClinic C5
Joubertstreet
Vereeniging
Tel: 016 422 2378

Cement arthroplasty for ankle joint destruction

Ho-Seong Lee, MD, Ji-Yong Ahn, MD, Jong-Seok Lee, MD, Jin-Young Lee, MD, PhD, Jae-Jing Jeong, MD, and Yoing Rak Choi, MD, PhD

Investigation performed at the Department Orthopaedic Surgery, Asan Medical Centre, University of Ulsan, College of Medicine, Seoul, South Korea

J Bone Joint Surg Am. 2014 Sep 3;96(17):1468-75

The South Korean authors reported on 16 cases where cement (with or without antibiotic loading) was used as a primary salvage procedure to treat ankle joint destruction. Cases included three tumours of the talus, six failed ankle arthrodeses, five failed total ankle replacements, talus fracture and infected Charcot joint. Nine cases had prior infection. Comorbidities included diabetics, rheumatoid arthritis, renal failure and multiple open fractures.

At operation devitalised infected and/or tumour tissue was removed until healthy bone was reached. Concave surfaces were created proximally and distally. Alignment and length was optimally maintained while the space was filled with cement. In six of the 16 patients screws were used to increase stability at the bone-cement junction.

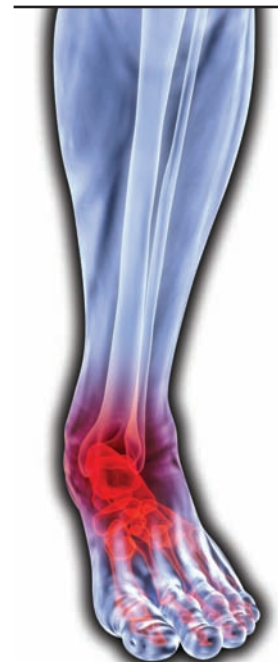
Post-operatively a short cast was used for 4 weeks after which full weight bearing was allowed.

In follow-up (14–100 months; mean 39 months) patients reported AOFAS score improvement from 39 (11–71) pre operation to 70(47–88) post operation.

At final follow-up nine of the 16 patients did not need walking aids, three used a walking cane and one a wheel chair. Nine patients could walk continuously and four participated in recreational activities. Comorbidities were the main factor in the less active patients. Only one patient had a failed cement arthroplasty.

The authors conclude that cement arthroplasty is a relatively easy option for ankle joint destruction in less active patients. The longevity in young patients is unknown at this stage.

This article highlights a valuable addition to possible procedures for a severely compromised ankle joint.



Reviewer: Dr ICM Robertson

Dept of Orthopaedics
Tygerberg Hospital
Private Bag X3
Tygerberg, Cape Town
Tel: 021 938 5458

Delayed debridement of severe open fractures is associated with a higher rate of infection

PD Hull, SC Johnson, DJG Stephen,
HJ Kreder, RJ Jenkinson
The Bone & Joint Journal 2014;96-B:379–84

The adage 'All open fractures need to be debrided within six hours' was taught to all of us, but how true is it? This is one of many recent studies^{1,2} that have examined and challenged this rule.

This study performed in the Health Sciences Centre Toronto, Canada was done on 459 open fractures seen at this level 1 trauma centre. The authors found that while lower grade open fractures showed little increase in deep sepsis when debridement was delayed, Gustilo and Anderson grades II and III showed a 3% linear increase in deep sepsis per hour of delay.

Despite the traditional teaching that all open fractures should be debrided within six hours, this time constraint has never been established (or quantified) by the orthopaedic literature. This study tries to address this deficit.

This retrospective study looks at all patients presenting between 2003 and 2007 with open fractures. Patients who died or had amputations were excluded, resulting in 403 patients with 459 open fractures.

The authors administered antibiotics on presentation and until 24 hours post-operatively. Cefuroxime was the standard antibiotic given. With severely contaminated wounds gentamycin and metronidazole and penicillin were added. Clindamycin was the alternative to penicillin in allergic individuals. Debridement was done as soon as possible, but delays over six hours were often encountered. The timing of wound closure as well as the method of fixation was at the discretion of the treating surgeon. Failure of treatment was defined as deep infection which resulted in an unplanned repeat operation for bone infection.

Results

The mean time to starting with antibiotics was 2.4 hours, and to performing the debridement was 10.6 hours.

Infection was seen in 10% of cases. No grade I fractures became septic, and as a result the authors excluded these from their analysis. Grade 2 fractures resulted in a 6.9% sepsis rate. This increased to 20% deep sepsis with grade IIIB and C fractures. High grade fractures (>IIIA) had twice the rate of becoming infected than low grade (<IIIA) fractures.

Tibial fractures had a much higher chance of becoming infected than any other site (odds ratio of 2.44 compared to other non-tibial sites).

When analysing their results the authors conclude that delay to surgery increases the risk of deep sepsis by 3% per hour.

Discussion

The 'six hour rule' (time to debridement) is more an adage than a proven fact. This study shows that higher-grade open tibial fractures (Gustilo and Anderson 3B and C) show a much increased risk of infection.

The authors claim that they can predict a **non-tibial** fracture would have a 2.4 per cent chance of infection, if debrided within four hours. This risk increases to 2.9% if surgery was to be delayed another six hours. In contrast, a **high grade open tibial fracture**, delayed for a similar period, would be predicted to experience a significantly higher infection rate. In this case, the predicted chance of the limb developing sepsis will increase from 35.6% to 43.4%! This is a higher figure than the actual 20% sepsis for high-grade fractures the authors experienced in their study, because the 'predicted probability' was derived by extrapolation using the more abundant data from the lower-grade open fractures. In this model only **severely contaminated** wounds were considered, but the debridement periods were similar.

Effect of delay is less significant than some other factors, such as which bone is affected. Some studies have failed to show that early vs. delayed debridement make any difference.¹

This study shows that that the tibia has a 2.5 times higher chance of developing deep sepsis after an open fracture compared to other bones. What are the hazards of late night surgery? The authors point out the well documented effect of surgeon exhaustion. Operating on an open tibia is not particularly demanding, but this may change if plastic surgical procedures need to be done. If these types of skills are required, low grade open fractures, with minimal infection risk, may well be deferred to daylight hours

The conclusion is that the tibia needs priority over other bones especially if it has suffered a high grade open fracture. Lower grade open fractures, especially if they need complex plastic surgical procedures may have delayed surgery with low risk of deep infection.

Reviewer's commentary

Any level 1 study on the question of the permissible time delay to debridement of open fractures will be unlikely to achieve ethical approval. The type of retrospective study done by Hull *et al.* is what the orthopaedic surgeon requires for practicing evidence based medicine. This study does highlight the vast differences in infection risk between the tibia and other open fractures, and the low risk type I and II pose regarding deep infection.

Although the last word regarding the six-hour rule has not been written, this study emphasises the need to prioritise high grade tibial fractures. Decision makers controlling emergency list allocation can safely delay lower grade open fractures, particularly if they are non tibial fractures. In contrast, high grade open fractures need to be given highest priority and pushed onto the emergency list above all other orthopaedic casualties.

References: 1. Schenker M, Yannicoli S, Baldwin K, Ahn J, Mehta S. Does timing of operative active debridement affect infectious complications in open long-bone fractures? A systematic review. *J Bone Joint Surg [Am]* 2012;94A:1057-64. 2. Pollak AN, Jones A, Castillo RC, Bosse MJ, MacKenzie EJ. The relationship between time to surgical debridement and incidence of infection after open high-energy lower extremity trauma. *The Journal of Bone & Joint Surgery* 2010;92:7-15.

Reviewer: Dr Beyers Oosthuizen
Suite 8C Unitas Hospital
Tel: 012 664 4600

Reproducible fixation with a tapered, fluted, modular, titanium stem in revision hip arthroplasty at 8–15 years follow-up

Jose A Rodriguez MD, Ajit J Deshmukh, Jonathan Robinson MD, Charles N Cornell, Vijay J Rasquinha MD, Amar S Ranawat and Chitranjan S Ranawat MD
J of Arthroplasty 2014 (Sept) 29, Suppl 2, pp.214-18

This retrospective study assesses the mid- and long-term results of titanium tapered, fluted, modular (TFMT) stems in revision hip surgery.

Seventy-one hips were followed up over an average of 10 years. Seventy-nine per cent of the femurs had Paprosky 3A or more bone loss. There were a total of eight re-operations: three for instability, two for periprosthetic fractures, one for acetabular loosening, one for infection and one for a stem fracture at the modular junction.

All of the stems showed distal osteo-integration, 68% showed proximal bony reconstitution, two stems subsided >5 mm and the average Harris Hip score improvement were 37 points with 73% of patients ambulating without a walking aid after surgery.

The need for revision hip arthroplasty is ever increasing and high mechanical failure rates with cylindrical, fully porous coated CoCr stems led surgeons to favour TFMT stems. This study is the longest average follow-up of these stems published to date.

High mechanical failure rates with cylindrical, fully porous coated CoCr stems led surgeons to favour TFMT stems

Some reasons for re-operations:

- 4.2% instability: This is comparable to other literature and all three hips had severe abductor deficiency. None of the unstable hips subsided.
- There were two intra-operative fractures which were treated with cabling and re-implantation with no problems afterwards.
- One implant fracture 3 years post-operatively: The fracture site was just proximal to the most proximal area of distal osteo-integration and below the modular junction. This was one of the 38% with radiolucent lines around the proximal body which implies no osteo-integration around the body. It also happened to be in the widest area of the stem.

Tips when using TFMT stems:

- Pre-op planning to determine the optimal site of bone fixation and estimate implant dimensions is pivotal
- Prophylactic cerclage cable around the most proximal circumferentially intact bone. If an ETO was done, this should be below the most distal ETO site. It serves to prevent fracture propagation and iatrogenic fractures during reaming and implant placement.
- C-arm guidance during reaming to assess endosteal contact, bypass of stress risers and anterior cortical perforation.
- Ream by hand and not with power
- You need at least 6 cm of stem distal to your prophylactic cerclage cable.
- Determine the 6 cm mark on the reamer and then increase in diameter. Don't go deeper as you need to ream a cone for the stem to seat in.
- Choose the thickest implant possible in high BMI patients and where proximal osteo-integration is unlikely.
- The study is limited by its retrospective, non-randomised and uncontrolled nature, but it still supports the use of TFMT stems with reliable distal fixation in patients with femoral bone loss.

Extensor apparatus of the lesser toes: Anatomy with clinical implications – topical review

Miquel Dalmau-Pastor, Betlem Fargues, Enric Alcolea, Nerea Martínez-Franco, Patricia Ruiz-Escobar, Jordi Vega, Pau Golanó, Jordi Vega
Foot & Ankle International 2014;35(10):597–969

Reviewer: JJ van Niekerk
PO Box 650819
Benmore 2010
Tel: 011 883 1719
Fax: 011 884 2349

This is going to become one of the seminal articles about the anatomy of the toes.

The authors, all from Spain and including the Late Prof Pau Golanó, have written a very extensive review of the anatomy of the lesser toes with regard to the muscles and tendons, to give an insight as to why certain toes are more prone to certain problems.

They draw attention to the fact that there have been very few well-researched reviews of this anatomy. Mostly the hand anatomy has been copied to the foot.

It is interesting that they do an extensive literature search and find that the best previous work on this subject was written by Sarrafian in 1969.

The article is richly illustrated and well and clearly written so that one can read it and understand what is going on and why certain structures are more important than others.

This is not an article that can be summarised as a quick abstract, as they carefully look at the anatomical structure and highlight previously inaccurate descriptions which have crept into the literature and into text books.

This is an article to be read by all registrars and should be re-read by all consultants who really want to understand foot and ankle anatomy and pathology.

Reviewer: Dr Allan van Zyl

PO Box 28772

Danhof

Bloemfontein

Tel: 051 448 3051

What's new in adult reconstructive knee surgery

Carl Deirmengian, MD; Jess H. Lonner, MD
J Bone Joint Surg Am. 2014 Jan 21;97(2):169-74

This is a summary of an excellent review article in which 24 prospective randomised studies in *B&J Journal*, *JBS*, and *J of Arthroplasty* from the previous year were selected.

Implant choice

Numerous studies, Breeman *et al.*, Nutton *et al.*, Pijls *et al.* have demonstrated no difference between mobile-bearing and fixed-bearing knee implants.

'Although mobile-bearing knees have several potential theoretical advantages, the randomised controlled trials continue to demonstrate no significant differences with regard to outcome, function or survivorship due to this technology'

Kim *et al.* compared oxidised zirconium femoral components with conventional components and found no difference in all measured outcomes and concluded that the oxidised zirconium femoral components provide no benefit and they question the additional expense of these components.

Jensen *et al.* looked at the use of trabecular metal tibial cones in revision knee replacements and concluded in their small study that these components demonstrated a trend towards improved implant stability.

Alignment

Recent debate has questioned the long standing belief that neutral mechanical alignment improves longevity of knee replacements. This is of special importance for the proponents of computer navigation.

Kim *et al.* showed navigation does not improve alignment or clinical outcome.

In contrast, Huang *et al.* saw improved neutral mechanical alignment with navigation.

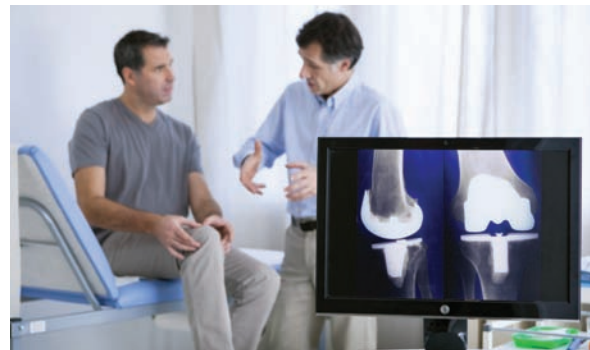Yim *et al.*, however, saw no difference between navigated vs non-navigated knees.

Patient specific cutting guides:

Chareancholvanich *et al.* saw no specific improvement with regard to limb or implant alignment when using this technology. There is also no significant difference in the numbers of outliers, raising considerable doubt regarding the clinical relevance of this technology.

Intra-operative products

No difference in sepsis rates between plain and antibiotic-loaded cement in a study of 2 948 patients, according to Hinarejos *et al.*



Jules-Elysee *et al.* demonstrated lower pain scores when intravenous hydrocortisone was given peri-operatively without increase of pain or wound healing. As only 17 patients in each arm of the study were presented the authors concluded that 'Caution should be taken until larger studies reveal that the infection rate does not rise in patients receiving perioperative hydrocortisone'.

Intra-operative techniques

Minimal invasive surgery (MIS) – the overwhelming majority of studies over the last decade have failed to show significant clinical advantage in these MIS techniques but did find increased rates of complications.

Peripatellar electrocautery – Baliga *et al.* have shown that this technique has no benefit.

Tourniquet use or not – Tai *et al.* showed significant less blood loss with tourniquet use.

The inflammatory markers, CRP and creatine phosphokinase were also higher in the non-tourniquet group demonstrating greater injury and inflammation without a tourniquet. Pain was higher, although not statistically significant when a tourniquet was used.

'Although some surgeons may feel strongly about the use or avoidance of tourniquets, it appears that these prospective randomised studies do not reveal an obvious recommendation'.

Pain control

Multimodal protocols that pre-empt pain and nausea that encourage early mobilisation have led to dramatic changes patients experience following knee replacements.

Periarticular infiltration of local anaesthetic has become the norm as part of pain control strategy. Chia *et al.*, studied the efficacy of additional corticosteroid infiltrations with the local anaesthetics. They saw no advantage in the group that had additional corticosteroid periarticular injections.