

## Recurrent primary fallopian tube carcinoma presenting with an appendiceal metastasis

**J S Möller, FCNP**

**J I Basson, MMed (Rad D)**

Free State PET/CT Centre, Bloemfontein

**J L Duminy, MMed (Rad Onc)**

Wilmed Park Oncology Centre, Bloemfontein

**E Potgieter, FC Path (Anat)**

PathCare Laboratories, Bloemfontein

**Corresponding author:** J Moller ([jakesmoller@hotmail.com](mailto:jakesmoller@hotmail.com))

A 61-year-old woman presented with a moderately differentiated serous papillary adenocarcinoma of the left fallopian tube in 2004. The tumour infiltrated the tube to the external surface. The uterus, cervix, right fallopian tube and ovaries were free of tumour, but peritoneal washings revealed the presence of metastatic tumour. The patient underwent chemotherapy but relapsed in 2009. The OV125 tumour marker at this stage was 2 685 U/ml (normal range: 0 - 35), which decreased to 9.6 U/ml following chemotherapy, and had increased again to 57.4 U/ml. A F-18 FDG PET/CT scan was requested for restaging, and demonstrated a retro-caecal appendix with a FDG-avid nodule in its tip, measuring 13 mm in the long axis (Fig. 1; see next page). At the time, the differential diagnosis was carcinoid tumour, primary carcinoma and a metastatic lesion (from the known primary tubal carcinoma). No further macroscopic tumour sites could be imaged. Histopathological analysis of the appendix revealed a metastatic serous papillary adenocarcinoma infiltrating through to the serosal surface (Fig. 2).

### Discussion

Primary fallopian tube carcinoma is a rare tumour, comprising less than 2% of female genital tract malignancies.<sup>1</sup> The incidence peaks between the fourth and sixth decades of life, with a median age of 55. Its presenting symptoms may be non-specific, and it is therefore not often diagnosed pre-operatively.<sup>2</sup> Clinical features include vaginal bleeding, abdominal pain, a pelvic mass and ascites. Imaging (most commonly ultrasound) may demonstrate a tubal mass. The diagnosis is usually made by histopathological examination. Tubal carcinoma spreads in much the same way as ovarian carcinoma, primarily by exfoliation of malignant cells that implant throughout the peritoneal cavity.<sup>3</sup> The initial staging of tubal carcinoma is based on the surgical findings at laparotomy. Treatment is similar to that of ovarian carcinoma, with surgery being the primary therapy aiming at tumour debulking and cytoreduction. Adjuvant chemotherapy is recommended for all but the earliest tumours, owing to the high propensity for microscopic distant metastases with subsequent recurrence.

Literature on the utility of PET/CT in tubal carcinoma is understandably sparse and limited to case reports, where it was able to localise the site of tumour recurrence.<sup>4,5</sup> However, PET/CT is expected to be of value, especially in the context of a rising tumour marker and negative conventional imaging, considering the clinical and pathological similarities between it and ovarian carcinoma, where the role of PET/CT is more clearly defined.<sup>6</sup>

1. Ng P, Lawton F. Fallopian tube carcinoma – A review. *Ann Acad Med Singapore* 1998;27:693-697.
2. Pectasides D, Pectasides E, Economopoulos T. Fallopian tube carcinoma: A review. *Oncologist* 2006;11:902-912.
3. Riska A, Leminen A. Updating on primary fallopian tube carcinoma. *Acta Obstet Gynecol Scand* 2007;86:1419-1426.
4. Takanami K, Kaneta T, Yamada S, et al. F-18 FDG PET/CT findings of primary carcinoma of the fallopian tube. *Clin Nucl Med*;34:378.
5. Patel PV, Cohae C, Chin BB. PET-CT localizes previously undetected metastatic lesion in recurrent fallopian tube carcinoma. *Gynecol Oncol* 2002;87:323-326.
6. Prakash P, Cronin CG, Blake MA. Role of PET/CT in ovarian cancer. *Am J Roentgenol* 2010;194:464-470.

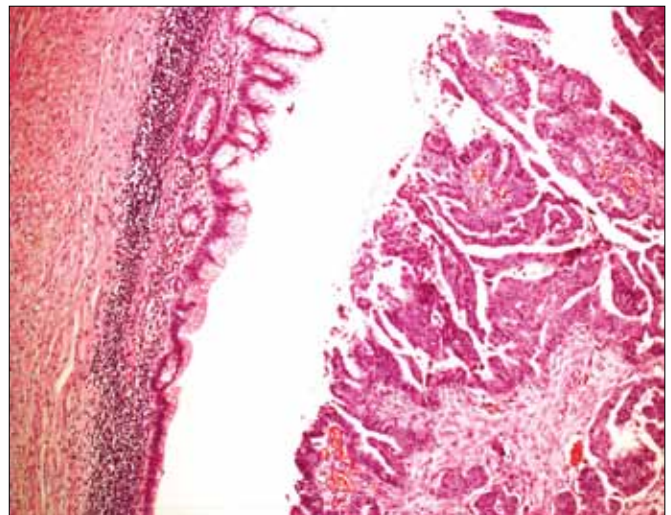


Fig. 2. Metastatic papillary serous adenocarcinoma in the appendix.

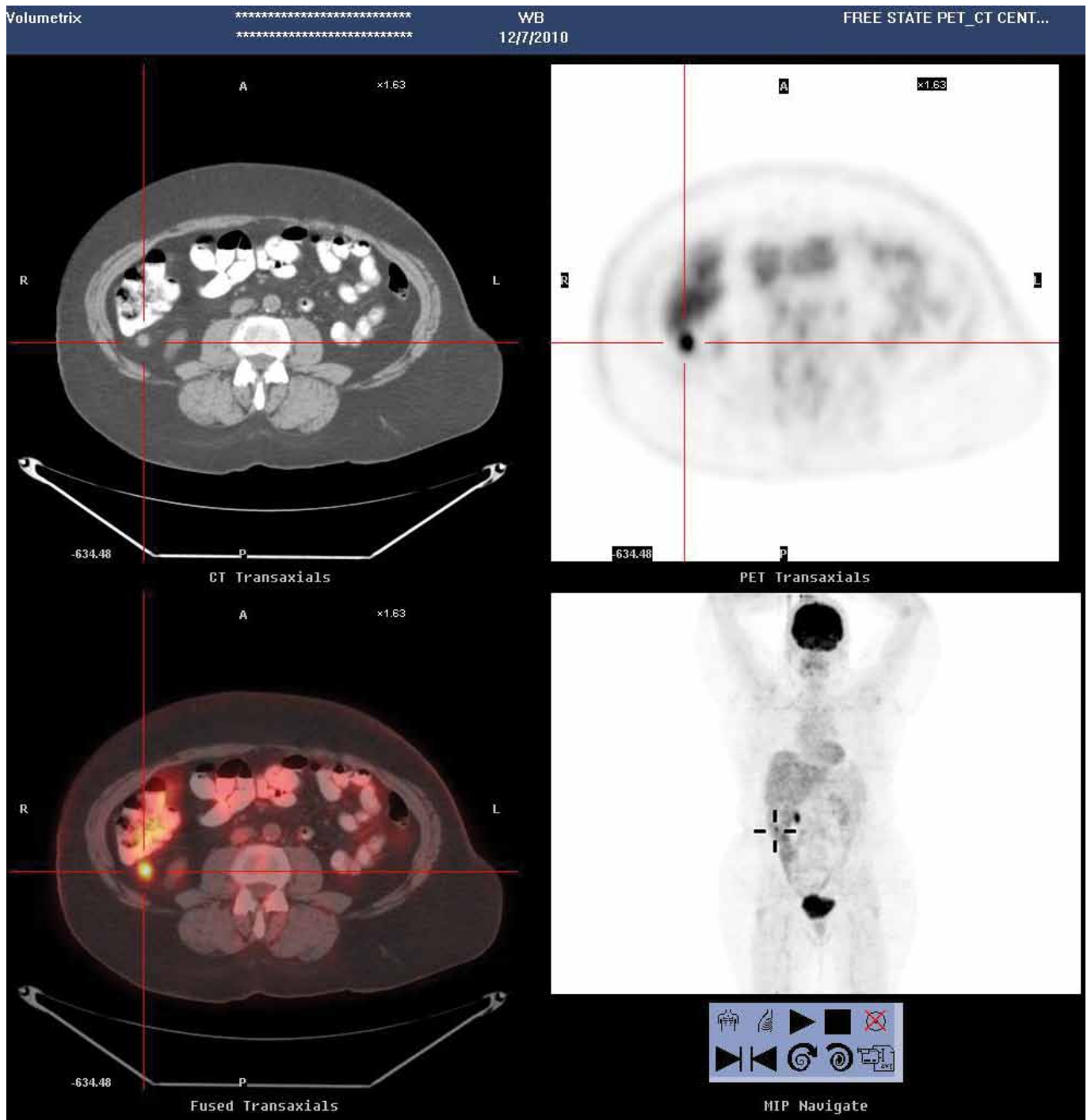


Fig. 1. Transaxial CT, PET and fusion images with the FDG-avid nodule in the tip of the appendix.