

# Is the skull x-ray a useful tool in paediatric blunt head injury and are we familiar with an abnormal finding?

**S Andronikou**

MBChB, FCRadDiag (SA), FRCR (London)

**C Welman**

MBChB

**E Kader**

MBChB

**J Venter**

MBChB

**T Kilborn**

MBChB

Department of Paediatric Radiology,  
University of Cape Town and Institute of Child Health,  
Red Cross War Memorial Children's Hospital,  
Rondebosch, Cape Town

Corresponding author

S Andronikou

Department of Paediatric Radiology, Red Cross War  
Memorial Children's Hospital, Cape Town, 7700  
Tel: (021) 658-5422. Fax: (021) 658-5101.  
E-mail: docsav@mweb.co.za

## Abstract

Skull X-ray (SXR) has been, and still is, used in some institutions to detect skull fractures in paediatric head injuries. When no clinical/neurological indication for computed tomography (CT) scanning exists, the presence of a skull fracture may be used as an indication for this. This case report demonstrates an unusual SXR finding of oval lucencies in a neurologically normal child who had sustained a head injury. The subsequent CT scan demonstrated a subacute subdural haemorrhage with air pockets, highlighting the need to recognise

intracranial air. The literature is reviewed regarding the usefulness of SXR in childhood head injury.

## Key words

Computerised tomography, skull fracture, subdural haemorrhage, pneumocranium

## Introduction

Some institutions have previously used and continue to use a skull X-ray (SXR) in the protocol for investigation of blunt head injury.<sup>1</sup> Computerised tomography (CT) is recommended as the imaging modality of choice for investigating blunt head trauma and, when normal in a patient with an isolated head injury, allows the clinician to discharge the patient.<sup>1-4</sup> It is in mildly injured patients where there are no positive neurological findings or a Glasgow coma scale (GCS) between 13 and 15 that controversy exists on whether a CT scan is routinely indicated.<sup>1,2,4,5</sup>

In an environment where costs and the availability of CT scanning are primary considerations, there is a difficult choice between –

1. discharging patients based on negative clinical/neurological findings and running the potential risks of missing an intracranial abnormality;
2. admitting patients for observation without CT scanning, which has been shown by certain authors to be more expensive than the following option 3;
3. subjecting all patients to routine CT scanning.

The place of skull radiography is considered controversial,<sup>1</sup> but detecting a skull fracture is considered an indication for CT scanning in institutions

# Is the skull x-ray a useful tool in paediatric blunt head injury and are we familiar with an abnormal finding?

from page 45

where SXR is still performed. Recognising the skull fracture per se has little clinical benefit, as it has little to do with management or outcome.<sup>3</sup> It is also well known that in children severe intracranial injury can occur in the absence of skull fractures.<sup>1</sup>

A study from Alder Hey in Liverpool states that SXR is not a reliable predictor of intracranial injury and is indicated only –

- in penetrating head injury;
- when non-accidental injury (NAI) is suspected, especially in children less than two years of age;
- to confirm/exclude suspected depressed skull fracture.<sup>1</sup>

The sensitivity for predicting intracranial injury based on neurological abnormalities was 91%, while the sensitivity of SXR for predicting intracranial injury was 65%.<sup>1</sup>

Other authors have calculated that in a fully conscious child with a skull fracture, the risk of intracranial haematoma was 80 times higher than in a child without a fracture.<sup>6</sup> These are two typical conflicting views on the value of SXR. Lloyd *et al* noted that significant injury was not seen in the absence of neurological signs and symptoms, but brain injury is commonly seen in the absence of a skull fracture.<sup>1</sup> The number of skull fractures detected was also very low at 2.7%. Another feature to note is that intracranial haematomas sustained from mild head injuries are associated with neither an abnormal skull X-ray nor ab-

normal neurological findings in up to 16-20% of cases.<sup>5</sup> As yet unpublished data from our institution showed that no drainable collection found on CT over a five-year period in patients with mild head injury was present without an associated skull fracture.

## Case report

We present a case of a four-year-old boy who presented five days after having sustained a blunt head injury from falling off a bed. There was no history of loss of consciousness, but the patient had complained of headaches for the past week and had vomited twice. The Glasgow coma scale was 15/15 and no neurological abnormalities were detected on clinical examination. A CT scan was not indicated according to the existing protocol, but a skull X-ray was performed and called normal, resulting in the patient being discharged.

When the radiologist reviewed the films the following day, he noted numerous lucencies on the lateral skull film (Figure 1), which were puzzling,

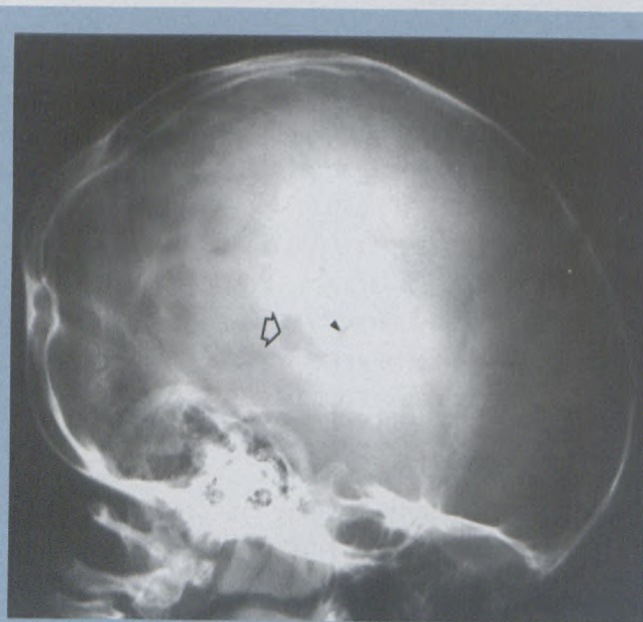


Figure 1: Numerous oval lucencies are seen over the temporal and parietal bones on lateral SXR (open arrow) and a faint linear fracture that was missed initially is visible on careful inspection (closed arrow)

and recalled the patient for a CT scan. The CT scan demonstrated a large right subdural haemorrhage containing air pockets and low densities in keeping with clot evolution (Figures 2 and 3). Review of the skull X-ray showed a fine vertical fracture line traversing the lucencies.

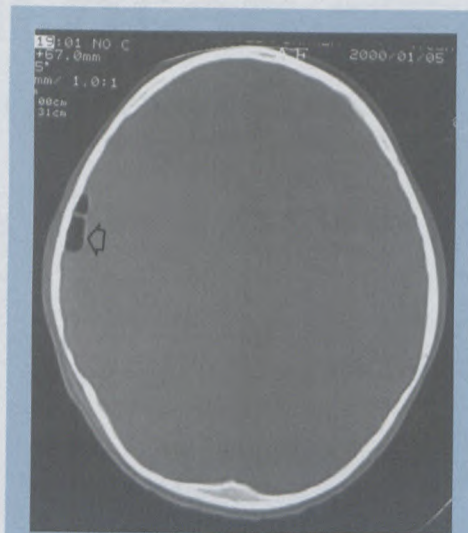


Figure 2: Axial CT of the brain on bone window setting clearly demonstrates the air pockets (open arrow), explaining the oval lucencies seen on plain film underlying the right parietal bone

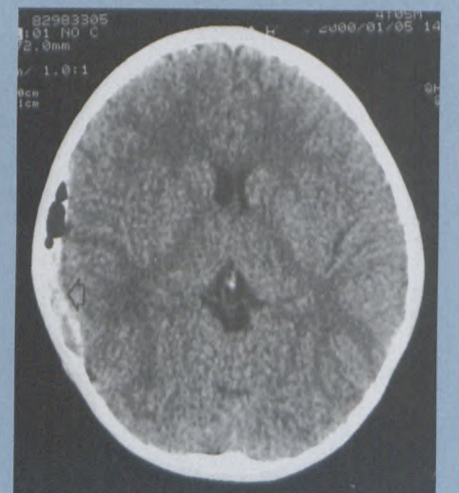
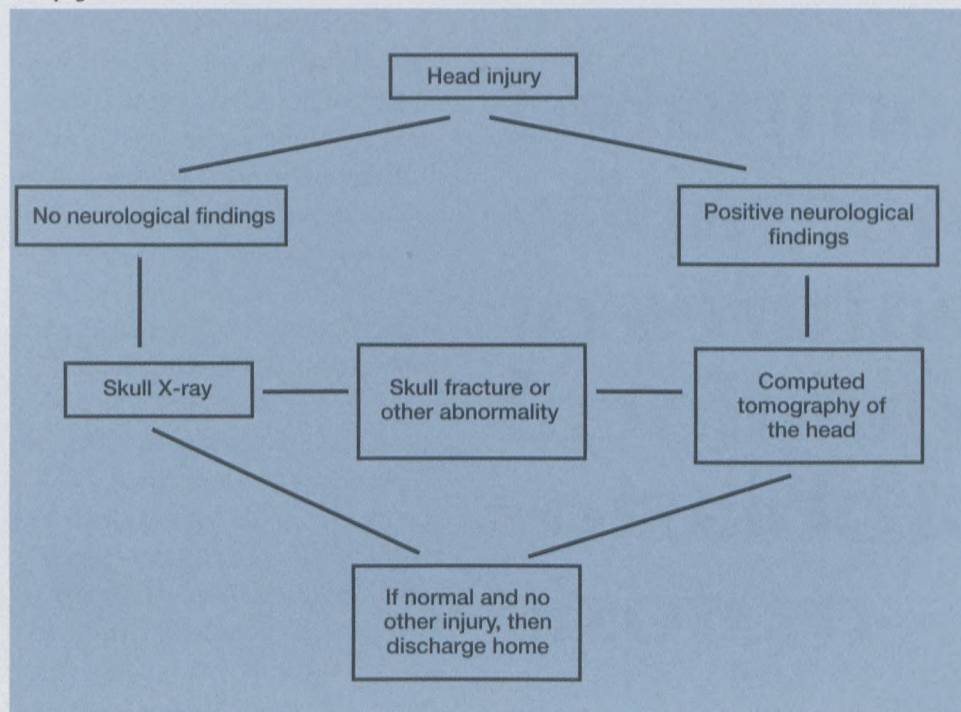


Figure 3: Axial CT of the brain on soft tissue/“brain” window setting demonstrates a significant right-sided subacute subdural haemorrhage (open arrow) that has undergone evolution and the air pockets at the non-dependent portion of the surface collection

# Is the skull x-ray a useful tool in paediatric blunt head injury and are we familiar with an abnormal finding?

from page 46



Current imaging protocol for paediatric blunt head injury used at the Red Cross Children's Hospital

## Conclusion

This case highlights numerous issues:

1. A child may present with a normal Glasgow coma scale and no neurological findings, but still have a significant intracranial bleed that needs surgical intervention.
2. If skull X-rays are to be performed, then we should be aware of features other than skull fractures, such as pockets of air, that are also an indication for CT scanning.

3. Assessment of an SXR by non-radiological staff is a drawback of performing routine SXR, as fractures and more confusing findings may be missed.

4. Institutions without direct CT access may need to evaluate patients clinically and possibly using skull X-rays alone as predictors of intracranial haemorrhage. In such institutions it should be remembered that the neurological findings have a better predictive value than skull X-rays, but if skull X-rays are to be used, then any

abnormality should urge the clinician to request a CT scan from a tertiary institution.

## Acknowledgements

We would like to thank the Red Cross Children's Hospital radiographers Dawn Skippers, Jessica Bertelsman, Sylvia Paverd and Nasrin Lahri for their contribution toward this paper.

## References

1. Lloyd DA, Carty H, Patterson M, Butcher CK, Roe D. Predictive value of skull radiography for intracranial injury in children with blunt head injury. *Lancet* 1997; **349**: 821-824.
2. Davis RL, Mullen N, Makela M, Taylor JA, Cohen W, Rivara FP. Cranial computed tomography scans in children after minimal head injury with loss of consciousness. *Ann Emerg Med* 1994; **24**: 640-645.
3. Davis RL, Hughes M, Gubler KD, Waller PL, Rivara FP. The use of cranial CT scans in triage of paediatric patients with mild head injury. *Paediatrics* 1995; **95** (3): 345-349.
4. Baker SR, Gaylord GM, Lantos G, Tabaddor K, Gallagher EJ. Emergency skull radiography: The effect of restrictive criteria on skull radiography and CT use. *Radiology* 1985; **156**: 409-413.
5. Stein SC, O'Malley KF, Ross SE. Is routine computer tomography scanning too expensive for mild head injury? *Ann Emerg Med* 1991; **20**: 1286-1289.
6. Teasdale G M, Murray G, Anderson E *et al*. Risks of acute traumatic intracranial haematoma in children and adults: Implications for managing head injuries. *BMJ* 1990; **300**: 363-67.