

Proptosis as a manifestation of neuroblastoma

S T Hlongwane, MB ChB
 M Pienaar, BSc, MB ChB
 G Dekker, MB ChB, MFamMed
 A Brandt, MB ChB
 D van der Merwe, MB ChB
 H B Louw, MB ChB, MFamMed
 S Dajee, MB ChB, DA, MMed Rad (D)

Department of Radiology, Tygerberg Hospital and Stellenbosch University

Abstract

Neuroblastoma occurs mainly in childhood and approximately 20% of cases have orbital metastases. Proptosis can be the only manifestation of metastatic neuroblastoma. Early investigation is important, as metastatic disease requires aggressive management. We present a case of a 7-year-old girl initially presenting with proptosis.

Introduction

Neuroblastoma is an uncommon tumour of early childhood which can metastasise to the orbits. Neuroblastoma accounts for 7.5% of all cancers in children less than 15 years of age, with 90% of all neuroblastomas occurring before the age of 10 years.¹ Approximately 1% of patients present initially with evidence of metastatic disease without a readily identifiable primary lesion. Neuroblastoma commonly metastasizes to bone (60%), regional lymph nodes (45%), orbit (20%), liver (15%), intracranially (14%), and lung (10%).²

There is little published work detailing the orbital and ophthalmic manifestations of neuroblastoma. This case report addresses the features of a 7-year-old girl presenting initially with proptosis.

Case report

A 7-year-old girl presented to the ophthalmology department with a 3-week history of progressive, painless left-sided proptosis. There was no history of visual disturbance. The mother also reported that the patient had difficulty walking due to discomfort in her right hip. There was also no history of recent illness, allergies or trauma.

Examination of the eyes showed a left axial, non-pulsatile proptosis with full range of movements. Abdominal examination did not show any abnormality. She had a tachycardia of with a pulse rate of 115 beats per minute. Haematological results revealed a haemoglobin of 8.6 g/dl, with a normocytic normochromic anaemia. The brain CT and MRI scans demonstrated enhancing mass lesions in the left sphenoid wing and lateral orbital wall, with an associated hyperostosis (Figs 1 – 2).

There was also opacification of the right maxillary and ethmoid sinuses. Biopsy of a cervical lymph node confirmed the diagnosis of neuroblastoma. The patient was referred to the oncology department for chemotherapy and to the psychologist for support and counselling as her prognosis was assessed to be very poor.

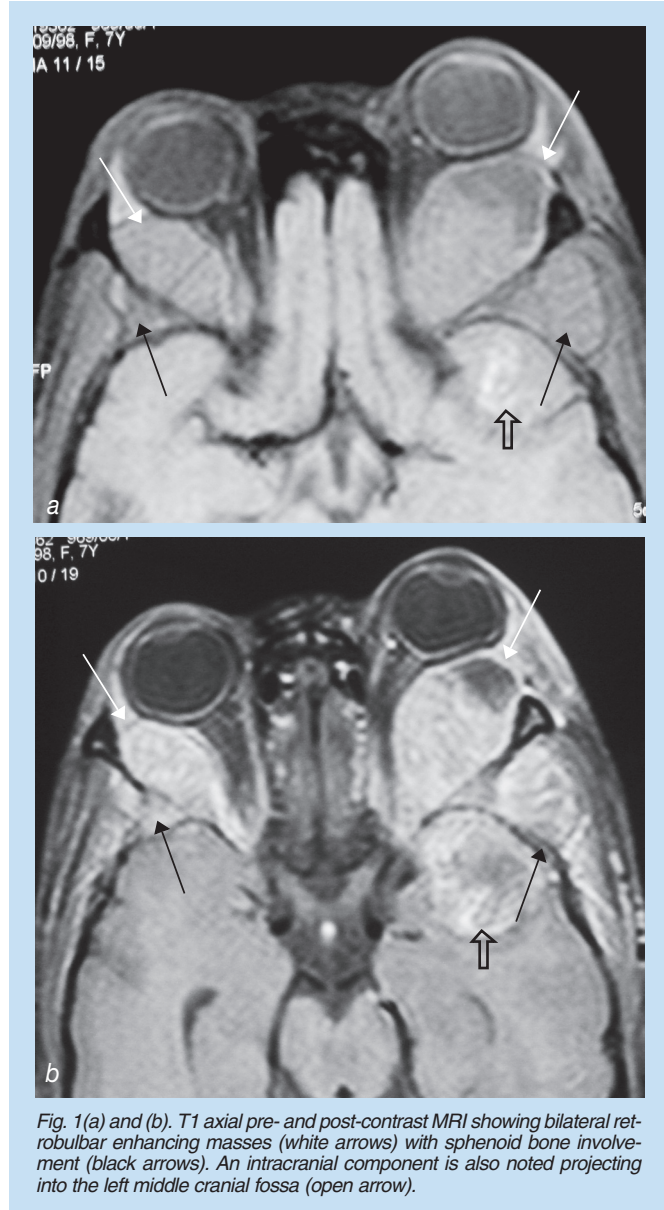

Fig. 1(a) and (b). T1 axial pre- and post-contrast MRI showing bilateral retrobulbar enhancing masses (white arrows) with sphenoid bone involvement (black arrows). An intracranial component is also noted projecting into the left middle cranial fossa (open arrow).

Discussion

Neuroblastoma occurs mainly in childhood and approximately 20% of cases have orbital metastases.¹ The primary tumour can arise from anywhere along the sympathetic chain, but the adrenal medulla is a common site (35%). Usually one adrenal gland is involved; bilateral involvement is rare.²

Symptoms may be due to tumour mass or bone pain from metastases. Proptosis and periorbital ecchymosis (raccoon eyes) which can mimic child abuse, are common signs and arise from retrobulbar metastases. Subconjunctival haemorrhages may occur as a consequence of pancytopenia resulting from bone marrow metastases.¹ In a study of 57 cases of childhood proptosis, metastatic neuroblastoma was the cause in

CASE REPORT

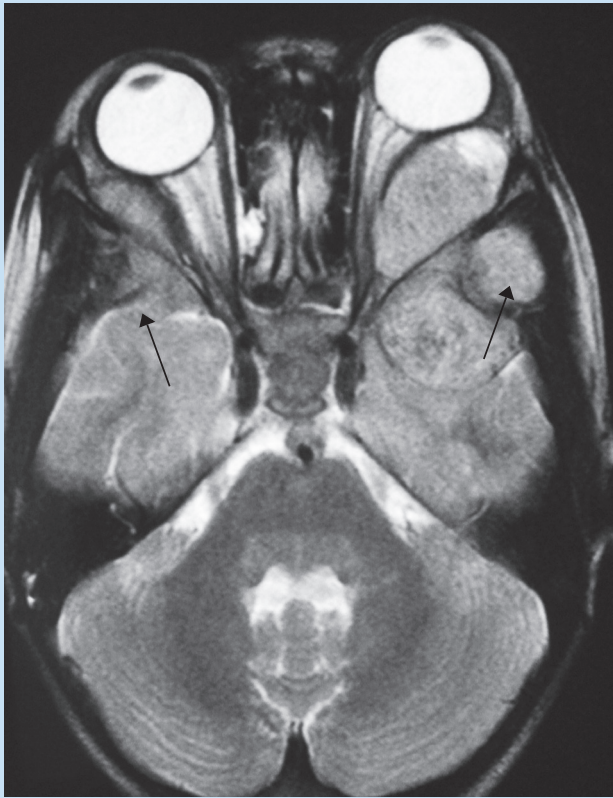

Fig. 2. T2 axial MRI image showing retrobulbar metastases originating in the sphenoid bone.

4 of the cases. The most common cause was orbital cellulitis, followed by thyroid eye disease and optic nerve/chiasm glioma.³


Ophthalmic involvement by neuroblastoma is defined by the International Neuroblastoma Staging System (INSS)² as stage 4 disease. Treatment of the primary disease is based on the Children's Oncology Group Neuroblastoma Risk Group Assignment Schema of low, intermediate, or high. Orbital involvement belongs in the high-risk category; therefore treatment involves very high doses of aggressive multiagent chemotherapy.

Conclusion

Proptosis in children can be the only manifestation of metastatic neuroblastoma. Early investigation is important, as metastatic disease requires aggressive management.

1. Ahmed S, Goel S, Khandwala M, Agrawal A, Chang B, Simmons IG. Neuroblastoma with orbital metastasis: ophthalmic presentation and role of ophthalmologists. *Eye* 2006; **20**: 466-470.
2. West S, Correa JD, Germain M, Balsam D, Rosen J. *Neuroblastoma* 2005; emedicine.com/radio/topic472.htm
3. Sindhu K, Downie J, Ghabrial R, Martin F. Aetiology of childhood proptosis. *J Paediatric Child Health* 1998; **34**: 374-376.

Imaging of Cancer, An Issue of Radiologic Clinics



By **David M. Panicek, MD,**
FACR

To Enquire Contact:
Health & Medical
Publishing Group
Private Bag X1,
Pinelands, 7430
Tel: 021 – 6578200
Fax: 021- 6834509
e-mail:
carmena@hmpg.co.za
[/ brents@hmpg.co.za](mailto:brents@hmpg.co.za)

ISBN 1416039023 · Hardback · 240 Pages
Saunders · Forthcoming Title (January 2007)