

A truly duplex renal system

C Sanyika

L Marishane

*Department of Radiology
University of Natal*

The angiogram of a 34-year old male prospective living renal donor in Figure 1 demonstrates two right renal arteries. A delayed digital abdominal radiograph (Figure 2) demonstrated a complete right duplex renal collecting system.

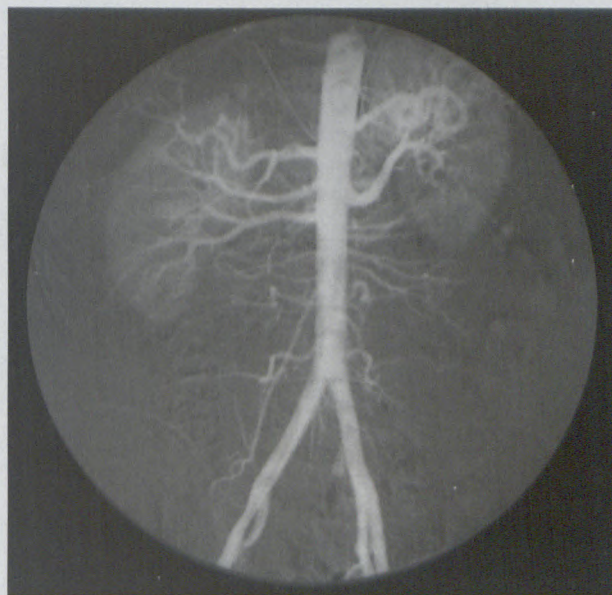


Figure 1

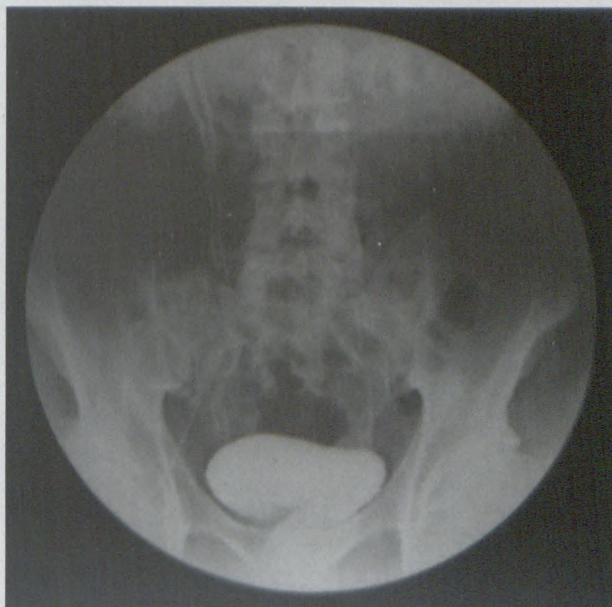


Figure 2