

Comparison of sonourethrography and retrograde urethrography in the evaluation of anterior urethral strictures

N Khan

MB BS, FCRAD (SA)

H M Modishi

MB ChB

L D R Tsatsi

MB ChB, FCRaD (SA)

*Department of Diagnostic Radiology
Medical University of Southern Africa*

A Kahloon

FRCS (Glasgow), FCS (Urol) SA

A Segone

FCS (Urol) SA, MMed (Urology)

*Department of Urology
Medical University of Southern Africa*

Abstract

Radiographic retrograde urethrography (RUG) has traditionally been the preferred technique used by urologists to image the anterior urethra. Since originally described by McAninch *et al.* in 1988, ultrasonic imaging of the urethra has evolved into a powerful and clinically useful tool for the accurate delineation of urethral pathology. However the posterior urethra cannot be assessed reliably using this technique. Sono-

urethrography has proved to be more accurate than conventional radiographic urethrography in measuring stricture length throughout the anterior urethra. The objective and purpose of this study was to assess the efficacy of sonourethrography in the evaluation of anterior urethral strictures and also to explain its many advantages over traditional imaging technique.

Introduction

Ultrasound imaging of the urethra has evolved into a powerful and clinically useful imaging tool in accurate delineation of anterior urethral pathology. It has proved to be more accurate than conventional technique in measuring the length of the stricture involving the anterior urethra. Radiographic retrograde urethrography (RUG) is a static two-dimensional study. Its ability to define stricture length precisely is limited, and also variation in patient position and traction on the penis during injection of the contrast medium can greatly alter the radiographic appearance of the

stricture. RUG has an added disadvantage, viz. unnecessary radiation exposure to the testes. Sonourethrography (SUG) is a procedure for assessment of the urethral abnormality, specifically strictures of the anterior urethra. It is an accurate predictor of stricture length, while RUG underestimates the stricture length. It can provide valuable information on the luminal and extraluminal anatomy of the anterior urethra and at the same time it gives a three-dimensional assessment of the length of the urethral stricture. We report on our experience of SUG of the anterior urethral strictures; its appearance is demonstrated and ultrasonic studies are compared with standard RUG.

Patients and methods

We studied 22 randomly selected patients between the ages of 19 and 61 years who were being evaluated for signs and symptoms of stricture disease. Once an abnormality was visible on RUG the patient immediately underwent SUG for comparison. The radiographic findings were not disclosed to the sonographer until completion of the study.

For SUG a 12F Foley's catheter was introduced into the distal urethra and its position was secured by distending the balloon with 2 ml of saline in the fossa navicularis. A standard dose of 20 - 30 ml of saline was infused into the urethra for adequate distension. All sonographic studies were performed with the Aloka SSD 5000 (Tokyo, Japan) using a 7.5 MHz linear array transducer. After liberal application of ultrasonic gel on the ventral surface of the penis the patient was scanned in a supine position.

Longitudinal and transverse images were obtained (Fig. 1).

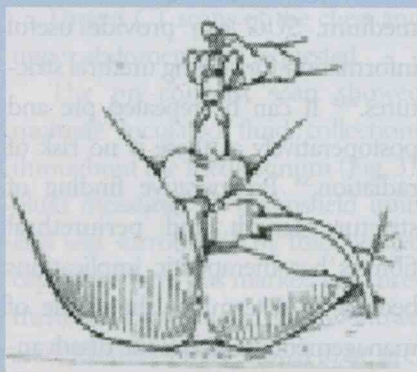


Fig. 1. Sonourethrography — the entire proximal bulbar urethra can be imaged with this technique using a ventral approach, starting distally at the penile urethra.

Subsequently transperineal and trans-scrotal scans were performed to image the proximal penile and bulbar urethra. Scanning was continued to include the proximal bulbar urethra and the region of the external sphincter.

The stricture was located, stricture length was determined using electronic caliper measurements, and peri-urethral structures were evaluated for spongiofibrosis and evidence of false tracts. The duration of the procedure was 10 - 20 minutes, and no complications were encountered. Selected static and dynamic images were recorded for documentation on the video. Strictures were graded as mild (encroachment on less than one-third of the lumen), moderate (encroachment on one-third to one-half) and severe (encroachment on more than half).

For RUG a 12F urethral catheter was inserted into the distal urethra and 2 ml of saline was injected into the balloon to secure its position in the fossa navicularis. Ten to 15 ml of radiographic contrast (Urografin) was infused under fluoroscopy and

spot films were taken. Dynamic images were also recorded on the video. Stricture length was determined by direct measurement on the film without correcting for magnification from variation in the tube film distance. If the stricture was complete the bladder was filled via a suprapubic catheter (already in place) with 200 - 300 ml of Urografin and the patient was asked to try and void under fluoroscopic guidance. Spot films were taken. The results of the RUG were compared with the ultrasound findings (Fig. 2).

Results

Of the 22 patients examined with RUG and SUG, 19 had stricture length longer on SUG than RUG (Figs 3 and 4), in 2 patients the length was longer on SUG, and only in 1 patient the results of the ultrasound were comparable with the standard imaging technique. The concomitant findings are given in Fig. 5. Five patients

demonstrated mucosal hypertrophy and debris, 3 had urethral polyps (Fig. 6), 1 showed a urethral stone (Fig. 7), 1 demonstrated a diverticulum and a sinus tract, and peri-urethral fibrosis was seen in 1 patient.

In general the correlation between radiographic and sonographic studies was poor. RUG underestimated the stricture length and provided no information on peri-urethral fibrosis and intraluminal abnormalities.

Discussion

The use of sonography for the study of anterior urethral strictures was first reported in 1988 by McAninch *et al.*,¹ who found it to be a notable improvement over the conventional radiographic examination. It is a more accurate imaging technique for measuring stricture length than the conventional means. Because the scanning probe is aligned directly in the mid-sagittal plane, the axis of

STRICTURE LENGTH

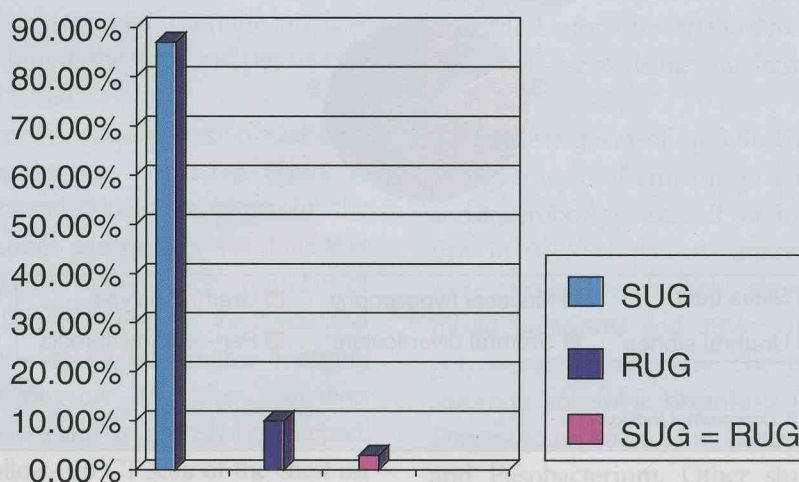


Fig. 2. Stricture length.

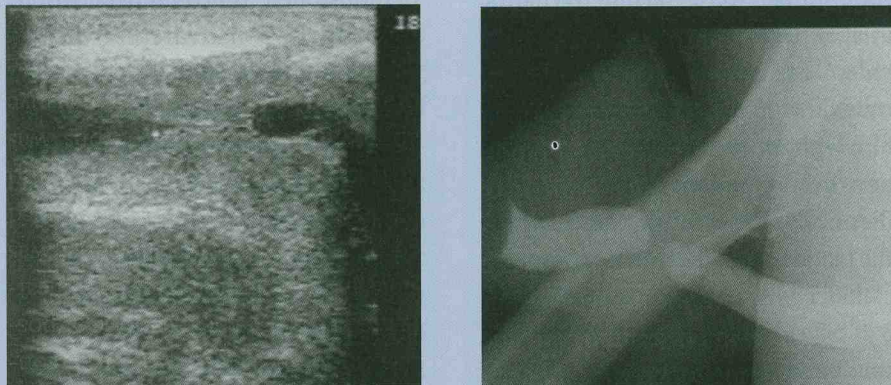


Fig. 3. Retrograde urethrography and comparative sonourethrography clearly show the discrepancy in stricture length.

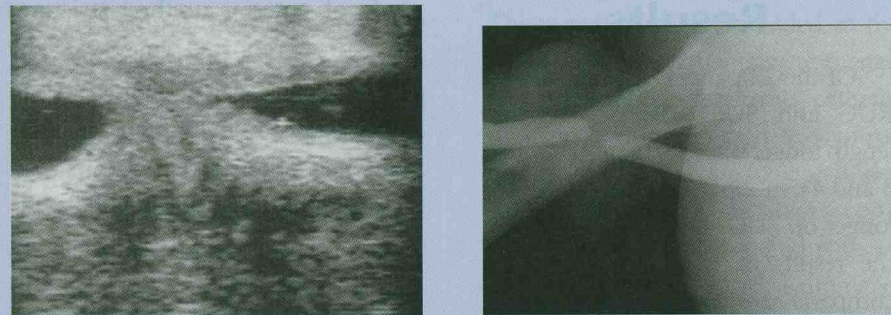
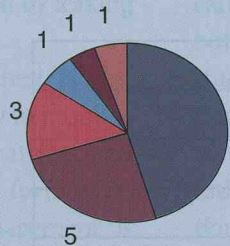


Fig. 4. Another patient with RUG and SUG, demonstrating the stricture to be much longer on SUG.

Concomitant findings



- Sinus tract
- Mucosal hypertrophy
- Urethral polyps
- Urethral stones
- Urethral diverticulum
- Peri-urethral fibrosis

Fig. 5. Concomitant findings.

ment cannot be filled adequately because of high-grade stenosis restricting the passage of contrast medium. SUG can provide useful information for staging urethral strictures.^{2,3,5} It can be repeated pre and postoperatively as there is no risk of radiation.^{5,6} Preoperative finding of stricture length and periurethral fibrosis has therapeutic implications because it determines the mode of management. RUG has the disadvantage of unnecessary radiation exposure to the testes, and it also does not outline the peri-urethral structures.^{4,6}

Based on our preliminary experience of 22 patients, we believe that retrograde SUG is a sensitive technique in detecting anterior urethral strictures, and in 90% of our cases SUG provided important information for both the diagnosis and preferred method of treatment.^{1,7} It can determine stricture length and the degree of spongiofibrosis more accurately than the standard radiographic technique. As there is no risk of radiation exposure, multiple sequential or follow-up scans of the urethra can be obtained after treatment.

Conclusion

SUG is a simple, rapid and readily available technique that provides a reliable, dynamic, three-dimensional assessment of anterior urethral strictures. It is more accurate in measuring stricture length than conventional RUG. It is also better for detecting intra-urethral calculi. Based on this preliminary experience we believe that SUG can be used as a screening technique to evaluate patients with suspected anterior urethral strictures.

measurement is precisely perpendicular to the urethra, whereas the axis of the area under examination of the

X-ray beam is frequently aligned obliquely.⁴ SUG can be particularly useful when the entire stricture seg-

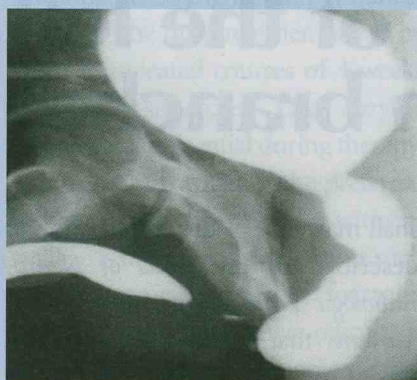
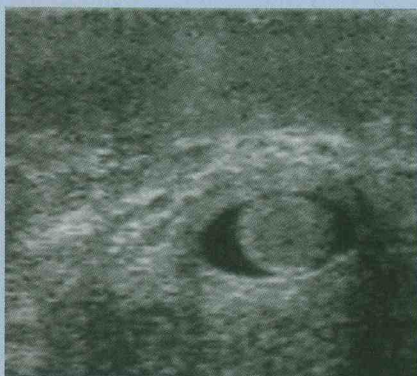

Fig. 6. Concomitant finding of hypertrophied mucosal polyp which was seen on *SUG* and not demonstrated on *RUG*.

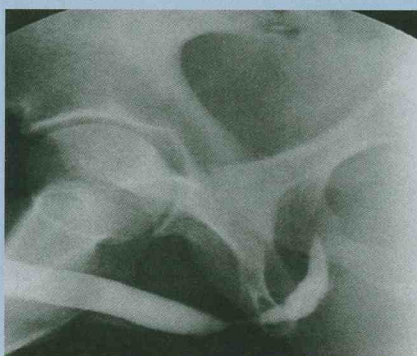
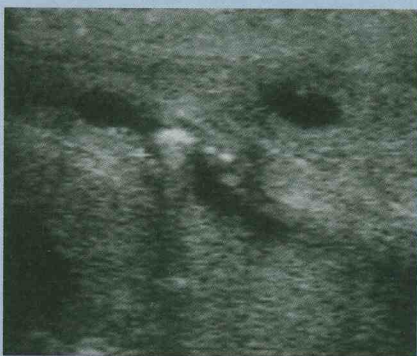
Fig. 7. Concomitant findings — urethral stone, not seen on *RUG*.

References

1. McAninch JW, Laing FC, Jefferey RB. Sonourethrography in the evaluation of urethral strictures: A preliminary report. *J Urol* 1988; **139**: 297-299.
2. Gupta S, Majumdar B, Tiwari A, Gupta RK. Sonourethrography in the evaluation of anterior urethral strictures: Correlation with radiographic urethrography. *J Clin Ultrasound* 1993; **21**: 231-239.
3. Morey AF, McAninch JW. Ultrasound evaluation of male urethra for assessment of urethral stricture. *J Clin Ultrasound* 1996; **24**: 473-479.
4. Morey AF, McAninch JW. Sonographic staging of anterior urethral strictures. *J Urol* 2000; **163**: 1070-1075.
5. Heidenreich A, Derschum W, Wilbert R. Ultrasound in the evaluation of urethral stricture disease: a prospective study in 175 patients. *Br J Urol* 1993; **74**: 93-98.
6. Morey AF, McAninch JW. Role of preoperative sonourethrography in bulbar urethral reconstruction. *J Urol* 1997; **158**: 1376-1379.
7. Peskar DB, Perovic AV. Comparison of radiographic and sonographic urethrography for assessing urethral strictures. *European Radiology* 2003; **10.1007/s00330-003-1929-1941**.



DORLAND'S ILLUSTRATED MEDICAL DICTIONARY

The new 30th edition, including a host of new features and technologies

- PDA Software
- Spellchecker
- Access Dorland's Online
- CD-ROM included
- In full colour for the first time!
- 800 New terms
- The world's best-selling medical dictionary.

List Price: R599.00
Member's Price: R529.00

Available at special discount prices to SAMA members.

To order contact: SAMA - HMPG Bookshop

Tel: (021) 530 6520 • Fax: (021) 531 4126 • E-mail: books@samedical.org / fpalm@samedical.org

