

Raiza Michaela A. Kasilag, MD
Kathrina Aquino-Diaz, MD

Department of Otorhinolaryngology
Head and Neck Surgery
Ospital ng Maynila Medical Center

The Complete and Two-Turn Cochlear Duct Length Among Filipinos

ABSTRACT

Objective: This study aims to measure the complete and two-turn cochlear duct lengths in a Filipino population using archived CT scan images.

Methods:

Design: Retrospective Review of Records
Setting: Tertiary Government Training Hospital
Participants: CT Scan Images of 255 patients

Cochlear images of patients who underwent cranial, facial, orbital, paranasal sinus and temporal bone CT scans from January 2019 to December 2019 were analyzed. Coronal oblique images from 3D multiplanar reconstructions were obtained and a single linear measurement ('A' value) was used as the spiral coefficient to calculate the complete cochlear duct length (CDL) and two-turn length (2TL).

Results: A total of 510 cochlear images were obtained from the CT scan images of 255 subjects (143 males, 112 females aged 1 to 81 years; mean age = 47 years). The mean 'A' value was 8.81 mm (SD = 0.20). The mean complete cochlear duct length was 32.68 mm (31.01 mm – 35.50 mm; SD = 0.834) while the mean two-turn cochlear duct length was 29.61 mm (28.14 mm – 32.08 mm; SD = 0.732). The complete and two-turn cochlear duct lengths in males were found to be significantly longer than in females ($p = .001$). No significant difference was found between cochlear measurements for left and right ears.

Conclusion: The mean complete cochlear duct length among Filipinos in our study measures 32.68 mm while the mean two-turn cochlear duct length measures 29.61mm. Both complete and two-turn cochlear duct lengths were longer among Filipino males than among females.

Keywords: *cochlea; cochlear duct length; two-turn length; high-resolution computed tomography (HRCT)*

Cochlear duct length is defined as the length of the scala media obtained by measuring the distance from the middle of the round window to the helicotrema.^{1,2} Knowledge of the cochlear duct length measured pre-operatively is valuable for the cochlear implant surgeon for precise intracochlear electrode array placement. With variable electrode implant lengths available, cochlear duct length plays a significant role in the depth of insertion and the success of hearing improvement as well as hearing preservation.^{2,3} Previous studies have established

Correspondence: Dr. Kathrina Aquino-Diaz
Department of Otorhinolaryngology
Head and Neck Surgery
Ospital ng Maynila Medical Center
Quirino Ave. cor. Roxas Blvd, Malate, Manila 1004
Philippines
Phone: (+632) 8524 6061 local 220
Email: ommc_enthns@yahoo.com

The authors declared that this represents original material that is not being considered for publication or has not been published or accepted for publication elsewhere in full or in part, in print or electronic media; that the manuscript has been read and approved by the authors, that the requirements for authorship have been met by each author, and that the authors believe that the manuscript represents honest work.

Disclosures: The authors signed a disclosure that there are no financial or other (including personal) relationships, intellectual passion, political or religious beliefs, and institutional affiliations that might lead to a conflict of interest.

Presented at the Philippine Society of Otolaryngology – Head and Neck Surgery Descriptive Research Contest (2nd Place) November 8, 2021



Creative Commons (CC BY-NC-ND 4.0)
Attribution - NonCommercial - NoDerivatives 4.0 International



the cochlear duct length among various populations in North America, Europe and Australia,^{4,7} while subsequent studies in Asian populations showed significantly shorter values.^{2,8-10} A search of the English medical literature on HERDIN Plus, the ASEAN Citation Index (ACI), the WHO Global Health Library – Western Pacific Region Index Medicus (GIM-WPRIM), Directory of Open Access Journals (DOAJ), MEDLINE (PubMed and PMC) and Google Scholar using the search terms “Filipino cochlear duct length,” “Filipino CDL values,” “normative Filipino cochlear duct measurements,” and “cochlear implant,” yielded no previous studies on the CDL among a Filipino population. Since the numbers of cochlear implantation surgeries being done in the Philippines continues to increase at a steady rate, it is important to establish normative CDL values among the Filipino population.

The cochlear duct length has been previously measured using 4 major techniques: 1) direct method, involving microscopic evaluation of histologic sections using a micrometer;¹¹⁻¹³ 2) indirect method, which measures CDL using landmarks from plastic casts or histologic sections;¹⁴ 3) 3D reconstruction of the cochlea using 3D coordinate;¹⁵⁻¹⁷ and 4) by using linear measurements on imaging and representing the cochlea as a mathematical spiral function.⁵⁻¹⁰

Three-dimensional (3D) reconstruction from histologic sections is said to be the most accurate method in measuring cochlear dimensions. However, the amount of time needed to make such measurements make this method difficult to use. Making singular linear measurements on high-resolution CT scans of the temporal bone, however, allows accurate measurements of cochlear dimensions in less time, making the spiral coefficients method the more popular choice in recent studies.^{2,3} In addition to finding the complete cochlear duct length, there is a growing interest in the two-turn (2TL) cochlear duct length in an attempt to mitigate the anatomical variations between cochleae. With previous studies noting that such variations exist only in the apical turn, calculating the 2TL (basal and middle turn) decreases the variations in computed cochlear duct lengths, and as a corollary. Better correlation was demonstrated by multiple studies among 2TL than complete cochlear duct length.^{11,14,18}

This study aims to establish normative cochlear duct length values using archived CT scan images, specifically the mean complete and two-turn cochlear duct length in a Filipino population.

METHODS

With institutional review board approval from the San Juan de Dios Educational Foundation Institutional Review Board (SJIRB-2021-0004), this retrospective review of records obtained archived cochlear images of patients who underwent cranial, facial, orbital, paranasal sinus and temporal bone computed tomography scans for various indications from January 2019 to December 2019 at the Ospital ng Maynila Medical Center.

The minimum number of patients was determined at 95% level

of confidence, power = 80%, detectable mean difference of 0.1, and standard deviation of 0.4. The computed minimum sample size for this study was 252 patients, calculated using Open Source Epidemiologic Statistics for Public Health (OpenEpi Version 3.01 Updated 20103/0004/06) Available from <https://openepi.com/SampleSize/SSMean.htm>.

All included scans were obtained using the same single 24 detector-row Brivo CT385 Helical CT (GE Medical Systems Inc., WI, USA), employing 0.625mm section thickness, 120kV tube voltage, 54 mA tube current, 1.5s revolution time, 512 x 512 matrix resolution, 0.9375 pitch factor, and 70mm field of view parameters. Computed tomography scans that were found to have either congenital or acquired cochlear or inner ear pathologies based on the official reading of a board-certified radiologist were excluded from the study.

In compliance with the provisions of the hospital’s ethics review board, temporal bone image isolation was done on all computed tomography scans meeting the above-mentioned criteria. The scans were processed using RadiAnt DICOM Viewer version 5.5.1 (Medixant, Poznan, Poland) with a 4000 window width and 1000 window level.

Since a view of the entire basal turn of the cochlea (showing one full 360-degree turn from the round window onwards) was not possible using a single 2-dimensional plane, a multiplanar reconstruction using minimum intensity projection was made. By aligning the multiplanar reconstruction axes parallel to the basal turn on axial (*Figure 1A*) and sagittal (*Figure 1B*) planes, multiplanar reconstruction of the inner ear was done to produce a coronal oblique (*Figure 1C*) image of the cochlea. The resulting coronal oblique image was able to show the entire basal turn of the cochlea, round window, oval window and anterior parts of the superior and lateral semicircular canals. The largest distance from the middle of the round window, passing through the modiolus to the opposing lateral wall of the cochlea was obtained as the ‘A’ value.⁵ For this distance, two separate measurements were individually obtained by each author, and the average was taken as the final measurement for the ‘A’ value. Measurements were obtained for both ears of all patients.

The obtained ‘A’ value was the spiral coefficient used to calculate the complete cochlear duct length (CDL) and two-turn length (2TL). Cochlear duct length was calculated as $CDL = 4.16A - 3.98$ while the 2 turn length was computed using the equation $2TL = 3.65(A - 0.7)$.¹⁸

Demographic and clinical characteristics of patients were recorded in Microsoft Excel version 16.16.27 (Microsoft Corporation, Redmond, WA, USA). Categorical data were presented as frequencies and percentages while numerical data were summarized using mean and standard deviation with its minimum and maximum values. Interval estimates for mean were reported using a 95% confidence interval and were compared to reported values in literatures. Group means of numerical variables (for example left versus right CDL) were computed then compared using independent sample t-test. All tests were performed at 5% level of significance (α).

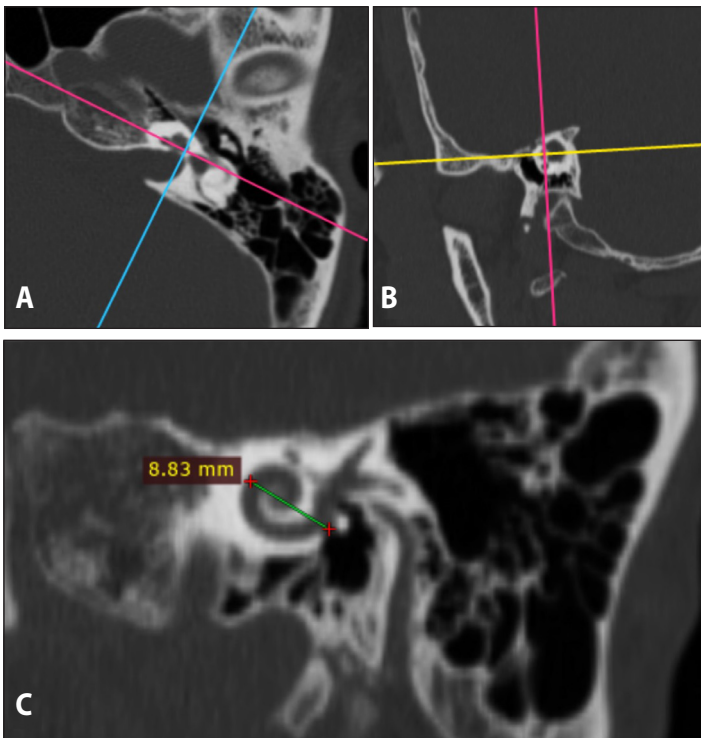


Figure 1. Temporal bone CT bone window images of the left ear showing the basal turn of the cochlea: **A.** plain axial; **B.** plain sagittal cuts; and **C.** Coronal oblique image obtained from multiplanar reconstruction of the same axial and sagittal cuts showing measurement for 'A' value

RESULTS

A total of 510 cochlear images were obtained from the CT scan images of 255 patients (143 males and 112 females; aged 1 to 81 years; mean age = 47 years) and reconstructed for further analysis.

The 'A' value (largest distance from the middle of the round window, passing through the modiolus, to the opposing lateral wall of the cochlea) ranged from 8.41 mm to 9.49 mm (M = 8.81 mm; SD = 0.20). The mean complete cochlear duct length was 32.68 mm (31.01 mm – 35.50 mm; SD = 0.83) while the mean two-turn cochlear duct length was 29.61 mm (28.14 mm – 32.08 mm; SD = 0.73).

The mean complete CDL of the 143 males (M = 32.85, SD = 0.87) compared to the mean complete CDL of the 112 females in the study (M = 32.49, SD = 0.75) were significantly longer, $t(253) = 3.48, p = .001$. Likewise, the mean two-turn CDL values among males (M = 32.49, SD = 0.75) were also noted to be significantly longer, $t(253) = 3.50, p = .001$ than the mean two-turn cochlear duct length among females (M = 29.44, SD = 0.66).

The mean complete cochlear duct length on the right ear of all subjects was 32.67 mm (32.57 mm – 32.78 mm; SD = 0.83) while that of the left ear was 32.69 mm (32.59 mm – 32.79 mm; SD = 0.84). The mean two-turn cochlear duct length of the right and left ears were 29.61 mm (29.52 mm – 29.70 mm; SD = 0.73) and 29.62 mm (29.53 mm – 29.71 mm; SD = 0.73), respectively.

DISCUSSION

Our present study found the mean 'A' value for the Filipino cochlea was 8.81 mm, which when used as a spiral coefficient would lead to a mean complete cochlear duct length value of 32.68 mm while the mean two-turn cochlear duct length was 29.61 mm. In addition, significantly longer values ($p = .001$) for both the complete and two-turn cochlear duct length among Filipino males were found than that for Filipino females.

Since the advent of cochlear implantation, increasing interest in cochlear dimensions and how they affect electrode design and insertion has been observed.¹⁻⁴ Cadaveric examinations of human cochlea were time-consuming and did not allow real time physiologic correlation.^{5,6,18} Although 3D reconstruction is the most accurate method of determining cochlear duct length, the spiral coefficient method allows surgeons to use a single linear measurement on pre-operative CT scans to approximate cochlear duct lengths. Since considerable inter-population variations in cochlear duct length has been proven,⁴⁻¹⁰ the need to produce electrodes accordingly is increasing in order to improve postoperative outcomes.¹

Compared to previous methods historically employed in measuring cochlear duct length, Escudé *et al.*⁵ provided a single value 'A' measured by the surgeon on high-resolution CT images of the temporal bone that predicted electrode placement during surgery. This value 'A' is the largest distance from the round window to the lateral wall, passing through the mid-modiolar axis. In their study, incorporating value 'A' into a basic spiral function allowed prediction of the cochlear duct length.⁵

Alexiades *et al.* deem that the two-turn CDL strikes the balance between achieving adequate cochlear coverage and decreasing insertional trauma to the apical region. 'A' values of 7.3, 8.4, and 9.2mm equate to 2TL values of 24-, 28-, and 31-mm lengths, respectively, aiding the surgeon in pre-operative selection of electrode array.¹⁸ One variation also notable in previous studies was the zero reference angle – the location in which the measurement of the 'A' value began. Measurements in some studies started at the inferior edge of the round window, while others used the middle portion of the round window as the starting point.¹⁹ To address this difference, a consensus panel on a cochlear coordinate system in 2010 established the zero reference angle as the center of the round window.²⁰

Similar to other studies,^{8,9,11,13} significant differences between both the complete and two-turn cochlear duct lengths of males and females were found in this study. Cochlear duct length among males has been found to be significantly longer than among females using the various methods for CDL measurement. It was first hypothesized by Sato *et al.*¹³ that the significant CDL differences consistently observed between sexes but not between various age groups is a function of sexual dimorphism instead of continued cochlear growth as a person ages. It was further hypothesized in their study that similar function is



noted for the same percentage distance along the basilar membrane despite differences in cochlear duct length among sexes, suggesting that longer latency is required for cochlear transduction in males than females – evidenced by a significantly longer latency of wave I in auditory brainstem responses in males.¹³

Compared with measurements made in the reported literature worldwide which also employed spiral coefficients, the mean complete cochlear duct length of Filipinos found in our present study was shorter than that of Northern American and European populations. A study among North Americans by Skinner *et al.* found a mean complete CDL of 34.62mm (SD = 1.2).⁷ A similar study by Escudé *et al.* among Europeans found a mean complete CDL of 34.4 mm (SD = 2.2).⁵ Both studies showed mean CDL values that were significantly longer than those of our Filipino population ($p = .001$). Comparisons with published mean CDL values among other Asian populations however, showed similar or shorter values than those found for Filipinos in our present study. The mean complete CDL of Filipinos in our present study is significantly longer ($p < .001$) than that of the Saudi Arabian population ($M = 31.882$; $SD = 2.65$).⁹ Interestingly, there was no significant difference in the complete CDL (mean = 32.45; $SD = 1.31$) among an Indonesian population in the study by Zahara *et al.*¹⁰ compared to the complete CDL of Filipinos ($p = .127$). The similarity between the complete CDL among Filipinos and Indonesians in these studies may reflect our partial Indo-Malay ancestry. While previously identified differences among

North American and European versus Asian cochlear duct lengths may be related to larger head sizes for the former, further investigations are needed as the previously published literature and our present study have not measured and correlated racial head sizes to cochlear duct length.

This study is not without its limitations. CT images with incidental findings of congenital and acquired inner ear malformations were excluded, so there were no associations made with pathologic findings. In addition since data collected were computed tomography scans from a single institution, findings may not have included variations, if any, for CDL measurements in other regional populations in the country. It is recommended that future studies incorporate CT data from multiple institutions in different regions in the Philippines and to also incorporate patient age and audiometric data in further investigations.

In conclusion, the mean complete cochlear duct length among the Filipinos in our study measured 32.68 mm while the mean two-turn cochlear duct length measured 29.61mm. Both complete and two-turn cochlear duct lengths were longer in Filipino males than females. Although existing variations in the cochlea necessitate the need for individual pre-operative CT measurements, trends are apparent between sexes as well as among different races, with Asian CDL measurements (including those of Filipinos) being shorter than those in North American and European populations.

ACKNOWLEDGEMENTS

We would like to thank Dr. Manolo C. Maglonzo, MD, FPCR for his inputs to improve the research methodology, Mr. Ruben Mendoza for sharing his technical expertise in CT Imaging and DICOM software use and Mr. Roy Alvin Malenab for his assistance in statistical analysis.

REFERENCES

1. Erixon E, Rask-Andersen H. How to predict cochlear length before cochlear implantation surgery. *Acta Otolaryngol.* 2013 Dec;133(12):1258–65. DOI: 10.3109/00016489.2013.831475; PubMed PMID: 24053486.
2. Grover M, Sharma S, Singh SN, Kataria T, Lakhawat RS, Sharma MP. Measuring cochlear duct length in Asian population: worth giving a thought!. *Eur Arch Otorhinolaryngol.* 2018 Mar;275(3):725–728. DOI: 10.1007/s00405-018-4868-9; PubMed PMID: 29332169.
3. Koch R, Ladak HF, Elfarnawany M, Agrawal SK. Measuring cochlear duct length – a historical analysis of methods and results. *J Otolaryngol Head Neck Surg.* 2017 Mar; 46(1):19. DOI: 10.1186/s40463-017-0194-2; PubMed PMID: 28270200; PubMed Central PMCID: PMC5341452.
4. Ketten DR, Skinner MW, Wang G, Vannier MW, Gates GA, Neely JG. In vivo measures of cochlear length and insertion depth of nucleus cochlear implant electrode arrays. *Ann Otol Rhinol Laryngol Suppl.* 1998 Nov;175:1–16. PubMed PMID: 9826942.
5. Escudé B, James C, Deguine O, Cochard N, Eter E, Fraysse B. The size of the cochlea and predictions of insertion depth angles for cochlear implant electrodes. *Audiol Neurotol.* 2006;11 Suppl 1:27–33. DOI: 10.1159/000095611; PubMed PMID: 17063008.
6. Kawano A, Seldon HL, Clark GM. Computer-aided three-dimensional reconstruction in human cochlear maps: measurement of the lengths of organ of corti, outer wall, inner wall, and Rosenthal's canal. *Ann Otol Rhinol Laryngol.* 1996 Sep;105(9):701–9. DOI: 10.1177/000348949610500906; PubMed PMID: 8800056.
7. Skinner MW, Ketten DR, Holden LK, Harding GW, Smith PG, Gates GA, et al. CT-derived estimation of cochlear morphology and electrode array position in relation to word recognition in nucleus-22 recipients. *J Assoc Res Otolaryngol.* 2002 Sep;3(3):332–50. DOI: 10.1007/s101620020013; PubMed PMID: 12382107.
8. Thong J, Low D, Tham A, Liew C, Tan T, Yuen H. Cochlear duct length—one size fits all? *Am J Otolaryngol.* 2017 Mar-Apr;38(2):218–221. DOI: 10.1016/j.amjoto.2017.01.015; PubMed PMID: 28139318.
9. Alanazi A, Alzhrani F. Comparison of cochlear duct length between the Saudi and non-Saudi populations. *Ann Saudi Med.* 2018 Mar-Apr; 38(2):125–129. DOI: 10.5144/0256-4947.2018.125; PubMed PMID: 29620546; PubMed Central PMCID: PMC6074369.
10. Zahara, D., Dewi, R. D., Aboet, A., Putranto, F. M., Lubis, N. D., & Ashar, T. Variations in Cochlear Size of Cochlear Implant Candidates. *Int Arch Otorhinolaryngol.* 2019 Apr;23(2):184–190 DOI: 10.1055/s-0038-1661360; PubMed PMID: 30956703; PubMed Central PMCID: PMC6449142
11. Hardy M. The length of the organ of corti in man. *American Journal of Anatomy.* 1938 Jan;62(2):291–311. DOI: 10.1002/aja.1000620204.
12. Úlehlová L, Voldřich L, Janisch R. Correlative study of sensory cell density and cochlear length in humans. *Hear Res.* 1987;28(2-3):149–51. DOI: 10.1016/0378-5955(87)90045-1; PubMed PMID: 3654386.
13. Sato H, Sando I, Takahashi H. Sexual dimorphism and development of the human cochlea. computer 3-D measurement. *Acta Otolaryngol.* 1991;111(6):1037–40. DOI: 10.3109/00016489109100753; PubMed PMID: 1763623.
14. Erixon E, Högstorp H, Wadin K, Rask-Andersen H. Variational anatomy of the human cochlea: implications for cochlear implantation. *Otol Neurotol.* 2009 Jan;30(1):14–22. DOI: 10.1097/MAO.0b013e31818a08e8; PubMed PMID: 18833017.
15. Meng J, Li S, Zhang F, Li Y, Qin Z. Cochlear size and shape variability and implications in cochlear implantation surgery. *Otol Neurotol.* 2016 Oct;37(9):1307–13. DOI: 10.1097/MAO.0000000000001189; PubMed PMID: 27579839.
16. Takagi A, Sando I. Computer-Aided Three-Dimensional Reconstruction: A Method of Measuring Temporal Bone Structures Including the Length of the Cochlea. *Ann Otol Rhinol Laryngol.* 1989 Jul;98(7 Pt 1):515–522. DOI: 10.1177/000348948909800705; PubMed PMID: 2751211.
17. Shin KJ, Lee JY, Kim JN, Yoo JY, Shin C, Song WC, et al. Quantitative Analysis of the Cochlea using Three Dimensional Reconstruction based on Microcomputed Tomographic Images. *Anat Rec (Hoboken).* 2013 Jul;296(7):1083–8. DOI: 10.1002/ar.22714; PubMed PMID: 23670819.
18. Alexiades G, Dhanasingh A, Jolly C. Method to estimate the complete and two-turn cochlear duct length. *Otol Neurotol.* 2015 Jun;36(5):904–7. DOI: 10.1097/MAO.0000000000000620; PubMed PMID: 25299827.
19. Dimopoulos P, Muren C. Anatomic variations of the cochlea and relations to other temporal bone structures. *Acta Radiol.* 1990 Sep;31(5):439–44. PubMed PMID: 2261286.
20. Verbit BM, Skinner MW, Cohen LT, Leake PA, James C, Boëx C, et al. Consensus panel on a cochlear coordinate system applicable in histologic, physiologic, and radiologic studies of the human cochlea. *Otol Neurotol.* 2010 Jul;31(5):722–30. DOI: 10.1097/MAO.0b013e3181d279e0; PubMed PMID: 20147866; PubMed Central PMCID: PMC2945386.