

Light Guided Endoscopic Dacryocystorhinostomy

Jamshed Nasir, Iftikhar Aslam

Pak J Ophthalmol 2006, Vol. 22 No.3

.....
See end of article for
authors affiliations

.....
Correspondence to:
Jamshed Nasir
Department of Ophthalmology
Fatima Memorial Hospital
Lahore

Received for publication
July' 2005
.....

Purpose: To evaluate the outcome of light guided endoscopic dacryocystorhinostomy (DCR).

Material and Methods: Seven patients above the age of 35 years were recruited for the said study at the Combined Military Hospital Lahore. Careful selection of patient and assessment of their lacrimal apparatus status was established with radiological test. All those with Nasolacrimal duct obstruction irrespective of the level of obstruction were included in the study after proper consent. A joint venture by ENT and Eye surgeon involving introduction of fiber optic bright light commonly used for Vitrectomy through the lower canaliculus into the Lacrimal sac directed towards the medial wall of the sac which shines through in the dark room environment from the lateral wall of the nasal cavity and is marked by the surgeon. The mucous membrane and than the bone is removed through a bone cutter and the sac is reached. The sac wall is incised and later intubated for a period of three months.

Results: Initial results were encouraging in the form of reduction and disappearance of epiphora. Once the tube was removed, five out of seven patients showed remarkable and two showed moderate improvement in their symptoms of epiphora. A success rate of 100% was achieved as far the patient symptom was concerned. Individual patients were followed for a period of one year, after which a final assessment of their drainage system was made and was found to have satisfactory drainage system and patency.

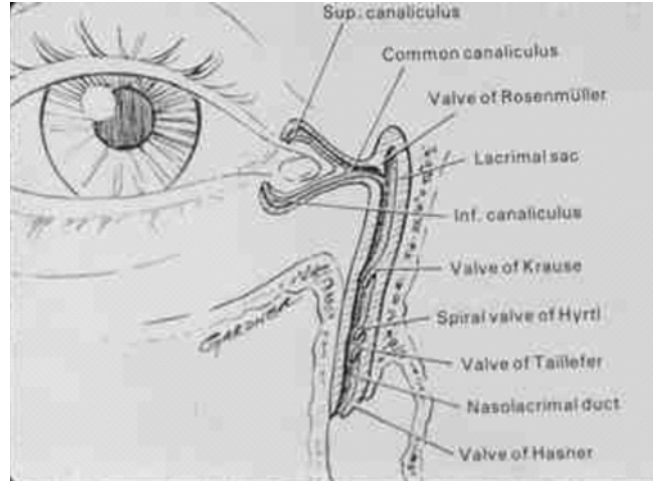
Conclusion: This study demonstrated that good results can be achieved in cases of persistent epiphora due to nasolacrimal duct obstruction with less traumatic surgical procedure under local anaesthesia with equal or better results. A long term follow up is still awaited and we expect to have good outcome once a long term follow up is established.

Key words: Dacryocystorhinostomy, Endoscopic dacryocystorhinostomy. Nasolacrimal duct obstruction, Epiphora.

Dacryocystorhinostomy or DCR, a very well known surgical procedure for Chronic Dacryocystitis with NLD obstruction has dual approach, the external conventional approach done by the Ophthalmic Surgeon and the relatively

new approach, the internal/transnasal endoscope assisted approach, a joint venture by the ENT and Eye surgeon. The transnasal DCR can be traced as back as 1893 when Caldwell and West first did this procedure with some success but later on this procedure was


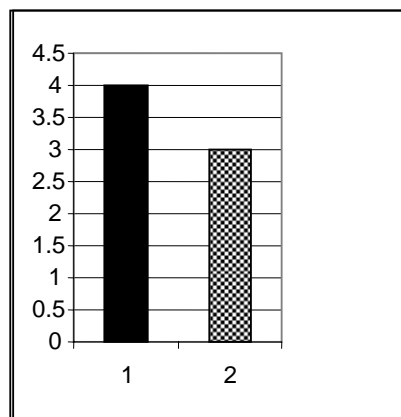
surrendered in favour of external DCR. The Endoscopic transnasal DCR is gaining popularity due to its added advantages of direct visualization over the operated area nasally, less traumatic a procedure in general and the procedure can be done under local infiltration anesthesia easily with good even better results than the external procedure. The Endoscopic DCR is primarily Mcdonogh and Meiring's original work some fifteen years ago. Since then every effort is being made to further improve upon it. The further recent advances in DCR surgery with the use of Lasers(YAG, Carbon dioxide, Argon and KTP Lasers etc) has further simplifies the technique but laser availability with the specified Laser power and setting is still unavailable to most of us. The use of Silicone tubing, stents and other devices also plays important role in the overall success of the procedure. An overall success rate of external DCR ranges between 80-95% and that of Endoscopic DCR between 82-96% has been claimed by various surgeons through their studies^{1,3,15}.



MATERIAL AND METHODS

A prospective study of seven patients for epiphora due to NLD obstruction was included in the study between August' 2001 to August' 2003. These seven patients were followed individually for period not less than 12 months post operatively. Patency of the lacrimal system was assessed by repeated syringing, ENT examination and DCG if needed. The silicone tubing left in the system for maintaining passages along with the sleeve was removed three month post

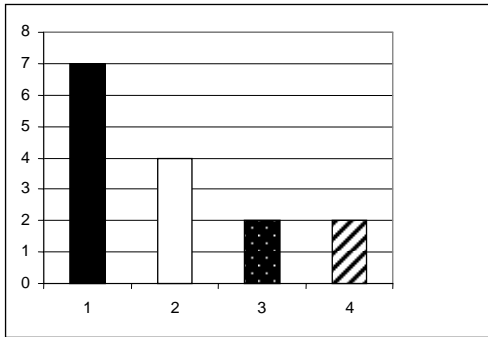
Male to Female Ratio



1. Male (White shade)
 2. Female (Grey)
 Total number of cases

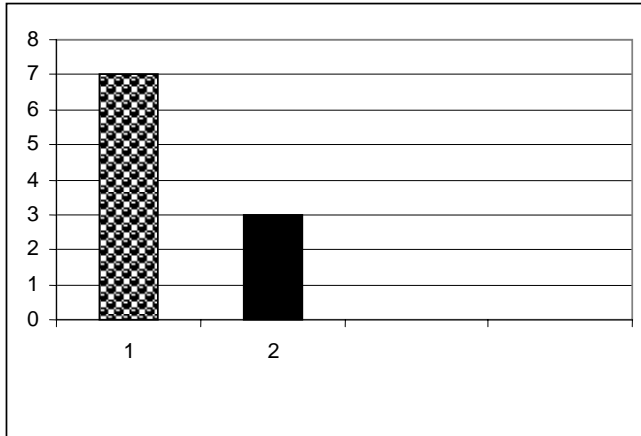
04
 03
 07

Intra operative complications



- | | |
|----------------------------------|----|
| 1. Total cases | 07 |
| 2. Intra operative complications | 04 |
| 3. Intra operative bleeding | 02 |
| 4. Increased Blood pressure | 02 |

Post operative complications



- | | |
|------------------------------|----|
| 1. Total cases | 07 |
| 2. Post operative ecchymosis | 03 |

operatively once the clearance by the ENT surgeon was given about the patency of the ostium.

After proper packing of the nasal cavity with gauze soaked in 4% Lignocaine with adrenaline 1 in 100,000 for ten minutes, clear and decongested area was achieved. 30* light supported rigid endoscope introduced through the nose to mark the area anterior to the middle meatus. The guide line for the mark area is guided through 20G fiber optic light used for vitrectomy procedure is directed through the lower canaliculus and directed towards the medial walls of the Lacrimal fossa. This light, the intensity of which is controlled by the main booster, when shines through the nasal cavity is marked. A U shaped incision is made in the mucous membrane with open end of this U directed posteriorly with a sickle knife. Once the mucous membrane is dissected out, using a bone punch, reverse if needed, the lacrimal bone of same

size was removed .The edge of the bone are smoothened by repeated cutting or bone drill if needed (in one case). The tenting of lacrimal sac by fiber optic light can clearly be seen which then is excised in similar U fashion using a knife.

The DCR tube with its guide wire passed through each of the punctum and the canaliculus is secured at the nostril when extruded. The two tube then are embraced with a sleeve which is wired superiorly towards the ostium and is secured there for the stay period of three months till removal. After the procedure the nasal packing done for 24 hours which then was removed.

RESULTS

The study was conducted for a period of two years starting in August 2001 ending August 2003. The cases were carefully selected for the study and a proper follow up was explained to the patients who followed the instruction with a regular follow up during the study period. A total of seven patients were enrolled for the study with a follow up of one year for individual patient with zero shortfalls at the end of the study. This high success rate is attributed to the available means of communication with the physicians and the patients.

The average age of the patient was 50.5 years ranging from thirty five to seventy two years. The male to female ratio was 4:3 with male dominance in this study. The patients had an ENT examination pre operatively revealing DNS in four cases of mild to moderate nature without nasal obstruction. There was no sign of nasal allergy. The ocular examination pre operatively also did not revealed any major abnormality.

All the patients under went light guided Endoscopic DCR after proper explanation of the procedure to which they accepted on a written form. The intra operative complication included bleeding in two cases (28.57%) and rise in the blood pressure during the procedure in two cases (28.57%) controlled during the surgery. Three patients had ecchymosis (42.88%). This eventually settled in three weeks time. All patients (seven) improved with the procedure with success rate of 100% in the disappearance of their symptom of epiphora and improvement of their clinical condition till the completion of their follow up period of one year. During the follow up period, a joint examination was done by the Ophthalmologist and the ENT surgeon as a routine. The results were appreciably

better^{3,12} than the more traumatic and general anesthesia dependant conventional Dacryocystorhinostomy.

Successful Criteria

- Disappearance of symptoms
- Improvement in clinical signs
- Open ostium of the operated area as seen by the ENT surgeon

(Table 1)

DISCUSSION

Dacryocystorhinostomy is considered the treatment of choice surgical option for epiphora due to Naso lacrimal duct obstruction of various causes discussed earlier. The procedure has a high success rate (over 90% as is proved with various studies) but has some limitation due to following reasons. The procedure preferably is done under general anesthesia therefore per and post operative risks² of general anesthesia are well known to every one although over period of time the anesthesia has become quite safer now. The traumatic procedure of osteotomy used has an impact over the patient for which patient remains uncomfortable for quite some time after the surgery. As compared to conventional DCR³ this procedure is as a routine done under local anesthesia and minimum tissue handling and disruption with even better out come as is shown by the results. The procedure can closely be compared with Laser Endo DCR started recently in some centre. The laser endo DCR is laser dependant which is generally not available in most of the tertiary care eye centre what to talk of primary and secondary centre. This procedure ‘‘Light guided Endoscopic DCR’’ therefore is an alternative to more traumatic general anesthesia dependant conventional DCR and pretty expensive Laser assisted endo DCR and can be done even at smaller centre due to availability of instrument. The technical expertise is not different from the other procedure however an ENT surgeon is asked to help for better per operative and post operative results.

Table 1: Study period, follow up period and age are in years

Description	Results
Study Period	02

Total Patient	07
Follow up period	01*
Follow up shortfall	00
Average age	50.5
Male to Female ratio	4:3
Previous DCR	00
Deviated Nasal Septum	4
Intra Operative bleeding	2
Post operative eechymosis	3
Success rate	100%

CONCLUSION

The result of endoscopic Light guided DCR as compared to conventional external DCR in our study are very encouraging. The initial response is excellent and it appears to be better than the quoted data in the literature of 82% to 92%^{1,15} success of internal DCR as is mentioned in numerous studies in the literature. All patients (100%) were satisfied with the surgical procedure itself and there was no symptoms of Epiphora till the end of first year. A better coordination between ENT and Eye surgeon is the key to successful outcome and the procedure should be followed more than the External DCR.

Author’s affiliation

Dr. Jamshed Nasir
 Department of Ophthalmology
 Fatima Memorial Hospital
 Lahore

Dr. Iftikhar Aslam
 Department of ENT
 CMH Abbatabad

REFERENCES

1. Zaman M, Babar TF, Saeed N. A review of 120 cases of dacryocystorhinostomies (Dupuy Dutemps and Bourguet technique). J Ayub Med Coll Abbottabad. 2003;15:10-2.
2. Fayet B, Racy E, Assouline M. Complications of standardized endonasal dacryocystorhinostomy with unciformectomy. Ophthalmology. 2004; 111: 837-45.
3. Tsirbas A, Davis G, Wormald PJ. Mechanical endonasal dacryocystorhinostomy versus external dacryocystorhinostomy. Ophthalmol Plast Reconstr Surg. 2004; 20: 50-6.
4. Berlucchi M, Staurengi G, Rossi Brunori P, et al. Transnasal endoscopic dacryocystorhinostomy for the treatment of

- lacrimal pathway stenoses in pediatric patients. *Int J Pediatr Otorhinolaryngol.* 2003; 67: 1069-74.
5. **Cokkeser Y, Evereklioglu C, Tercan M, et al.** Hammer-chisel technique in endoscopic dacryocystorhinostomy. *Ann Otol Rhinol Laryngol.* 2003; 112: 444-9.
 6. **Kashkouli MB, Parvaresh M, Modarreszadeh M, et al.** Factors affecting the success of external dacryocystorhinostomy. *Orbit.* 2003; 22: 247-55.
 7. **Dietrich C, Mewes T, Kuhnemund M, et al.** Long-term follow-up of patients with microscopic endonasal dacryocystorhinostomy. *Am J Rhinol.* 2003; 17: 57-61.
 8. **Dolman PJ.** Comparison of external dacryocystorhinostomy with nonlaser endonasal dacryocystorhinostomy. *Ophthalmology.* 2003; 110: 78-84.
 9. **Tsirbas A, Wormald PJ.** Endonasal dacryocystorhinostomy with mucosal flaps. *Am J Ophthalmol.* 2003; 135: 76-83.
 10. **Tsirbas A, Wormald PJ.** Mechanical endonasal dacryocystorhinostomy with mucosal flaps. *Br J Ophthalmol.* 2003; 87: 43-7.
 11. **Minasian M, Olver JM.** The value of nasal endoscopy after dacryocystorhinostomy. *Orbit.* 1999; 18: 167-76.
 12. **Woog JJ, Kennedy RH, Custer PL, et al.** Endonasal dacryocystorhinostomy: a report by the American Academy of Ophthalmology. *Ophthalmology.* 2001; 108: 2369-77.
 13. **Vanderveen DK, Jones DT, Tan H, et al.** Endoscopic dacryocystorhinostomy in children. *JAAPOS.* 2001; 5: 143-7.
 14. **Struck HG.** Value of external dacryocystorhinostomy *Klin Monatsbl Augenheilkd.* 1999; 215: 1-3.
 15. **Zilelioglu G, Tekeli O, Ugurba SH, et al.** Results of endoscopic endonasal non-laser dacryocystorhinostomy. *Doc Ophthalmol.* 2002; 105: 57-62.
 16. **Fayet B, Bernard JA, Ritleng P, et al.** Internal transient palpebral inclusion following dacryocystorhinostomy. *J Fr Ophtalmol.* 1994; 17: 195-9.