

# Micro-Incision Vitreoretinal Surgery in Cases of Idiopathic Macular Hole at a Tertiary Care Hospital

Syed Fawad Rizwi, Muhammad Abdullah Khan, Zeeshan Kamil, Syeda A. Bokhari, Faisal Murtaza, Lubna Feroze

*Pak J Ophthalmol 2017, Vol. 33, No. 3*

See end of article for authors affiliations

Correspondence to:  
Zeeshan Kamil  
Department of Ophthalmology,  
L.R.B.T Free Base Eye Hospital,  
Korangi 21/2, Karachi  
**Email:** dr.zeeshankamil@yahoo.com

**Purpose:** To assess the anatomical and visual results of micro incision vitreoretinal surgery (MIVS) in patients with idiopathic macular hole.

**Study Design:** Quasi experimental study.

**Place and Duration of Study:** LRBT Free Base Eye Hospital, Karachi from January 2014 to December 2014.

**Material and Methods:** The study included 18 eyes of 18 patients with idiopathic macular hole, who underwent MIVS with dye assisted internal limiting membrane (ILM) peeling and 14% perfluoropropane (C<sub>3</sub> F<sub>8</sub>) as internal tamponade. Outcome measures were post-operative visual acuity and anatomical closure. Post-operative follow-up was conducted up to 6 months after the surgery.

**Results:** Eighteen patients were recruited for the study, out of which 11 (61%) were male and 07 (39%) were female. Age ranged from 45 – 70 years (mean age 60.8 ± 5.2 years). Visual improvement of up to 2 lines was seen in 11 (61%) of the patients, whereas, anatomical closure was achieved in 16 (88%) of the patients.

**Conclusion:** Micro incision vitreoretinal surgery (MIVS) in patients with idiopathic macular hole resulted in high anatomical success and significant visual improvement.

**Keywords:** Microincision vitreoretinal surgery, idiopathic macular hole, perfluoropropane.

**I**diopathic macular hole is one of the major vitreoretinal disorders which causes metamorphopsia and poor central vision in the elderly<sup>1</sup>. The overall prevalence is approximately 3.3% per 1000<sup>2</sup>. Numerous causes of macular hole include myopia and trauma but most common cause is idiopathic with a female preponderance in the 7<sup>th</sup> decade<sup>3</sup>. It has been reported that 4-6% of full thickness macular holes close spontaneously<sup>4</sup>. The pathogenesis of idiopathic macular hole has been attributed to the presence of tangential and anteroposterior traction on the fovea by pre-foveal cortical vitreous<sup>5</sup>. It has been postulated, that the

leading factors for spontaneous closure of macular hole are release of vitreo-foveal traction or glial proliferation<sup>6</sup>. Kelly and Wendell were the first surgeons, who report successful closure of idiopathic macular hole<sup>7</sup>. Since then various modifications have vastly improved the surgical outcomes, especially with the introduction of ILM peeling<sup>8</sup> and triamcinolone acetonide use for better visualization of the vitreous gel<sup>9</sup>. Factors which may influence surgical outcomes include the size and duration of macular hole, internal limiting membrane and epiretinal membrane (ERM) peeling, type of gas tamponade used and duration of face down posturing<sup>10</sup>. The type

of internal tamponade used and the duration of face-down positioning has been under much debate. Earlier clinical trials suggested use of long-acting tamponade with  $C_3F_8$  gas and prolonged posturing for about 2 weeks, for improvement in visual acuity and higher rates of macular hole closure<sup>11</sup>. However, other studies recommended short-acting tamponade with a shorter duration of face-down positioning as an effective means to better anatomical and visual outcomes, comparable to those suggested by previous studies<sup>12</sup>. Contrary to these beliefs, two recent studies have suggested that for macular holes < 400  $\mu$ m in size, no face-down posturing was required<sup>13</sup>.

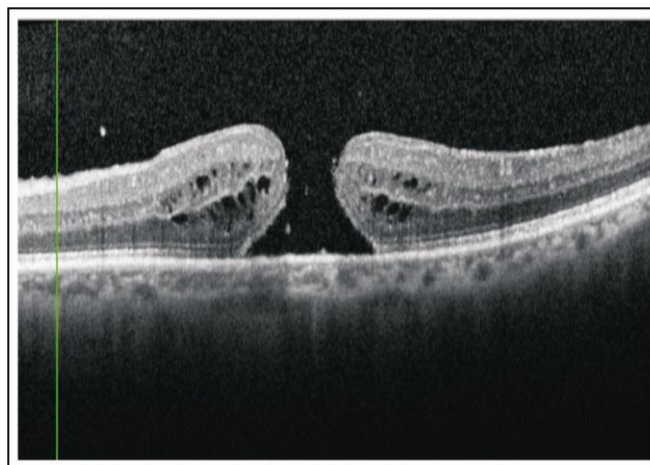
Success rates of up to 70% have been reported after macular hole surgery with ERM peeling and use of  $SF_6$  for internal tamponade.<sup>14</sup> Whereas, anatomical closure of up to 90% have also been reported with vitrectomy, ILM peeling and  $C_3F_8$  gas tamponade.<sup>15</sup>

In the current study, we assessed successful anatomical and visual outcomes of macular hole surgery in our set up.

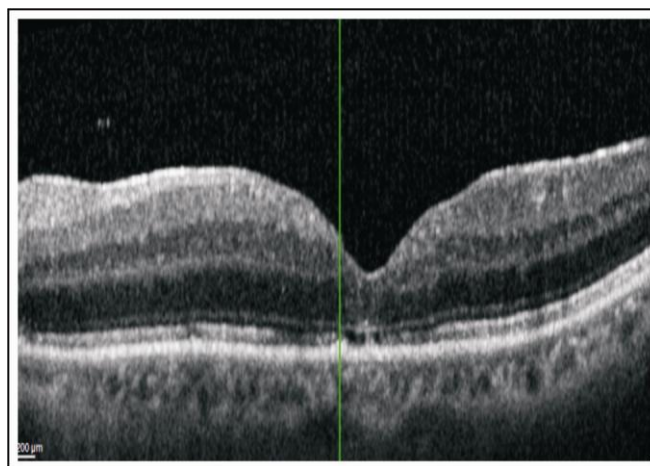
## MATERIAL AND METHODS

This prospective quasi experimental study was conducted on 18 eyes of 18 patients out of which 11 (61%) were male and 7 (39%) were female patients at LRBT Free Base Eye Hospital Karachi from January 2014 to December 2014. All surgeries were carried out by senior vitreo-retinal surgeon (SFR) along with assistant surgeon (FM). The study was approved by institutional ethical review committee. After informed consent, patients with stage 2, 3 or 4 idiopathic macular holes were enrolled in the study. Patients with stage 1 macular hole, macular cysts or secondary macular holes were excluded from the study. Prior to surgical intervention, a detailed history was taken from all the patients, followed by ophthalmic examination on biomicroscopic slit lamp using 90 diopter (D) lens, indirect ophthalmoscopic funduscopy with 20 D lens and visual acuity measurement on Snellen's chart by (MAK). Spectral domain optical coherence tomography (OCT) was used to assess the stage of macular hole (Figure 1) by (LF). All surgeries were performed under local peri-bulbar anesthesia with a mixture of lidocaine (2%) and bupivacain (0.7%). A total of 2 - 3 ml was injected. Under strict aseptic measures, micro-incision vitrectomy using 25+ gauge vitrectomy system (constellation vision system, Alcon® surgicals) was done. Surgical induction of posterior vitreous detachment (PVD) was done

followed by ILM peeling assisted by brilliant blue (BBG) staining. After air-fluid exchange, 14%  $C_3F_8$  was injected for internal tamponade. Post-procedure, patients were advised strict face-down posturing for 2 weeks. The patients were reviewed on post-operative day 1, week 1, 6, 12 and 24. On each visit, best-corrected visual acuity (BCVA), intra-ocular pressure and dilated fundus examination were performed. At week 6 and 24, OCT images were also taken to establish the closure of macular hole (Figure 2). Data collection and recording was done using SPSS statistics 21 by two of the authors (SAB and ZK). The outcome of the surgery was assessed by the extent of the anatomical closure of the macular hole achieved and improvement in the BCVA.



**Figure 1:** Pre-operative OCT (ocular coherence tomography).



**Figure 2:** Post-operative OCT (ocular coherence tomography).

## RESULTS

Eighteen cases of idiopathic macular hole underwent surgery at LRBT Free Base Eye Hospital, Karachi from Jan 2014 to Dec 2014. The mean age of patients was  $60.08 \pm 5.2$  years. Among them 11 patients (61%) were male and 07 patients (39%) were female. Pre-operative BCVA ranged from 6/18 to 6/60 or below, whereas, postoperative BCVA at the end of 24 weeks showed improvement of 2 Snellen's lines or more in 61% of cases. Anatomical closure was achieved in 16 patients (88%) of the eyes (Table 1). Paired t-test was used to analyse the data. P-value of  $< 0.05$  was considered to be significant.

**Table 1:** Indicates pre-operative visual acuity and post-operative visual acuity at the end of 24 weeks follow up.

Visual Acuity	Pre-Operative	Post-Operative (at 24 Weeks)
6/9-6/12	0	02 (11%)
6/18-6/24	02 (11%)	02 (11%)
6/36-6/60	05 (28%)	10 (56%)
6/60 or below	11 (61%)	04 (22%)

## DISCUSSION

The aim of macular hole surgery is to improve the patient's vision and to prevent further visual deterioration. Macular hole closure rates and visual outcomes have improved considerably over the last decade. Important prognostic factors include the time it takes between the onset of hole formation to the development of an anatomical hole, and also the stage of macular hole<sup>16</sup>.

The anatomical success rate for this study was 88%, which is comparable to local and international studies<sup>17-19</sup>. There were 2 patients in whom anatomical success was not obtained despite surgery. These two patients were excluded from the final result of anatomical success, and were planned for a repeat surgery. Nadeem et al also reported the need for repeat surgery in patients in whom anatomical closure was not achieved after the first surgery<sup>19</sup>.

In recent times there has been an increasing trend towards ILM peeling in macular hole surgery. ILM is the basement membrane which supports the Muller cells. Its contraction leads to tangential tractional forces on the macula which contributes in the

pathogenesis of macular hole.<sup>10</sup> Therefore, ILM peeling results in relieving these forces, leading to increased surgical success rates as demonstrated by various studies. Some studies have also suggested that by relieving these tractional forces may reduce the need for prolonged prone positioning<sup>21</sup>.

Significantly higher macular hole closure rates have also been found in cases where dye-assisted ILM peeling was performed for both stage 2 and stage 3 macular holes<sup>18</sup>. Initially, indocyanine green, was being used for this purpose, but it was associated with toxic effects on vitreomacular interface<sup>22</sup>, but now several other dyes have been introduced. In this study Brilliant Blue was used to dye the ILM, for which no toxic effects on retina have been reported<sup>23</sup>.

Different agents for intraocular tamponade have been used including silicon oil and different concentrations of C3F8 gas<sup>24</sup>. In our study we used C3F8 gas which has shown to result in good anatomical and functional outcomes.

Significant improvement in BCVA has been reported in many comparable studies.<sup>25,26</sup> In current study 61% of patients showed best corrected visual improvement of more than 2 snellen's line at the end of 24 weeks of follow up. Other studies have reported visual improvement in 70% of the cases, 24, 27 whereas, Nadeem et al demonstrated an improvement of 2 or more lines in 40% of the cases and one or more line in 6.66% of the cases<sup>19</sup>.

## CONCLUSION

Micro-incision vitreo-retinal surgery with dye-assisted ILM peeling and the use of C3F8 as internal tamponade showed satisfactory visual and anatomical outcomes. However a larger group of operated eyes and a longer follow-up will be required to assess the longterm effects of this procedure.

### Author's Affiliation

Dr. Syed Fawad Rizvi  
M.B.B.S, M.C.P.S, F.C.P.S  
Prof/ Chief Consultant Ophthalmologist  
L.R.B.T Free Base Eye Hospital, Korangi 21/2, Karachi  
Dr. Mohammad Abdullah Khan  
M.B;B.S, M.C.P.S, F.C.P.S  
Asst. Prof/ Consultant Ophthalmologist  
L.R.B.T Free Base Eye Hospital, Korangi 21/2, Karachi  
Dr. Zeeshan Kamil  
M.B;B.S, M.C.P.S, F.C.P.S, F.R.C.S  
Asst. Prof/ Consultant Ophthalmologist

L.R.B.T Free Base Eye Hospital, Korangi 21/2, Karachi

Dr. Syeda Aisha Bokhari

M.B;B.S, F.C.P.S, F.R.C.S

Asst. Prof/ Ophthalmologist

L.R.B.T Free Base Eye Hospital, Korangi 21/2, Karachi

Dr. Faisal Murtaza

M.B;B.S, M.C.P.S, F.C.P.S, F.R.C.S, F.C.P.S (VR)

Asst. Prof/ Consultant Ophthalmologist

L.R.B.T Free Base Eye Hospital, Korangi 21/2, Karachi

Dr. LubnaFeroz

M.B;B.S, Medical Officer

L.R.B.T Free Base Eye Hospital, Korangi 21/2, Karachi

### Role of authors

Dr. Syed Fawad Rizvi

Senior Vitreo-retinal surgeon

Dr. Mohammad Abdullah Khan

Patient Clinical Assessment

Dr. Zeeshan Kamil

Data collection and recording

Dr. Syeda Aisha Bokhari

Data collection and recording

Dr. Faisal Murtaza

Data collection and recording

Dr. Lubna Feroz

OCT conductor

### REFERENCES

1. **Jackson TL, Donochie PH, Sparrow JM et al.** United Kingdom National Ophthalmology Database Study of vitreoretinal surgery: Report 2, macular hole. *Ophthalmology*, 2013; 120: 629-634.
2. **Fine S.** Discussion, macular holes. *Ophthalmology*, 1993; 100: 871.
3. **Margherio RR, Schepens CL.** Macular breaks. I. Diagnosis, etiology and observations. *Am J Ophthalmol*. 1972; 74: 233-40.
4. **Inoue M, Arakawa A, Yamane S et al.** Long-term outcome of macular microstructure assessed by ocular coherence tomography in eyes with spontaneous resolution of macular hole. *Am J Ophthalmol*. 2012; 153: 687-91.
5. **Khaqan HA, Jameel F et al.** Visual outcomes of macular hole surgery, *J Coll Physicians Surg Pak*. 2016; 26 (10): 839-42.
6. **Lo WR, Hubbard JB.** Macular hole formation, spontaneous closure, and recurrence in a previously vitrectomized eye. *A J Ophthalmol*. 2006; 141: 962-4.
7. **Kelly NE, Wendel RT:** Vitreous surgery for idiopathic macular holes. Results of a pilot study. *Arch Ophthalmol*. 1991; 109: 654-659.
8. **Park DW, Sipperly JO, Sneed SR et al.** Macular hole surgery with internal limiting membrane peeling and intravitreal air. *Ophthalmology*, 1999; 106: 1392-1397.
9. **Sakamoto T, Ishibashi T:** visualizing vitreous in vitrectomy by triamcinolone. *Graefes Arch Clin Exp Ophthalmol*. 2009; 247: 1153-1163.
10. **Kumar A, Gogia V, Kumar P et al.** Evaluation of predictors for anatomical success in macular hole surgery in Indian population. *Indian J Ophthalmol*. 2014 Dec; 62 (12): 1141-1145.
11. **Thompson JT, Smiddy WE, Glaser BM et al.** Intraocular tamponade duration and success of macular hole surgery. *Retina*, 1996; 16: 373-382.
12. **Tadayoni R, Vicaut E, Devin F et al.** A randomized controlled trial of alleviated positioning after small macular hole surgery. *Ophthalmology*, 2011; 118: 150-155.
13. **Guillaubey A, Malvitte L, Lafontaine PO et al.** Comparison of face down and seated position after idiopathic macular hole surgery: a randomized clinical trial. *Am J Ophthalmol*. 2008; 146: 128-134.
14. **Wendel RT, Patel AC, Kelly NE et al.** Vitreous surgery for macular holes. *Ophthalmology*, 1993; 100: 1671-6.
15. **Kumar A, Gogia V, Shah VM et al.** Comparative evaluation of anatomical and functional outcomes using brilliant blue G versus triamcinolone assisted ILM peeling in macular hole surgery in Indian population. *Graefes Arch Clin Exp Ophthalmol*. 2011; 249: 987-995.
16. **Kang HK, Chang AA and Beaumont PE.** The macular hole: report of an Australian surgical series and meta-analysis of the literature. *Clin Exp Ophthalmol*. 2008; 28: 298-308.
17. **Gupta B, Laidlaw DAH, Williamson TH et al.** Predicting visual success in macular hole surgery. *Br J Ophthalmol*. 2009; 3: 1488-91.
18. **Christenson US, Kroyer K, Sander B et al.** Value of internal limiting membrane peeling for surgery for idiopathic macular hole stage 2 and 3: a randomized clinical trial. *Br J Ophthalmol*. 2009; 93: 1005-15.
19. **Ahmed N, Shah SRA, Choudry QL et al.** Outcomes of macular hole surgery at Mayo Hospital, Lahore. *Pak J Ophthalmol*. 2012; 28 (2): 77-80.
20. **Lois N, Burr J, Norrie J, et al.** Full-thickness Macular Hole and Internal Limiting Membrane Peeling Study (FILMS) Group. Internal-limiting membrane peeling versus no peeling for idiopathic full-thickness macular hole: a pragmatic randomized controlled trial. *Invest Ophthalmol Vis Sci*. 2011; 52 (3): 1586-1592.
21. **Wickens JC, Shah GK.** Outcomes of macular hole surgery and shortened face-down positioning. *Retina*, 2006; 26: 902-4.
22. **Gandorfer A, Haritoglou C, Kampik A.** Retinal damage from indocyanine green in experimental macular surgery. *Invest Ophthalmol Vis Sci*. 2003; 44 (1): 316-323.

23. **Enaida H, Hisatomi T, Goto Y et al.** Pre-clinical investigation of internal limiting membrane peeling and staining using intravitreal brilliant blue G. *Retina*, 2006; 26 (6): 623-630.
24. **Ivanoska-AAdjievska B, Boskurt S, Semiz F, et al.** Treatment of idiopathic macular hole with silicone oil tamponade. *Clinical Ophthalmology*, 2012; 6: 1449-1454.
25. **Chang LK, Koizumi H, Spaide RF.** Disruption of the photoreceptor inner segment-outer segment junction in eyes with macular holes. *Retina*, 2008; 28: 969-75.
26. **Oh J, Smiddy WE, Flynn HW Jr, et al.** Photoreceptor inner/outer segment defect imaging by spectral domain OCT and visual prognosis after macular hole surgery. *Invest Ophthalmol Vis Sci*. 2010; 51: 1651-1658.
27. **Khokhar AR, Faziur Rabb K, Akhtar HU.** Outcomes of macular hole surgery. *J Coll Physicians Surg Pak*. 2003; 13: 569-72.