

# YAG Laser for Macular Subhyaloid Hemorrhage

Imran Ghayoor, Syed Irshad Haider, Sharif Hashmani, Sadaf Shah

*Pak J Ophthalmol 2012, Vol. 28 No. 2*

.....  
See end of article for  
authors affiliations

.....  
Correspondence to:  
Imran Ghayoor  
Liaqat National Hospital  
Karachi  
.....

**S**ubhyaloid hemorrhage is defined as a localized detachment of vitreous from the retina caused by the accumulation of blood, which can lead to sudden and severe loss of vision, when it takes place in the macular area.

Premacular subhyaloid hemorrhage may occur in retinal vascular disorder such as proliferative diabetic retinopathy, branch retinal vein occlusion, macro aneurysm, and age-related macular degeneration, hematological disorders such as leukemia<sup>1</sup> and chemotherapy induced pancytopenia, following laser in situ keratomileusis (LASIK)<sup>3</sup> because of rapid release of the microkeratome vacume pressure or after retinal vascular rupture associated with physical exertion (Valsalva retinopathy),<sup>2</sup> Terson's Syndrome<sup>4</sup>. Purtscher's retinopathy<sup>5</sup>.

Sub-hyaloid haemorrhage can be managed either conservatively or by vitrectomy<sup>6</sup>. Hyaloidectomy of the posterior hyaloid face is another option<sup>7,8</sup>.

## MATERIAL AND METHODS

Two patients with subhyaloid Macular haemorrhage were selected to undergo Yag laser treatment. We used 3 mirror contact lens and started power setting 6 MJ and used a maximum of 10 MJ till hole is achieved in the posterior hyaloid and one can see blood coming out like a tail of a rat.

## CASE- 1

A 32 years old man referred to the hospital with history of sudden visual loss to hand movement in left eye 5 day's ago. There was no history of systemic or ocular disorders, trauma, or surgery. No further identifiable cause for subhyaloid hemorrhage was found upon systemic evaluation. The right eye had visual acuity 6/6 with correction. The Left eye was HM with or without glasses. Anterior segment of both eyes were normal.

On funduscopy of left eye revealed a round, well circumscribed, dome shaped hemorrhage with a convex surface overlying the posterior pole, extending between the temporal vascular arcade, consistent with a sub-hyaloid or sub internal limiting membrane hemorrhage.

Q-switched neodymium yttrium-aluminum Garnet (Nd-YAG LASER) laser was performed on the posterior hyaloid of the left eye over the dark brown hemorrhage, via the transcorneal route with full pupillary dilatation using a Goldmann-3-mirror contact lens. The aiming beam was precisely focused on the surface of the posterior hyaloid membrane at the inferior edges of the sub-hyaloid hemorrhage to facilitate gravity-induced drainage. At the end of the procedure, the hemorrhage spontaneously drained into vitreous cavity and resorbed after a mean period of 9 to 16 days.

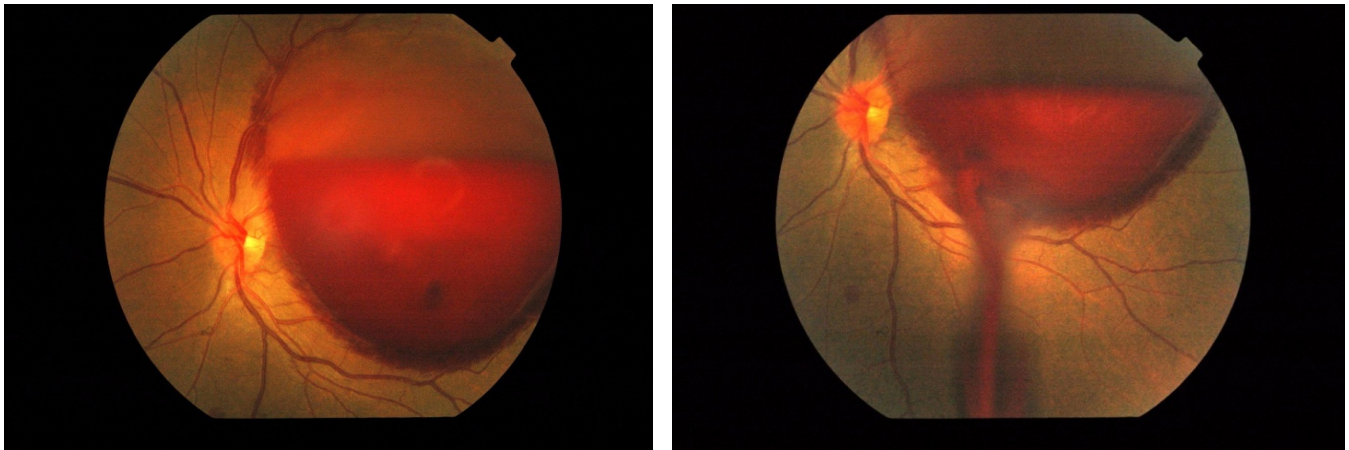


Fig.1: Subhyaloid hemorrhage

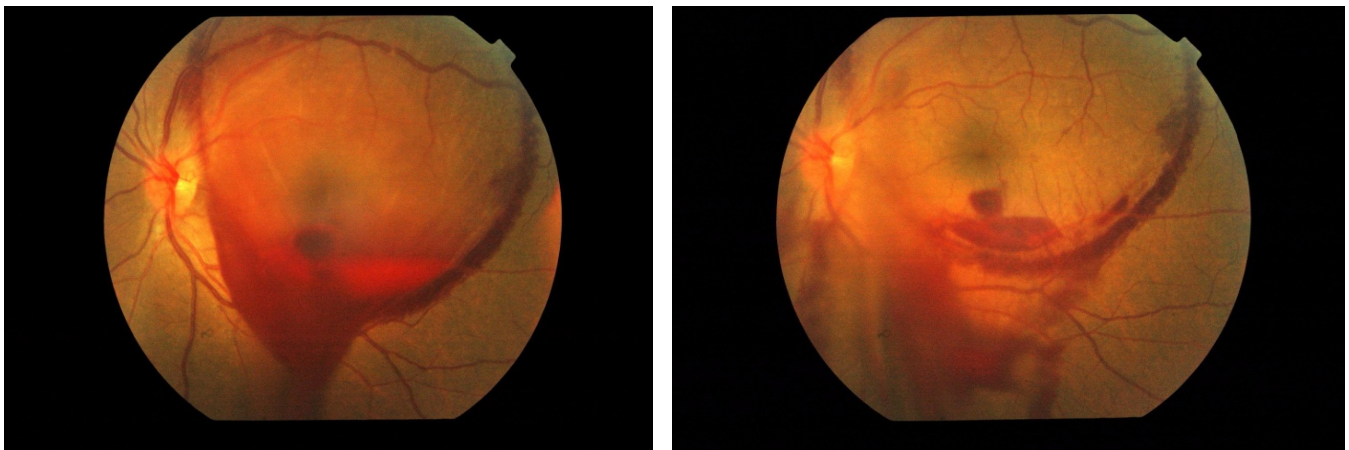


Fig. 2: Blood drainage into Vitreous Cavity after YAG laser

Visual acuity in the affected eye improved to 6/6 after YAG laser.

#### CASE - 2

37 years old insulin dependent diabetic male was referred to the hospital with sudden loss of vision in Left Eye of one week duration, on examination he was found to have proliferative diabetic retinopathy with large subhyaloid hemorrhage covering the macula.

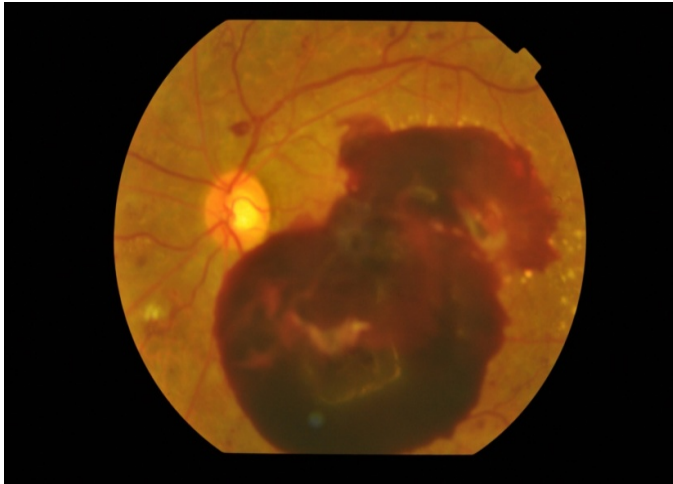
After explaining the situation he underwent PRP in both eyes. To relieve the large subhyaloid hemorrhage. YAG laser was attempted with central part of Goldmann three mirror fundus contact lens. A break in the hyaloid face, which resulted in drainage of blood.

The blood drained gradually with mild inflammation, hyphaema and rise in IOP, which resolved spontaneously after six weeks. The vision

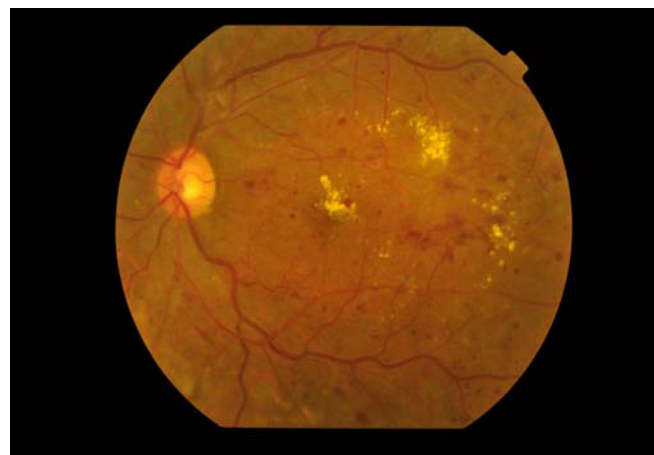
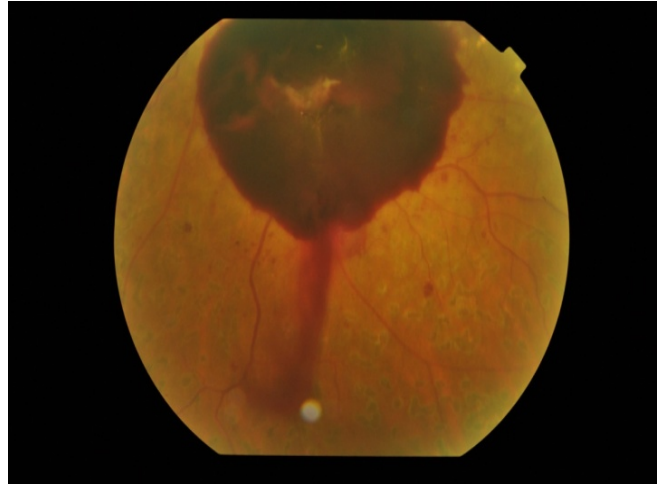
improved from HM to 6\12 on 6 week, in between he also received one Inj Avastin [bevacizumab] and later macular Grid laser, to complete the laser.

#### DISCUSSION

We wanted to report two of our cases of posterior subhyaloid hemorrhage in which sudden visual loss could be reverted to fair visual recovery without reverting to extensive surgery or prolong conservative treatment. In our 1<sup>st</sup> case we could not find any causes although vasa retina<sup>9</sup> is a possibility. In our second case the comparatively young gentleman had IDDM with proliferative diabetic retinopathy. The most interesting thing in him was that his subhyaloid hemorrhage drained through to the anterior segment. He did not have Rubeosis, the mild inflammation seems to result from the trauma of the procedure and the PRP which he received 2 days earlier.



**Fig.1:** Subhyaloid hemorrhage, cotton wool



**Fig. 2:** Blood drainage into Vitreous Spot and exudation. Proliferative Diabetic Retinopathy cavity after YAG laser

We have been experimenting with different contact lenses available with YAG. We wanted to report the use of Goldmann three mirror lens and its central part as none of reported cases mentions the lens used. We found that central portion of Goldmann three mirror lens works well with YAG and easy to focus the aiming beam, and does achieve the break required to drain the blood.

## CONCLUSION

Nd - YAG laser hyaloidotomy in pre-macular subhyaloid hemorrhage is simple, inexpensive outpatient procedures, which results in rapid visual recovery and is relatively safe. Further controlled clinical trials are recommended.

## Author's affiliation

Dr. Imran Ghayoor  
Liaqat National Hospital  
Karachi

Syed Irshan Haider  
Hashmanis Hospital  
Karachi

Dr. Sharif Hashmani  
Hashmanis Hospital,  
Karachi

Dr. Sadaf Shah  
Medical Officer  
Hashmanis Hospital  
Karachi

## REFERENCE

1. **Gass JDM.** Stereoscopic Atlas of Macular Diseases.3rd ed. St Louis: CV Mosby. 1987.
2. **Duane TD.** Valsalva hemorrhagic retinopathy. Trans Am Ophthalmol Soc. 1972; 70: 298 - 313.
3. **Mansour AM, Ojeimi GK.** Premacular subhyaloid hemorrhage following laser in situ keratomileusis. JRefract Surg. 2000; 16: 371-2.
4. **Kuhn F, Morris R, Mester V, et al.** Terson's syndrome. Results of vitrectomy and the significance of vitreous hemorrhage in patients with subarachnoid haemorrhage. Ophthalmology 1998; 105: 472-7.
5. **Agarwal A, McKibbin M.** Purtscher's retinopathy: epidemiology, clinical features and outcome. Br J Ophthalmol. 2007; 91: 1456-9.
6. **Ramsay RC, Knobloch WH, Cantrill HL.** Timing of vitrectomy for active proliferative diabetic retinopathy. Ophthalmology. 1986; 93: 283-9.

7. **Ulbig MW, Mangouritsas G, Rothbacher HH, et al.** Long-term results after drainage of premacular subhyaloid hemorrhage into the vitreous with a pulsed Nd: YAG Laser. Arch Ophthalmol. 1998; 116:1465-9.
8. **Ulbig MW, Mangouritsas G, Rothbacher HH, et al.** Long-term results after drainage of premacular subhyaloid hemorrhage into the vitreous with a pulsed Nd: YAG Laser. Arch Ophthalmol. 1998; 116:1465-9.
9. **Tabatabaee SA, Solaimani M, Mohammad-Reza Mansouri MR, et al.** Purtscher Retinopathy Associated with Valsalva Retinopathy after Accident. Iranian Journal of Ophthalmology. 2009; 21: 70-2.