

Role of Laser Suture Lysis in Immediate Trabeculectomy Failure

Syed Imtiaz Ali Shah, Shujaat Ali Shah, Partab Rai, Shahid Jamal Siddiqui, Safdar Ali Abbasi, Dure Yakta Shaikh

Pak J Ophthalmol 2015, Vol. 31 No. 4

See end of article for authors affiliations

Correspondence to:
Syed Imtiaz Ali Shah
Professor, Department of
Ophthalmology, Chandka
Medical College Larkana
syedimtiazalinaqvi@yahoo.com

Purpose: To study the role of laser suture lysis in immediate trabeculectomy failure.

Material and Methods: This was a prospective case series study conducted at Department of Ophthalmology, Chandka Medical College Hospital Larkana, Pakistan from May 2007 to May 2015. 21 eyes of 20 patients who underwent trabeculectomy for primary open angle glaucoma and encountered immediate trabeculectomy failure were included in the study. Immediate trabeculectomy failure was considered when IOP during first 48 hours after trabeculectomy remained above 25 mm Hg. Laser suture lysis was carried out with Nd: YAG Laser (1064 nm) or with frequency doubled Nd: YAG Laser (532 nm). The pre-procedure and post-procedure IOP was noted and IOP below 18 mm Hg was considered as successful laser suture lysis. Data entry and analysis was done on SPSS version 20.

Results: 12 (60 %) patients out of the total 20 patients were males and 8 (40 %) were females. The mean age \pm standard deviation of patients was 61.45 ± 7.37 years and the age range was 47 to 71 years. IOP came down to normal in all the cases after the laser suture lysis, without encountering any major complications. Mean IOP before laser suture lysis was 30.95 ± 2.20 mm Hg and mean IOP one hour after successful laser suture lysis was 13.38 ± 1.53 mm Hg.

Conclusion: Laser suture lysis is a safe, effective and day care procedure in the management of immediate trabeculectomy failure.

Keywords: Glaucoma, Trabeculectomy, failure, laser, suture.

Trabeculectomy, described firstly by Cairns in 1968,¹ is currently the most popular and widely performed surgery for the treatment of glaucoma.² Despite the advancements in techniques and instruments, trabeculectomy failure remains a significant problem. The rate of trabeculectomy or bleb failure has been reported to be around 10 – 20%.⁴⁻⁶ Trabeculectomy failure may be early (within one month of surgery) or late (after one month of surgery), the latter being more common⁸. The importance of early trabeculectomy failure lies in immediate detection and management. These cases can only be detected when either a sign of raised IOP is picked up

within first 48 hours or a habit of assessment of IOP during immediate postoperative period is developed. Once this complication occurs and remains undetected, it eventually ends up in resorting to more invasive procedures to control IOP, like another surgical procedure with enhancements, including use of cytotoxic medications (MMC^{14,15} and 5-FU^{16,17}) and implants.^{18,19} Topical steroids, 5-fluorouracil (5-FU), ocular massage,³ releasable sutures^{9, 10} and laser suture lysis¹¹⁻¹³ all have been used for the management of early trabeculectomy failure. We took up this study to see the role of laser suture lysis in immediate trabeculectomy failure.

MATERIAL AND METHODS

This prospective case series study was conducted at Department of Ophthalmology, Chandka Medical College Hospital Larkana Pakistan from May 2007 to May 2015. Patients of immediate trabeculectomy failure who underwent trabeculectomy for primary open angle glaucoma were included in the study; immediate trabeculectomy failure was considered when IOP during first 48 hours after trabeculectomy remained above 25 mm Hg. We picked up 21 eyes of 20 patients with immediate trabeculectomy failure, out of 367 eyes of 321 patients undergoing trabeculectomy for primary open angle glaucoma; with the mean immediate failure rate of 5.72%. Patients with primary angle closure glaucoma and secondary glaucoma were excluded from the study. All patients underwent trabeculectomy by the first author. Limbal based conjunctival flaps were created and blunt dissection was done followed by wet field cautery to the sclera for acquiring a clear field and securing hemostasis. A 5 × 5 mm triangular scleral flap was formed, an internal window of 1 × 3 mm was created and a peripheral iridectomy was performed. The scleral flap was sutured with three 8/0 silk or 10/0 nylon sutures and the conjunctiva was stitched with buried 8/0 silk sutures. A subconjunctival injection of antibiotic and steroid combination was given at the end of the procedure. Laser suture lysis was carried out with Nd: YAG Laser (1064 nm) or with frequency doubled Nd: YAG Laser (532 nm). 2 to 2.5 milijoules energy was used when Nd: YAG Laser was utilized and 300 to 400 milivolt energy was used when frequency doubled Nd: YAG Laser was utilized. Laser suture lysis of one edge suture of the triangular scleral flap was done and IOP was recorded after 5 minutes. If IOP did not fall, ocular massage was carried out and if IOP still remained high, another edge suture lysis was carried out followed by ocular massage till the IOP came down to below 18 mm Hg, which was considered as normal IOP and the procedure was considered successful. The pre-procedure and post-procedure IOP was noted and data entry and analysis was done on SPSS version 20.

RESULTS

21 eyes of 20 patients undergoing trabeculectomy for primary open angle glaucoma with immediate trabeculectomy failure were included in the study. 12 (60%) patients were males and 8 (40%) were females (Fig. 1). The mean age ± standard deviation of patients was 61.45 ± 7.37 years and the age range was 47 to 71

years. Laser suture lysis was performed within the first week after the trabeculectomy surgery. IOP came down to normal in all the cases, after laser lysis of one suture in 15 (71.43%) eyes and after laser lysis of two sutures in 6 (28.57%) eyes. Mean IOP before laser suture lysis was 30.95 ± 2.20 mm Hg and mean IOP one hour after successful laser suture lysis was 13.38 ± 1.53 mm Hg (Fig: 2). Only two complications were

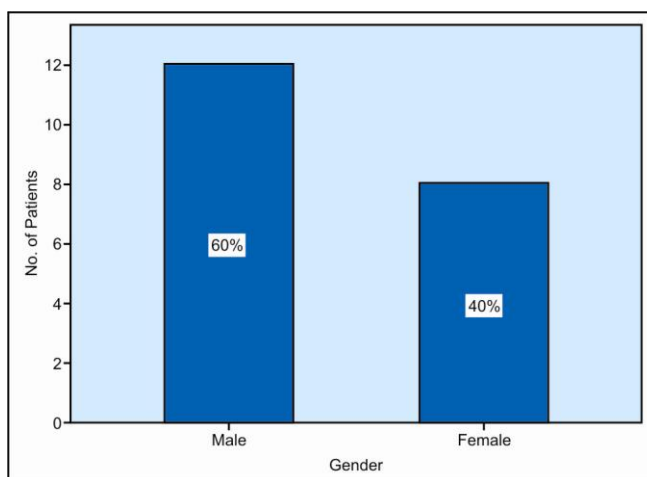


Fig. 1: Age distribution of patients.

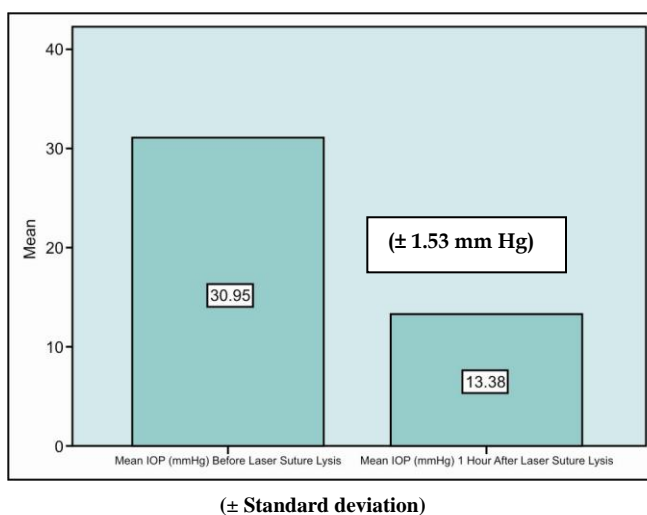


Fig. 2: Mean IOP before and after laser application.

Table 1:

Complication	No. of Patients	Total No. of Patients n (%)
Patient dissatisfaction	02	20 (10)
Bleeding at the sight of the laser application	04	20 (20)

noted after the procedure, which were patient dissatisfaction in 2 cases and bleeding at the sight of laser application in 4 eyes (Table 1), which settled with conservative measures.

DISCUSSION

The technique of laser suture lysis was initially reported in 1983 by Lieberman¹³ with a gonioscope and then in 1984 by Hoskins and Migliazzo⁷ with a special lens developed by them for the management of failing filtering blebs. A previous study by Downes SM et al²⁰ has observed that patients at risk of developing trabeculectomy failure can be identified in the early postoperative period on the basis of IOP. This study noted that patients with initial postoperative IOP of greater than 17 mm Hg had increased chances of going into trabeculectomy failure and those patients having initial postoperative IOP lesser than 17 mm Hg had increased chances of a successful trabeculectomy and long term IOP control. This fact shows the importance of adequate drainage immediately after trabeculectomy and the probable role of laser suture lysis in preventing not only the immediate trabeculectomy failure but late trabeculectomy failure as well. Laser suture lysis is most successful in IOP reduction when it is performed within two weeks of trabeculectomy. Macken P et al²¹ have reported many complications in their study on laser suture lysis such as flat anterior chamber, external aqueous leak, iris incarceration, hyphaema, malignant glaucoma and excessive bleb elevation. Similarly other studies have reported ocular hypotony with laser suture lysis after the use of antimetabolites in trabeculectomy,^{24,25} but in our study we came across minor complications. It seems that laser suture lysis results in more complications in eyes which have undergone trabeculectomy with antimetabolites. Overall our study shows that laser suture lysis is an efficient method for the management of immediate trabeculectomy failure as is reported by other studies.^{7,13,22,23}

CONCLUSION

Laser suture lysis is a safe and effective procedure in the management of immediate trabeculectomy failure. It avoids the need of invasive methods and their resultant risks and complications. It is an outpatient procedure, does not require any special expertise and does not need anesthesia.

Author's Affiliation

Dr. Syed Imtiaz Ali Shah
Professor of Ophthalmology
Chandka Medical College, Larkana

Dr. Shujaat Ali Shah
Trainee Registrar
Department of Ophthalmology
Chandka Medical College Larkana

Dr. Partab Rai
Professor of Ophthalmology
Chandka Medical College Larkana

Dr. Shahid Jamal Siddiqui
Professor & Chairman
Department of Ophthalmology
Chandka Medical College Larkana

Dr. Safdar Ali Abbasi
Registrar
Department of Ophthalmology
Chandka Medical College Larkana

Dr. Dure Yakta Shaikh
Assistant Professor
Department of Ophthalmology
Chandka Medical College Larkana

Role of Authors

Dr. Syed Imtiaz Ali Shah
Substantial contribution to conception and design, acquisition of data, analysis and interpretation of data for intellectual content.

Dr. Shujaat Ali Shah
Drafted and revised the manuscript, reviewed the figures, contributed to conception and design, acquisition of data, analysis and interpretation of data.

Dr. Partab Rai
Contributed to acquisition of data, analysis and interpretation of data and final approval of the study for publication.

Dr. Shahid Jamal Siddiqui
Revised the study critically and contributed to acquisition of data.

Dr. Safdar Ali Abbasi
Reviewed the manuscript and contributed to acquisition of data.

Dr. Dure Yakta Shaikh
Contributed to acquisition of data.

REFERENCES

1. **Cairns JE.** Trabeculectomy, preliminary report of a new method. *Am J Ophthalmol.* 1968; 66: 673-9.
2. **Al Habash A, Aljasim LA, Owaidhah O, Edward DP.** A review of the efficacy of mitomycin C in glaucoma filtration surgery. *Clin Ophthalmol.* 2015; 9: 1945-51.
3. **Ali M, Akhtar F.** Ocular digital massage for the management of post-trabeculectomy under filtering blebs. *J Coll Physicians Surg Pak.* 2011; 21: 676-9.
4. **Hitchings RA, Grierson I.** Clinico pathological correlation in eyes with failed fistulizing surgery. *Trans Ophthalmol Soc UK.* 1983; 103: 84-8.
5. **Addicks EM, Quigley HA, Green WR, Robin AL.** Histologic characteristics of filtering blebs in glaucomatous eyes. *Arch Ophthalmol.* 1983; 101: 795-8.
6. **Migdal C, Gregory W, Hitchings R.** Long-term functional outcome after early surgery compared with laser and medicine in open-angle glaucoma. *Ophthalmology.* 1994; 101: 1651-7.
7. **Hoskins HD Jr, Migliazzo C.** Management of failing filtering blebs with the Argon laser. *Ophthalmic Surg.* 1984; 15: 731-3.
8. **Azuara-Blanco A, Katz LJ.** Dysfunctional filtering blebs. *Surv Ophthalmol.* 1998; 43: 93-126.
9. **Zhou M, Wang W, Huang W, Zhang X.** Trabeculectomy with versus without releasable sutures for glaucoma: a meta-analysis of randomized controlled trials. *BMC Ophthalmol.* 2014; 14: 41.
10. **Matlach J, Hoffmann N, Freiberg FJ, Grehn F, Klink T.** Comparative study of trabeculectomy using single sutures versus releasable sutures. *Clin Ophthalmol.* 2012; 6: 1019-27.
11. **Vijaya L, Manish P, Ronnie G, Shantha B.** Management of complications in glaucoma surgery. *Ind J Ophthalmol.* 2011; 59: 131-40.
12. **Hiroshi K, Kaori K.** A Comparison of the Intraocular Pressure Lowering Effect of Adjustable Suture Versus Laser Suture Lysis for Trabeculectomy. *J Glaucoma.* 2011; 20: 228-33.
13. **Lieberman MF.** Suture lysis by laser and gonioscopy. *Am J Ophthalmol.* 1983; 95: 257-8.
14. **Mostafaei A.** Augmenting trabeculectomy in glaucoma with subconjunctival mitomycin C versus subconjunctival 5-fluorouracil: a randomized clinical trial. *Clin Ophthalmol.* 2011; 5: 491-4.
15. **Lin Z-J, Li Y, Cheng J-W, Lu X-H.** Intraoperative Mitomycin C Versus Intraoperative 5-Fluorouracil for Trabeculectomy: A Systematic Review and Meta-Analysis. *J Ocular Pharmacol Ther.* 2012; 28: 166-73.
16. **Chawla A, Mercieca K, Fenerty C, Jones NP.** Outcomes and complications of trabeculectomy enhanced with 5-fluorouracil in adults with glaucoma secondary to uveitis. *J Glaucoma.* 2013; 22: 663-6.
17. **Anand N, Dawda VK.** A Comparative Study of Mitomycin C and 5-Fluorouracil Trabeculectomy in West Africa. *Mid East Afr J Ophthalmol.* 2012; 19: 147-52.
18. **Shen CC, Salim S, Du H, Netland PA.** Trabeculectomy versus Ahmed Glaucoma Valve implantation in neovascular glaucoma. *Clin Ophthalmol.* 2011; 5: 281-6.
19. **Gessesse GW.** The Ahmed glaucoma valve in refractory glaucoma: experiences in southwest ethiopia. *Ethiop J Health Sci.* 2015; 25: 267-72.
20. **Downes SM, Mission GP, Jones HS, O'Neill EC.** The predictive value of post-operative intraocular pressures following trabeculectomy. *Eye.* 1994; 8: 394-7.
21. **Macken P, Buys Y, Trope GE.** Glaucoma laser suture lysis. *Br J Ophthalmol.* 1996; 80: 398-401.
22. **Sng CC, Singh M, Chew PT, Ngo CS, Zheng C, Tun TA.** Quantitative assessment of changes in trabeculectomy blebs after laser suture lysis using anterior segment coherence tomography. *J Glaucoma.* 2012; 21: 313-7.
23. **Haynes WL, Alward WL, McKinney JK.** Low-energy argon laser suture lysis after trabeculectomy. *Am J Ophthalmol.* 1994; 117: 800-1.
24. **Bardak Y, Cuyppers MH, Tilanus MA, Eggink CA.** Ocular hypotony after laser suture lysis following trabeculectomy with mitomycin C. *Int Ophthalmol.* 1997-98; 21: 325-30.
25. **Schwartz AL, Weiss HS.** Bleb leak with hypotony after laser suture lysis and trabeculectomy with mitomycin C. *Arch Ophthalmol.* 1992; 110: 1049.