

Ocular Manifestations and Viral Prevalence in Conjunctival Secretions of Patients with COVID 19 – A Meta-Analysis

Ayisha Shakeel¹, Sharjeel Sultan², Syed Imtiaz Ali³

¹⁻³*Al Nafees Medical College and Hospital, Isra University, Islamabad, ²Dow University of health sciences, Karachi*

ABSTRACT

PubMed was searched using key words “COVID-19”, “coronavirus”, and “SARS CoV-2” in conjunction with “ophthalmology” and “eye” on 17th May 2020. Total 483 articles were identified. After screening eleven articles were included in the analysis. The frequencies of ocular manifestations and the presence of virus in conjunctiva were analyzed and the final results were compiled. Ten out of eleven articles were analyzed for ocular manifestations. In our analysis a total of 2115 cases had Covid 19, out of which 77 patients developed ocular manifestations (3.64%, 95% CI 2.88 – 4.53). The most common being conjunctival congestion. Twelve patients had SARS – CoV-2 in their ocular secretions confirmed by RT PCR test (2.61%, 95% CI 1.36 – 4.52). This meta-analysis concludes that conjunctiva is neither a preferred site of infection nor a preferred gateway for entry of SARS CoV-2 in the body. As a low risk of infection does exist, eye protective equipment should be used when treating COVID – 19 patients.

Key Words: SARS CoV 2, COVID 19, Conjunctiva, Ophthalmology.

How to Cite this Article: Ocular Manifestations and Viral Prevalence in Conjunctival Secretions of Patients with COVID 19 – A Meta – Analysis. *Pak J Ophthalmol.* 2020; **36 (4):** 433-439.

Doi: <https://doi.org/10.36351/pjo.v36i4.1126>

INTRODUCTION

Human race since its existence has been threatened by many deadly pandemics. The most recent pandemic caused by a corona virus has very quickly spread through the entire world and has affected millions of individuals.¹ Since its beginning earlier this year there have been more than 4.6 million confirmed cases and around 300000 deaths worldwide.² Corona viruses are single stranded RNA enveloped viruses. They were first identified in 1960s and were considered to cause mild flu like symptoms in humans until more recently

since the emergence of SARS CoV in 2002 and MERS CoV in 2012. The latter two viruses can cause severe lower respiratory tract infection proceeding to pneumonia and even death.³ The latest pandemic is caused by a novel corona virus now named as SARS CoV2. Like its predecessors, it can cause a highly infectious pneumonia called corona virus disease or COVID 19. The SARS CoV-2 has a mortality much lower than the mortality of SARS CoV and MERS CoV but it is considered to be more contagious.^{4,5}

Interest of ophthalmology began in this disease since the first doctor to notice this different kind of flu was an ophthalmologist. Dr Li Wenliang was working in Wuhan, China when he noticed these patients. He unfortunately contracted the disease from one of his patients and died later on.⁶ Since then, two more ophthalmologists have died in Wuhan due to occupational exposure and a pulmonologist developed conjunctivitis while treating his patients. The only

Correspondence: Ayisha Shakeel

Al Nafees Medical College and Hospital, Isra University, Islamabad

Email: ayishashakeel@gmail.com

Received: September 3, 2020

Accepted: September 6, 2020

exposed part of his face were his eyes thus leading to the speculation that ocular entry could be the cause of infection.⁵ Due to close proximity to the patients as a job requirement, ophthalmologists are at greater risk of catching or transmitting the disease.⁷ Since then many studies and case reports have been published with involvement of eyes of COVID 19 patients.^{8,9,10} The most common ocular symptoms were hyperemia, chemosis, lacrimation and increased secretion while none of the patient experienced blurred vision.¹¹

The SARS CoV-2 spreads through respiratory droplets and by direct contact with virus contaminated fomites.¹² Eye due to exposure to the environment can come in contact with these virus particles. The virus has been sequenced and is found to be 75 – 80% similar to SARS CoV and 40% similar to MERS CoV.¹³ It is therefore possible that SARS CoV-2 shares the same mechanism to gain access in the human cells. The virus gains entry into human cells by binding to certain proteins on the cell surface. Two of such key proteins, Angiotensin converting enzyme 2 (ACE 2) and transmembrane serine protease 2 (TMPRSS 2) are the key proteins for entry in host cells. Animal models have shown that in the eye their highest expression is in conjunctiva and cornea.¹⁴ ACE 2 and TMPRSS 2 are found in human conjunctival cells and corneal limbal stem cells. ACE 2 are also present in other parts of the eye like trabecular meshwork, aqueous humor, iris, ciliary body, non-pigmented ciliary epithelium, and retina.¹⁵ Human eye is also connected to the nasopharynx by the constant draining of tears through the nasolacrimal duct. It is therefore, possible that there may be two routes of entry of virus through the eye. One is by binding to the ocular surface cells and the other is by being drained into the nasopharynx with tears.¹⁶ Although the possibility of spread exists, the eyes are rarely involved in COVID 19.¹⁷ This suggests that the eye is neither a preferred organ for human Coronavirus infection nor a preferred gateway of entry that enables human Coronaviruses to infect the respiratory tract.¹²

Since the emergence of this disease, a lot of information is coming up on daily basis about COVID 19 and its involvement of the eye. In ophthalmology, the main focus is on two things. Firstly, the ocular manifestations of COVID 19 and secondly how is the eye involved in transmission and infection of this disease. A number of studies have come up in literature to answer these questions with varying opinions. In this paper, we try to sum up the findings

of literature by performing a systematic review and meta-analysis with special focus on ocular manifestations and presence of virus in the conjunctiva of patients with possible transmission through the eye.

The objective of this analysis was to find out the ocular manifestations of COVID – 19 and presence of virus in the conjunctival secretions of these patients.

METHODS

This meta-analysis was carried out according to the fundamentals laid in the Preferred Reporting Items for Systematic reviews and Meta-Analysis (PRISMA) statement.¹⁸ The objective of this analysis was to find out the ocular manifestations of COVID19 and presence of virus in the conjunctival secretions of these patients.

In the meta-analysis only comparative studies (both prospective and retrospective observational studies) and Randomized controlled trials since the start of corona virus pandemic till 17th May 2020 were included. The participants in all these studies were laboratory confirmed COVID – 19 patients. Ocular symptoms of conjunctival hyperemia, discharge, watering, foreign body sensation, itching and chemosis were all included. Reverse transcriptase- polymerase chain reaction test (RT-PCR) was performed on the conjunctival swabs of all patients with ocular symptoms for presence of SARS – CoV-2.

PubMed database was searched for relevant articles using the keywords “COVID – 19”, “coronavirus”, and “SARSCoV-2” in conjunction with “ophthalmology” and “eye”. A total of 483 articles were identified through database searching till 17th May 2020. However, by following the flow diagram of PRISMA guidelines for meta-analysis, 97 articles were identified after removal of duplicates and irrelevant articles. Further screening removed 41 more articles (editorials, communication, case reports, case series) leaving 56 behind to be assessed for eligibility. These full text articles were then assessed for eligibility under the criteria set in the beginning of the article. Thirty-one did not fulfill the criteria and were removed leaving behind 25 articles for qualitative analysis. The results of these articles were assessed and out of these articles, 11 articles were included for meta-analysis. The whole process is shown in Fig. 1.

For statistical data analysis, frequencies were calculated in terms of percentages to identify the most

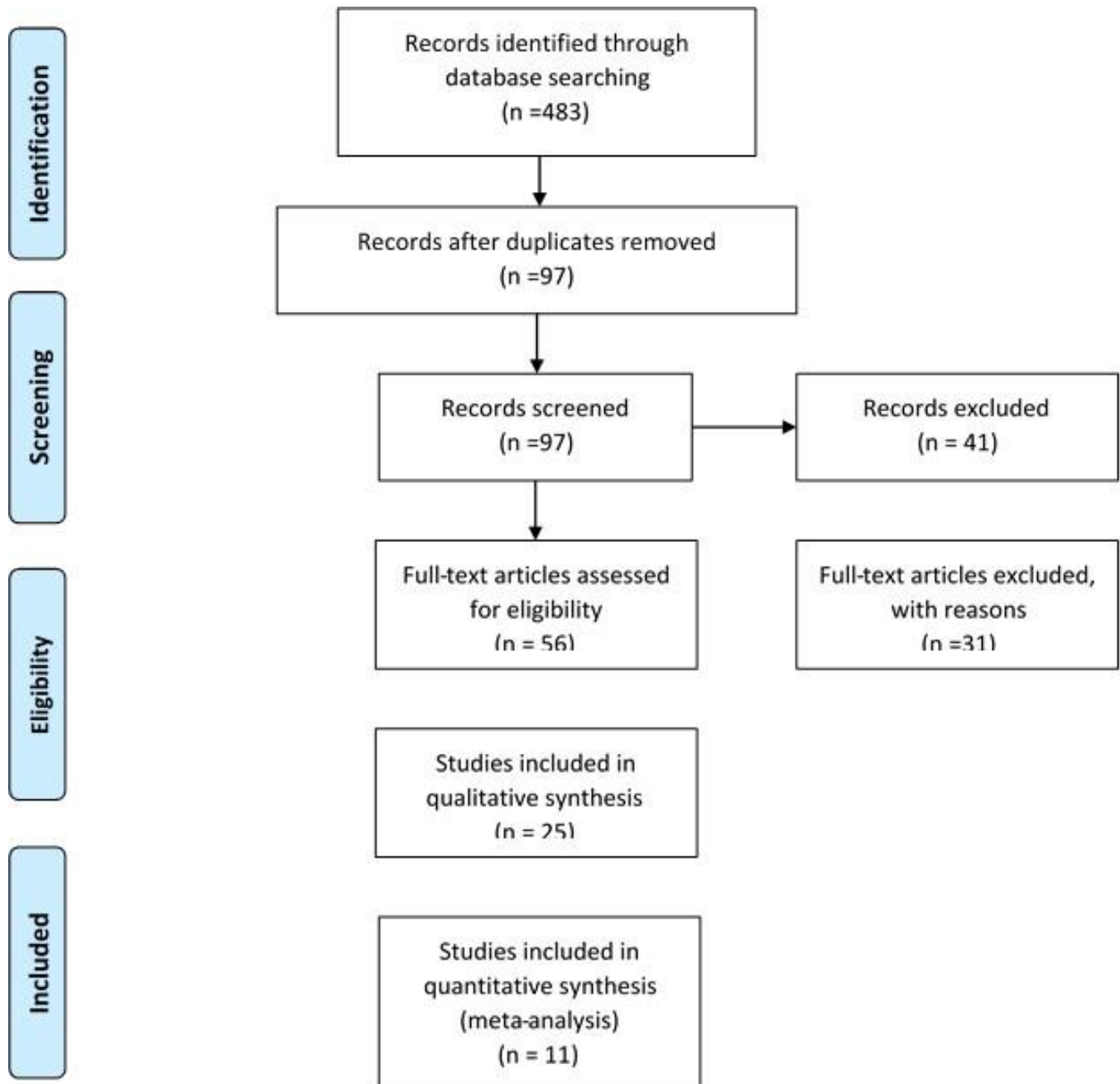


Fig. 1: Flow Chart.

common ocular manifestations and presence of virus in the conjunctiva of patients based upon which, final conclusions were drawn.

RESULTS

After following the guidelines of PRISMA for meta-analysis a total of 11 articles were finally included in the meta-analysis. Based on the available data ten

articles were included to analyze the ocular manifestations in patients with COVID – 19, while eight articles were included to assess the prevalence of virus in ocular secretions in such patients (table 1).

The ten studies analyzed for ocular manifestations had a total of 2115 confirmed cases of COVID 19. Out of the total 2115 confirmed cases, 77 patients developed ocular manifestations (3.64%, 95% CI 2.88 – 4.53) of different kind. The most common

ocular manifestations were conjunctival congestion (09 studies) followed by increased secretions (7 studies), itching (4 studies), foreign body sensation (2 studies), dry eyes (2 studies), chemosis, blurred vision and floaters (1 study each). For details see table 2.

The eight studies analyzed for prevalence of virus in ocular secretions had a total of 459 confirmed cases of COVID – 19. Out of the total 459 confirmed cases, 12 patients had SARS-CoV 2 in their ocular secretions confirmed by RT PCR test (2.61%, 95% CI 1.36 – 4.52). Table 3 shows the details.

Table 1: Studies Included in Meta-analysis.

Author	Type of Study	Sample Size	Age	Gender (M, F)	Patients with Ocular Manifestations	Patients with Positive Conjunctival Secretion
Yunyun Zhou et al ¹⁹	Retrospective	67	35.7 ± 10.6	25, 42	1	3
Nang Hong et al ²⁰	Cross sectional	56	48 ± 21.1	31, 25	15	-
Ping Wu et al ¹¹	Retrospective	38	65.8 ± 16.6	25, 13	12	2
Wei-Jie Guan et al ¹⁷	Retrospective	1099	47 (35 – 58)	58.1%, 41.9%	9	-
Jianhua Xia et al ²¹	Interventional case series	30	54.5 ± 14.17	27, 3	1	1
Xian Zhang et al ²²	Cross sectional	72	58.68 ± 14.81	36, 36	2	1
Yunyun Zhou et al ²³	Cross sectional	121	48	53, 68	8	3
Lan Qianqian et al ²⁴	Prospective	81	41.69 ± 18.6	33, 48	3	0
Ivan Yu Jun Seah et al ²⁵	Prospective	17	-	-	1	0
Hua-Tao Xie et al ²⁶	Retrospective	33	57.6 ± 14	22, 11	-	2
Liwen Chen et al ²⁷	Cross sectional	534	45	260, 274	25	-

Table 2: Studies Included in Analysis of Ocular Manifestations in COVID – 19 Patients.

Author	Type of Study	Sample Size	Age	Gender (M, F)	No of Patients with Ocular Manifestations	Percentage of Ocular Symptom	95% CI
Yunyun Zhou et al ¹⁹	Retrospective	67	35.7 ± 10.6	25,42	1	1.49%	0.04 – 8.04
Nang Hong et al ²⁰	Cross sectional	56	48 ± 21.1	31, 25	15	26.79%	15.83 – 40.3
Ping Wu et al ¹¹	Retrospective	38	65.8 ± 16.6	25, 13	12	31.58%	17.5 – 48.65
Wei-Jie Guan et al ¹⁷	Retrospective	1099	47 (35 – 58)	58.1%, 41.9%	9	0.82%	0.38 – 1.55
Jianhua Xia et al ²¹	Prospective	30	54.5 ± 14.17	27, 3	1	3.33%	0.08 – 17.22
Xian Zhang et al ²²	Cross sectional	72	58.68 ± 14.81	36, 36	2	2.78%	0.34 – 9.68
Yunyun Zhou et al ²³	Cross sectional	121	48	53, 68	8	6.61%	2.91 – 12.61
Lan Qianqian et al ²⁴	Prospective	81	41.69 ± 18.6	33, 48	3	3.70%	0.77 – 10.4
Ivan Yu Jun Seah et al ²⁵	Prospective	17			1	5.80%	0.15 – 28.65
Liwen Chen et al ²⁷	Cross sectional	534	45	260,274	25	4.68%	3.05 – 6.83
Total Patients		2115			77	3.64	2.88 – 4.53

Table 3: Studies with SARS – CoV-2 in Ocular Secretions.

Author	Type of Study	Sample Size	Age	Gender M, F	No of patients with SARS CoV2 in Conjunctival Secretions	% Age of Ocular Symptoms	95% CI
Ping Wu et al ¹¹	Retrospective	38	65.8 ± 16.6	25, 13	2	5.26%	0.64 – 1.77
Yunyun Zhou et al ¹⁹	Retrospective	67	35.7 ± 10.6	25, 42	3	4.48%	0.093 – 12.5
Jianhua Xia et al ²¹	Prospective	30	54.5 ± 14.17	27, 3	1	3.33%	0.08 – 17.22
Xian Zhang et al ²²	Cross sectional	72	58.68 ± 14.8	36, 36	1	1.39%	0.03 – 7.5
Yunyun Zhou et al ²³	Cross sectional	121	48	53, 68	3	2.48%	0.51 – 7.07
Lan Qianqian ²⁴	Prospective	81	41.69 ± 18.6	33, 48	0	0.00%	0 – 4.45
Ivan Yu Jun Seah et al ²⁵	Prospective	17			0	0.00%	0 – 19.5
Hua-Tao Xie et al ²⁶	Retrospective	33	57.6 ± 14	22, 11	2	6.06%	0.74 – 20.23
Total patients		459			12	2.61%	1.36 – 4.52

DISCUSSION

The results of this meta-analysis shows that overall 3.64% (95% CI 2.88 – 4.53) patients with COVID – 19 presented with ocular manifestations. This is slightly higher than another meta-analysis by Loffredo et al in which 1.1% patients of COVID 19 had ocular manifestations.²⁸ The reason could be that the number of studies in our meta-analysis were ten as compared to only three in the other meta-analyses. With more and more studies being published the rate and manifestations of the disease will change. Loffredo et al has also mentioned two groups of patients with COVID – 19 and the rate of ocular manifestations in patients with severe disease was 3%. The rate of ocular manifestations in COVID 19 patients has varied among individual studies. Initial studies by Huang, Chan and Chen from Wuhan did not mention any ocular manifestations at all.^{29,30,31} Later on multiple studies emerged which mentioned ocular manifestations as symptoms of COVID – 19. A study by Guan et al with a sample size of 1099 patients mentioned ocular manifestations in only 0.82% (95%CI 0.38 – 1.55) of the patients.¹⁷ On the contrary, a retrospective analysis of 38 patients by Wu et al reported ocular manifestations as high as 31.8% (95% CI 17.5 – 48.65).¹¹ As COVID – 19 is a new disease and humanity is battling with its effect on the human body, it is not surprising that we will find different features in different reports.

The most common ocular manifestation in our analysis was conjunctival congestion, which was present in 82% of our studies. This was followed by increased ocular secretions which was mentioned in 64% of our studies. The next most common manifestations were itching and ocular discomfort or foreign body sensation in around 36% of our studies. Dry eye was another manifestation, which the patients had experienced in 18% of our analyzed studies. The least common ocular manifestations were chemosis, floaters and blurred vision, which were mentioned in only one out of eleven studies (9%). Most of the studies except one did not mention reduced or blurred vision as an ocular manifestation of COVID – 19. These findings were almost similar to the reported literature on ocular manifestations of COVID – 19 in which conjunctival congestion, hyperemia, increased tearing and foreign body sensations were the most common manifestations in the eye. In a case report from France by Navel et al the patient presented with hemorrhagic conjunctivitis with pseudo membranes.⁸

In another case report by Chen et al a patient developed redness, foreign body sensation and tearing during the course of the disease.⁹ A case report by Cheema et al from Canada mentioned conjunctivitis as the primary presentation of COVID – 19.¹⁰ Another report by Daruich et al also mentioned ocular redness and foreign body sensation as the primary presentation of the disease.³² Corona viruses have been reported to cause retinal vasculitis, retinal degeneration and breakdown of blood retinal barriers in animal models in the past.³³ The SARS CoV-2 virus uses ACE2 receptors to get attached to the host cells and ACE 2 receptors have been identified in human retina. Therefore, the possibility of retinal manifestation exists in COVID – 19. A recent case series reported some retinal findings in the patients of COVID 19 possibly due to SARS-CoV-2.³⁴ As case reports were excluded from this analysis, these diverse retinal findings could not be found in these cross sectional and retrospective studies. Further studies are required to fully understand the spectrum of ocular manifestations in COVID – 19 patients.

In this meta-analysis we also looked into the presence of SARS CoV-2 virus in ocular secretions. Out of the eleven studies, eight studies analyzed ocular secretions for the presence of SARS CoV-2 by RT PCR tests. In these studies, a total of 459 patients with confirmed COVID – 19 were analyzed. Out of these, 12 were found to have SARS CoV-2 in their ocular secretions (2.61%, 95% CI 1.36 – 4.52). Two of the studies in this meta-analysis did not show viral shedding in ocular secretions at all.^{24,25} The highest rate of viral shedding in ocular secretions was in a study by Xie et al which was 6.06%.²⁶ As the knowledge about the disease is evolving the varying rates of viral shedding is not surprising. Respiratory-related public health events, such as SARS, were reported to be associated with ophthalmology.³⁵ Corona virus or Ebola virus had been detected in the tears of patients with SARS and Ebola.³⁶ A case report by Hu et al detected not only SARS CoV-2 but also HSV1 and HHV6B in ocular secretions 2 weeks after the nasopharyngeal swab became negative.³⁷ This was not found in the studies under review.

Shedding of virus in the ocular secretions of patients who does not have conjunctivitis pose a public health risk of transmission. An article by Liu et al mentioned that ocular route is not the preferred route for virus transmission and respiratory route was the most preferred route.³⁸ Although it seems, at the

moment, that there is a low risk of coronavirus spreading through tears, it may survive for a long time or replicate in the conjunctiva, even in the absence of conjunctivitis signs, indicating that eye protection (e.g., protective goggles alone or in association with face shield) is advisable to prevent contamination from external droplets and aerosol.

CONCLUSION

The current analysis indicate that Ocular manifestations are not very common in patients with COVID-19. This meta-analysis concludes that conjunctiva is neither a preferred site of infection nor a preferred gateway for entry of SARS CoV-2 in the body. As a low risk of infection does exist, eye protective equipment should be continued when treating COVID-19 patients.

Conflict of Interest

None to declare.

Funding Disclosure

None to declare.

REFERENCES

1. **Cucintta D, Vanelli M.** WHO Declares COVID-19 a Pandemic. *Acta Biomed.* 2020; **91 (1)**: 157-160.
2. Covid19.who.int. World Health Organization. Available from: <https://covid19.who.int/> (Assessed: May 17, 2020).
3. **Belser JA, Rota PA, Tumpey TM.** Ocular Tropism of Respiratory Viruses. *Microbiol Mol Biol R.* 2013; **77 (1)**: 144-156.
4. **Zheng J.** SARS-CoV-2: an Emerging Coronavirus that Causes a Global Threat. *Int J Biol Sci.* 2020; **16 (10)**: 1678-1685.
5. **Yu AY, Tu R, Shao X, Pan A, Zhou K, Huang J.** A comprehensive Chinese experience against SARS-CoV-2 in ophthalmology. *Eye and Vision,* 2020; **7 (19)**. <https://doi.org/10.1186/s40662-020-00187-2>
6. **Parrish RK 2nd, Stewart MW, Duncan PSL.** Ophthalmologists Are More Than Eye Doctors-In Memoriam Li Wenliang. *Am J Ophthalmol.* 2020; **213**: A1-A2. Doi:10.1016/j.ajo.2020.02.014.
7. **Siedlecki J, Branti V, Schworm B, Mayer WJ, Gerhardt M, Michalakakis S et al.** COVID-19: Ophthalmological Aspects of the SARS-CoV 2 Global Pandemic. *Klin Monbl Augenheilkd.* 2020; **237 (5)**: 675-680. Doi: 10.1055/a-1164-9381.
8. **Navel V, Chiambaretta F, Dutheil F.** Haemorrhagic conjunctivitis with pseudomembranous related to SARS-CoV2. *Am J Ophthalmol Case Reports.* 2020; **19**: 100735. <https://doi.org/10.1016/j.ajoc.2020.100735>
9. **Chen L, Liu M, Zhang Z, Qiao K, Huang T, Chen M et al.** Ocular manifestations of a hospitalised patient with confirmed 2019 novel coronavirus disease. *Br J Ophthalmol.* 2020; **104 (6)**: 748-751. Doi:10.1136/bjophthalmol-2020-316304.
10. **Cheema M, Aghazadeh H, Nazarali S, Ting A, Hodges J, McFarlane A et al.** Keratoconjunctivitis as the initial medical presentation of the novel coronavirus disease 2019 (COVID-19). *Can J Ophthalmol.* 2020; **S0008-4182 (20)**: 30305-7. Doi: 10.1016/j.jcjo.2020.03.003.
11. **Wu P, Duan F, Luo C, Liu Q, Qu X, Liang L et al.** Characteristics of Ocular Findings of Patients with Coronavirus Disease 2019 (COVID-19) in Hubei Province, China. *JAMA Ophthalmol.* 2020; **138 (5)**: 575-578.
12. **Sun C, Wang Y, Liu G, Liu Z.** Role of the Eye in Transmitting Human Coronavirus: What we know and what we do not know. *Front. Public Health,* 2020. <https://doi.org/10.3389/fpubh.2020.00155>
13. **She J, Jiang J, Ye L, Hu L, Bai C, Song Y.** 2019 novel coronavirus of pneumonia in Wuhan, China: emerging attack and management strategies. *Clin Trans Med.* 2020; **9 (19)**: 1-7. <https://doi.org/10.1186/s40169-020-00271-z>
14. **Bining Z, Qun W, Ting L, Shengqian D, Xia Q, Hui J et al.** Expression analysis of 2019-nCoV related ACE2 and TMPRSS2 in eye tissues. *Zhonghua Yan Ke Za Zhi.* 2020; **56 (0)**: E011. Doi: 10.3760/cma.j.cn112142-20200310-00170.
15. **Holappa M, Vapaatalo H, Vaajanen A.** Many Faces of Renin – antiotensin System – Focus on Eye. *Open Ophthalmol J.* 2017; **11**: 122-142. Doi: 10.2174/1874364101711010122.
16. **Napoli PE, Nioi M, Aloja E, Fossarello M.** The Ocular Surface and the Coronavirus Disease 2019: Does a Dual ‘Ocular Route’ Exist? *J. Clin. Med.* 2020; 1269. Doi: 10.3390/jcm9051269.
17. **Guan W, Ni Z, Hu Y, Liang W, Ou C, He J et al.** Clinical Characteristics of Coronavirus Disease 2019 in China. *N Engl J Med.* 2020; **382**: 1708-1720. Doi: 10.1056/NEJMoa2002032.
18. **Moher D, Liberati A, Tetzlaff J, Altman DG.** The PRISMA Group. Preferred Reporting Items for Systematic Reviews and Meta-Analyses: The PRISMA Statement. *PLoS Med.* 2009; **6 (7)**: e1000097. Doi: 10.1371/journal.pmed1000097.
19. **Zhou Y, Zeng Y, Tong Y, Chen C.** Ophthalmologic evidence against the interpersonal transmission of 2019 novel coronavirus through conjunctiva. <https://doi.org/10.1101/2020.02.11.20021956>

20. **Hong N, Yu W, Xia J, Shen Y, Yap M, Han W.** Evaluation of ocular symptoms and tropism of SARS-CoV-2 in patients confirmed with COVID-19. *Acta Ophthalmol.* 2020; **10**: 1111/aos.14445. Doi: 10.1111/aos.14445.
21. **Xia J, Tong J, Liu M, Shen Y, Guo D.** Evaluation of coronavirus in tears and conjunctival secretions of patients with SARS-CoV-2 infection. *J Med Virol.* 2020; **92** (6): 589-594. Doi: 10.1002/jmv.25725.
22. **Zhang X, Chen X, Chen L, Deng C, Zou X, Liu W.** The evidence of SARS-CoV-2 infection on ocular surface. *Ocul Surf.* 2020; **18** (3): 360-362. Doi: 10.1016/j.jtos.2020.03.010.
23. **Zhou Y, Duan C, Zeng Y, Tong Y, Nie Y, Yang Y et al.** Ocular findings and proportion with conjunctival SARS-CoV-2 in COVID-19 patients. *Ophthalmology.* 2020; **127** (7): 982-983. Doi: 10.1016/j.ophtha.2020.04.028.
24. **Lan QQ, Zeng SM, Liao X, Qi H, Li M.** Screening for novel coronavirus related conjunctivitis among the patients with corona virus disease-19. *Zhonghua Yan Ke Za Zhi.* 2020; **56** (0): E009. Doi: 10.3760/cma.j.cn112142-20200322-00213.
25. **Seah IYJ, Anderson DE, Kang AEZ, Wang L, Rao P, Young BE.** Assessing Viral Shedding and Infectivity of Tears in Coronavirus Disease 2019 (COVID-19) Patients. *Ophthalmology.* 2020; **127** (7): 977-979.
26. **Xie HT, Jiang SY, Xu KK, Liu X, Xu B, Wang Lin et al.** SARS-CoV-2 in the ocular surface of COVID-19 patients. *Eye Vis (Lond).* 2020; **7**: 23. Doi: 10.1186/s40662-020-00189-0.
27. **Chen L, Deng C, Chen X, Zhang X, Chen B, Yu H et al.** Ocular manifestations and clinical characteristics of 534 cases of COVID-19 in China: A cross sectional Study. *Med Rxiv.* 2020.03.12.20034678. <https://doi.org/10.1101/2020.03.12.20034678>
28. **Loffredo L, Pacella F, Pacella E, Tiscione G, Oliva A, Violi F.** Conjunctivitis and COVID-19: A meta-analysis. *J Med Virol.* 2020; 10.1002/jmv.25938. Doi: 10.1002/jmv.25938.
29. **Huang C, Wang Y, Li X, Ren L, Zhao J, Hu Y.** Clinical features of patients infected with 2019 novel coronavirus in Wuhan, China. *Lancet.* 2020; **395**: 497-506.
30. **Chan JFW, Yuan S, Kok KH, To KKW, Chu H, Yang J et al.** A familial cluster of pneumonia associated with the 2019 novel coronavirus indicating person to person transmission: a study of a family cluster. *Lancet.* 2020; **395**: 514-523.
31. **Chen N, Zhou M, Dong X, Qu J, Gong F, Han Y et al.** Epidemiological and clinical characteristics of 99 cases of 2019 novel coronavirus pneumonia in Wuhan, China: a descriptive study. *Lancet.* 2020; **395**: 507-513.
32. **Daruich A, Martin D, Gignac DB.** Ocular manifestation as first sign of Coronavirus Disease 2019 (COVID-19): Interest of telemedicine during the pandemic context. *J Fr Ophthalmol.* 2020; **43** (5): 389-391.
33. **Seah I, Agrawal R.** Can the coronavirus disease 2019 (COVID-19) affect the eyes? A review of coronaviruses and ocular implications in humans and animals. *Ocul Immunol Inflamm.* 2020; **28**: 391-395.
34. **Marinho PM, Marcos AAA, Romano AC, Nascimento H, Belfort R Jr.** Retinal findings in patients with COVID-19. *Lancet.* 2020; **395** (10237): 1610. Doi: 10.1016/S0140-6736(20)31014-X.
35. **Loon SC, Teoh SCB, Oon LLE, Se-Thoe SY, Ling AE, Leo YS.** The severe acute respiratory syndrome coronavirus in tears. *BJO.* 2004; **88**: 861-863.
36. **Bausch DG, Towner JS, Dowell SF, Kaducu F, Lukwiya M, Sanchez A.** Assessment of the Risk of Ebola Virus Transmission from Bodily Fluids and Fomites. *JID.* 2007; **196** (Suppl 2): S142-S147.
37. **Hu Y, Chen T, Liu M, Zhang L, Wang F, Zhao S, et al.** Positive detection of SARS-CoV-2 combined HSV1 and HHV6B virus nucleic acid in tear and conjunctival secretions of a non-conjunctivitis COVID-19 patient with obstruction of common lacrimal duct. *Acta Ophthalmol.* 2020; 10.1111/aos.14456. [published online ahead of print, 2020 May 14]. Doi: 10.1111/aos.14456.
38. **Liu Z, Sun CB.** Conjunctiva is not a preferred gateway of entry for SARS-CoV-2 to infect respiratory tract *J Med Virol.* 2020; 10.1002/jmv.25859. [published online ahead of print, 2020 Apr 10]. Doi: 10.1002/jmv.25859.

Author's designation and contribution

Ayisha Shakeel; Assistant Professor: *Concepts, Design, Literature research, Data acquisition, Data analysis, Statistical analysis, Manuscript preparation, Manuscript editing, Manuscript review*

Sharjeel Sultan; Assistant Professor: *Design, Literature research, Data acquisition, Statistical analysis, Manuscript preparation*

Syed Imtiaz Ali; Professor: *Concepts, Design, Data analysis, Manuscript preparation, Manuscript review.*

