

Extraction of broken intramedullary nail in ununited fractures of femur by doubling up the tip of guide wire: An innovative technique

Arun Vashisht^{1,*}, OP Gupta², Avinash Rastogi³

^{1,3}Associate Professor, ²Assistant Professor, Dept. of Orthopaedics, Subharti Medical College, Meerut, Uttar Pradesh

***Corresponding Author:**

Email: drarunvst@gmail.com

Abstract

Femoral shaft fractures are treated by close intramedullary interlocking nailing, that allows early ambulation and preservation of fracture haematoma. But a good number of patients present with disturbed union and broken nail. Extraction of the broken nail, especially of its distal segment, is quite challenging without opening and disturbing the fracture site. We describe an innovative technique of broken nail extraction with the help of a doubled up tip guide wire and a cannulated extractor. 12 patients with broken nails were subjected to our technique by first passing a guide wire through the broken nail up to the subchondral bone and then advancing through intercondylar notch into the flexed knee and then exiting the wire out of knee by a small incision. Tip of the exited wire is then doubled up over itself like a loop, so that it may behave like a ball tipped wire. A cannulated extractor is threaded over the proximal part of the wire and screwed into the proximal end of the broken nail, which is then extracted. All broken nails were extracted easily. No patient developed heamarthrosis or compromise in knee function. No sign of early or delayed knee infection was seen. The mean follow up period was 15.4(range18-24) months. We found this innovative technique simple, safe, inexpensive, requiring no sophisticated instrumentation and steep learning curve.

Keywords: Extraction, Broken nail, Innovative.

Access this article online

Website:

www.innovativepublication.com

DOI:

10.5958/2348-7682.2016.00006.3

Introduction

The femoral shaft fractures are of common occurrence in young adults due to high energy trauma in road traffic accidents. The concept of intramedullary fixation of femoral shaft fractures is time tested since the advent of Kuntscher's intramedullary nailing. But after the introduction of interlocking intramedullary nails, close nailing became the treatment of choice for majority of the diaphyseal fractures of femur due to biomechanical advantages over plate osteosynthesis⁽¹⁻²⁾. Advantages of early mobilization of the adjacent joints, early ambulation with walker or crutch support are the main attractions of close detention nailing without violation of the fracture haematoma during surgery, which is essential for union. But despite that, a good number of cases of disturbed union are encountered during follow up of these fractures, the causes of which, though, may be multifactorial, but the most common causative factor appears to be premature and over enthusiastic weight bearing that too without walking aids.

Disturbed union of femoral shaft fractures after nailing is potentially a serious complication, which if not taken care well in time, will ultimately lead to either nonunion or fatigue failure of the implant. The

management of disturbed union may require dynamization alone, autogenous bone grafting, or exchange nailing with or without bone grafting, but management of disturbed union with broken nail is a little bit challenging in terms of extraction of the broken nail without opening and disturbing the fracture site. Though a battery of instruments and techniques have been developed for the extraction of the broken nail using hooks, olive wires, long grabbers etc.⁽³⁻¹³⁾, but because of the difficulty of their easy availability everywhere and a higher cost, it often becomes necessary to open the fracture site to extract the distal portion of the nail. This brought forth the need to evolve a simple technique for the extraction of the broken nail. We, at our institution, developed an innovative technique for the same, which is simple, safe and inexpensive, by using a standard guide wire and a cannulated extractor only (Fig. 1), and we could extract broken nails easily through this technique in 12 patients.

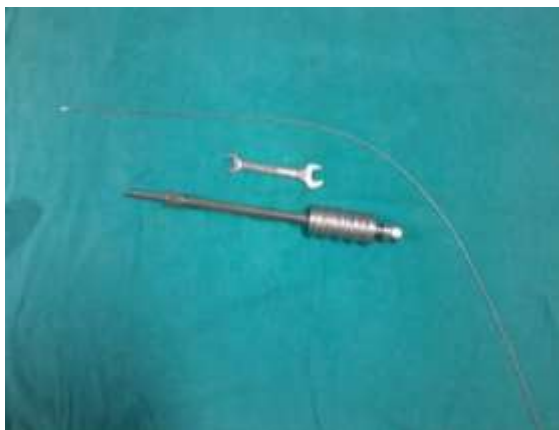

Fig. 1: A standard guide wire and a cannulated extractor

Material and Method

In this prospective study of 3 years from March 2012 to February 2015, conducted in department of Orthopaedics, Subharti Medical college, Swami Vivekanand Subharti University, Meerut, twelve patients aged between 26 to 47 years, all male, who were treated initially by interlocking intramedullary nailing for fracture shaft of femur but presenting with disturbed union and broken femoral nail in the follow up, after obtaining approval from Institutional Ethics Committee, were included. All these patients were counseled about the technique of extraction of the broken nail by passing a wire through the knee joint, followed by exchange nailing with one size larger nail, and an informed consent was obtained regarding the same.

Technique: After the spinal anaesthesia, the patient is laid supine over the fracture Table. The limb is prepared and draped from umbilicus to the distal 1/3rd of the leg. The greater trochanter is exposed by longitudinal incision through the previous scar. The proximal interlocking bolts are removed by giving small incisions, the guide wire is then passed inside the nail and is negotiated in the distal broken portion of the nail, with some outside manual manipulation of the ununited fracture if at all required due to any angulation, up to the level of the distal interlocking bolts under C-arm control. Now the distal bolts are removed by giving small skin incisions. The guide wire is then pushed distally up to the subchondral bone. At this point of time the leg is disengaged from the foot holder of the fracture table and wrapped into a separate sterile sheet and knee is flexed to 90° while the thigh is supported by one of the assistant. The guide wire is then advanced further distally to penetrate into the knee joint through an area of non-weight bearing articular cartilage in the intercondylar notch of femur, till it comes to lie under the skin after penetrating through the patellar tendon. An incision of about 1 to 1.5cm is made over the tip of the wire to exit it out of the skin, which

is then pushed further about 2-3cm out of the skin (Fig. 2, 3a, 3b).

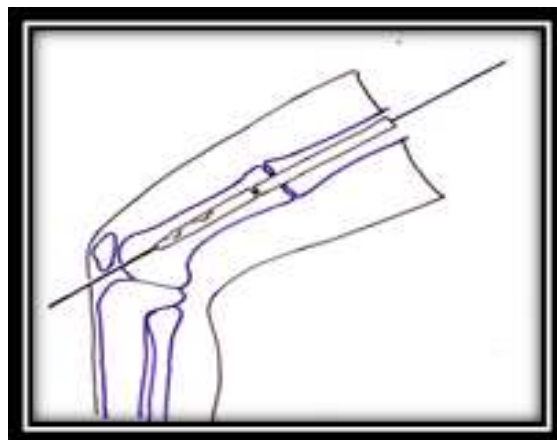


Fig. 2: A sketch depicting the guide wire

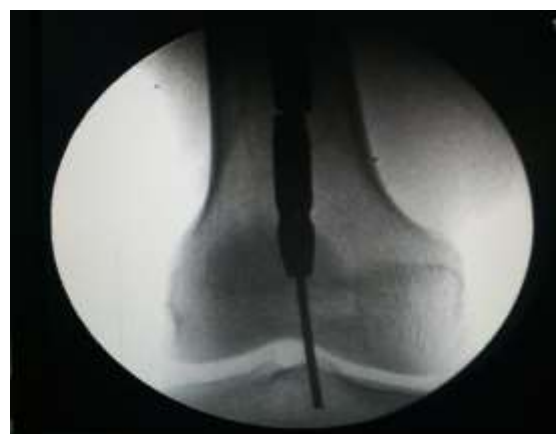

Fig. 3(a): A C-arm AP image of exiting the guide wire out of the knee

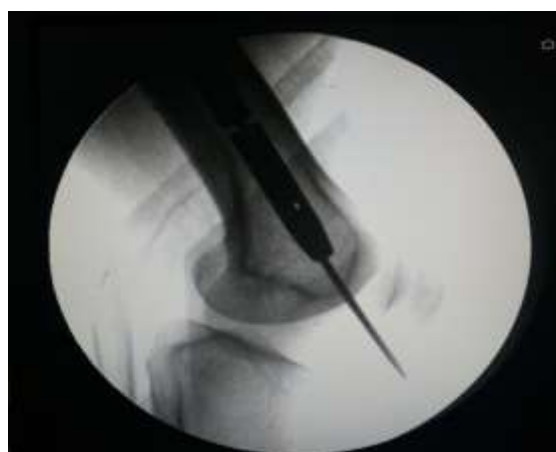

Fig. 3(b): A C-arm Lateral image of exiting the guide wire out of the knee

Now the tip of the wire is doubled over itself to make a loop of the wire at its terminal end, so that it may behave like a ball tipped guide wire (Fig. 4, Fig. 5).

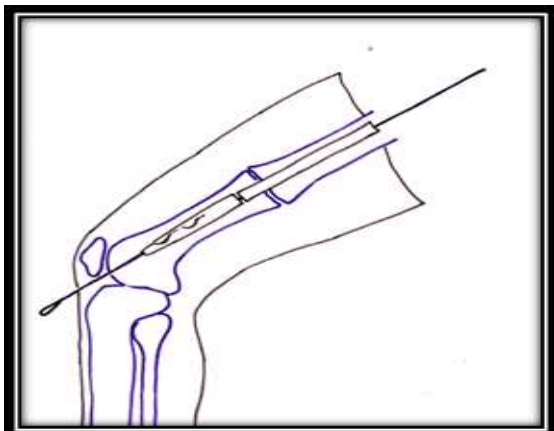


Fig. 4: A sketch depicting the doubled-up tip of the exited guide wire

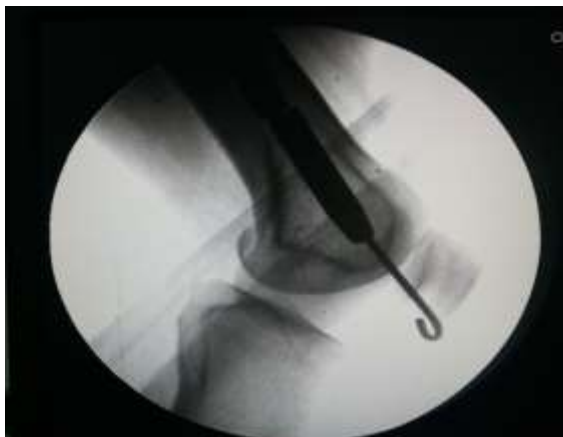

Fig. 5: A C-arm image of doubled up tip of the exited wire

The patellar tendon is then split slightly at a point of wire protrusion and is widened slightly by a hemostat to pull the wire proximally avoiding damage to the tendon. The wire is then pulled back proximally into the lower end of the femur till it gets stuck up at the end of the distal piece of the broken nail. The knee is then extended and the foot of the limb is again secured into the foot holder of the fracture table. Now a cannulated extractor of the femoral nail is threaded over the proximal portion of the guide wire and is screwed tightly into the proximal end of the femoral nail. The entire nail is then pulled out by gentle blows of the extractor hammer while one of the assistant keeps pulling the guide wire tightly and proximally with every blow of the extractor hammer. Both the pieces of the broken nail are thus extracted together easily and safely (Fig. 6).



Fig. 6: Extracted both pieces of broken nail together with the help of a doubled up tip guide wire

After extraction of the broken nail, exchange nailing is carried out in the usual fashion.

Results

We used this technique in twelve patients who had disturbed union with broken intramedullary nails (Table 1). These broken nails were extracted from March 2012 to February 2015. In all the 12 patients, the broken nail was extracted easily by this innovative technique developed at our institution without opening the fracture site and without disturbing whatever callus was present in the process of union. All these patients, after extraction of broken nail were managed by exchange nailing with one size larger nail after reaming of the medullary canal (Fig. 7a, Fig. 7b).

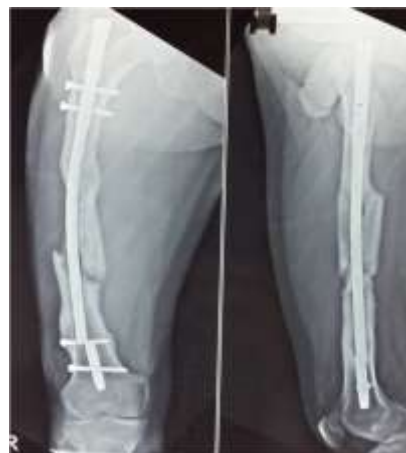

Fig. 7 (a): AP and Lateral radiographs of femur with broken nail

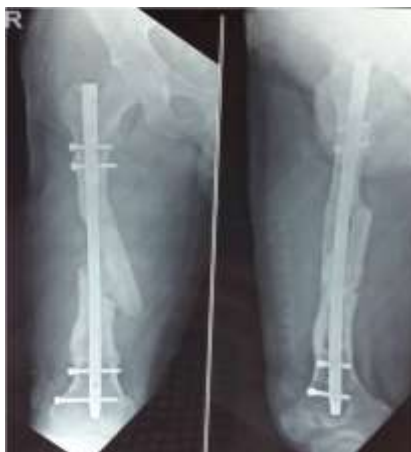

Fig. 7 (b): AP and Lateral radiographs of femur after exchange nailing

None of these patients developed heamarthrosis after the extraction of the broken nail by this technique and also there was no compromise in the pre nail extraction knee range of motion, and/or function (Table 1). None of the patient developed any sign of early or delayed infection and there was no impairment of knee function in any of the patient at the final follow up. All patients achieved union after exchange nailing within a mean period of 19.8(16-24) weeks (Table 1). Mean follow up period after exchange nailing was about 20.3 (range 18-24) months (Table 1).

Table 1: Showing clinical details of patients treated for broken femoral nails

S. No.	Age (years)	Sex	Union time after exchange nailing (weeks)	Follow-up period (months)	Knee ROM before removal of broken nail (Degree)	Knee ROM after exchange nailing (Degree)
1.	36	M	20	21	0 – 130	0 – 130
2.	30	M	18	18	0 – 120	0 – 120
3.	26	M	16	20	0 - 120	0 – 120
4.	38	M	19	19	0 – 110	0 – 110
5.	45	M	21	21	0 – 130	0 – 125
6.	38	M	18	24	0 – 120	0 – 120
7.	47	M	22	21	0 – 110	0 – 110
8.	36	M	19	20	0 – 125	0 – 120
9.	45	M	23	18	0 – 130	0 – 130
10.	32	M	24	22	0 – 130	0 – 125
11.	30	M	18	20	0 – 120	0 – 120
12.	43	M	20	20	0 – 115	0 – 115

Discussion

Closed retrieval of broken intramedullary femoral nails poses a great challenge for an orthopaedic surgeon. Though several techniques with a battery of special instruments⁽⁶⁻¹³⁾ are accessible in the orthopaedic literature for this challenging task but the difficulty of easy availability and higher cost of special instruments often compels the treating surgeon to open up the fracture site to take out the distal fragment of the fractured nail. Our simple, aforementioned innovative technique was found to be quite effective in closed extraction of a broken intramedullary femoral nail in all the twelve patients included in this study. The results of the other techniques described using olive wires, laparoscopic grabbers⁽⁴⁻⁵⁾ etc. have been described successful. The results of our technique are found to be

quite comparable with the results of various other techniques described in the literature. Our technique does not require any special instrument except a cannulated extractor and a standard guide wire.

Conclusion

In our opinion, this innovative technique of broken nail extraction is quite simple, successful without causing any impairment of knee function despite penetration of the guide wire into the joint, and is very cost effective. The technique is so simple that it can be executed by any orthopaedic surgeon at any centre. The technique neither requires a steep learning curve, nor any sophisticated instrumentation. There are several techniques described in the literature for the extraction of broken nails. We are not claiming that our technique

is superior to any of them rather we are just submitting that our technique is only a simple alternative to other proven techniques.

We feel that an objection may be raised against the penetration of guide wire in an otherwise innocent knee joint during the course of extraction of broken nail by our technique, which, however, in our opinion is not very boldly sustainable as none of the patients treated by our technique developed any early or delayed problem in their knee joint.

References

1. Bucholtz RW, Brumback RJ. Fractures of the shaft of the femur. In: Rockwood J, Green DP, Bucholtz RW, Heckman JD, editors. Fractures in adults. Philadelphia: Lippincott-Raven; 1996. Pp. 1918-27.
2. Winquist RA, Hansen ST, Clawson DK. Close intramedullary nailing of femoral fractures. *J Bone Joint Surg Am* 1984;66:529-39.
3. Giannoudis PV, Matthews SJ, Smith RM. Removal of the retained fragment of broken solid nails by the intramedullary route. *Injury* 2001;32:407-10.
4. Franklin JL, Winquist RA, Benirschke SK, Hansen ST Jr. Broken intramedullary nails. *J Bone Joint Surg Am* 1988;70:1463-71.
5. Brewster NT, Ashcroft GP, Scotland TR. Extraction of broken intramedullary nails-an improvement in technique. *Injury* 1995;26:286.
6. Marwan M, Ibrahim M. Simple method for retrieval of distal segment of the broken interlocking intramedullary nail. *Injury* 1999;30:333-5.
7. Levy O, Amit Y, Velkes S, Horoszowski H. A simple method for removal of fractured intramedullary nail. *J Bone Joint Surg Br* 1994;76:502-3.
8. Maini L, Upadhyay A, Aggarwal A, Dhaon BK. A new method of removing fractured interlocked nail. *Injury*.2002;33:261-2.
9. Maini L, Jain N, Singh J, Singh H, Bahl A, Gautam VK. Removal of a multi-segmental broken nail by close technique using a TEN nail. *J Trauma* 2009;66:e78-80.
10. Whalley H, Thomas G, Hull P, Porter K. Surgeon versus metalwork tips to remove a retained intramedullary nail fragment. *Injury* 2009;40:783-9.
11. Tadros AM, Blachut P. Segmentally fractured femoral Kuntscher nail extraction using a variety of techniques. *AM J Orthop* 2009;38:E59-60.
12. Oberst M, Schlegel k, Mory C, Suedkamp N. Endoscopically controlled removal of a broken intramedullary nail: A new technique. *Injury Extra* 2005;36:582-5.
13. Metikala S, Mohammad R. Closed retrograde retrieval of the distal broken segment of femoral cannulated intramedullary nail using a ball tipped guide wire. *Indian J Orthop* 2011;45:347-50.