

Outcome of fiber optic bronchoscopy in sputum smear negative pulmonary tuberculosis

Choudhary S¹, Tayade BO², Kharbade S³, Sontakke A¹, Khan S⁴, Abraham R⁵

Abstract:

Bronchoscopy is very useful for diagnosing Sputum smear-negative pulmonary tuberculosis (SSN-PTB). Our aim is to find out the diagnostic yield of fiber optic bronchoscopy in sputum smear negative under RNTCP and radio logically suspected new cases of pulmonary tuberculosis and the complications of fiber optic bronchoscopy. A cross-sectional prospective study in which consecutive 108 patients was carried out in patients whose two sputum smear for Acid Fast Bacilli was negative and chest X-ray suggestive of pulmonary tuberculosis were included into the study. Fiber optic bronchoscopy was carried out in all patients. The yield for tuberculosis was 78 % (85/108) i.e. made a final diagnosis of tuberculosis. 29 (26.85%), 41(37.96%) and 30(27.78%) patients had positive AFB smear on Bronchial brush, Broncho alveolar lavage and post bronchoscopy sputum of which 11(12.94%), 22(25.88%) and 13(15.29%) patients had exclusive diagnosis from the respective procedures. The immediate yield combining positive smear samples from different procedures and histopathological evidence of caseating granuloma in present study is 56%(61/108). In Broncho alveolar lavage culture 57/108(57.08%) were confirmed tuberculosis diagnosis and 24(28.4%) patients had exclusive diagnosis on bronchial culture. Bilateral, advanced, and non cavitary disease had 52, 53 and 64 patients diagnosed as pulmonary tuberculosis and was more as compared to different site, extent and type of disease on chest x-ray which were initially negative for tuberculosis. Our study suggests that fibre-optic bronchoscopy and its procedure can provide excellent material for early as well as confirming the diagnosis in suspected patients of pulmonary tuberculosis when smears of expectorated sputum do not reveal mycobacteria and helps in diagnosing different diseases and disorders having clinical picture mimicking tuberculosis.

Keywords: Sputum smear-negative, Pulmonary tuberculosis, Chest x-ray, Fiber optic bronchoscopy, Bronchial washings, Bronchial biopsies.

¹Associate Professor,

²Professor,

³Senior Resident,

⁴Assistant Professor,

⁵Junior Resident,

Department of Pulmonary

Medicine, NKP SIMS & RC,

Digdoh hills, Nagpur 440019.

drsumerchoudhary91@gmail.com

Introduction:

Tuberculosis (TB) is a disease known since time immemorial. Every four seconds individual contracts tuberculosis and one of them dies every 10 seconds (1-2). The most widely used tool of diagnosis of pulmonary tuberculosis is sputum examination and chest X-Ray. Sputum smear and culture examinations still remain the gold standard in the diagnosis of pulmonary tuberculosis (3-5). Acid-fast bacilli (AFB) smears of respiratory specimens (at least two or more specimens) are important for the prompt diagnosis of PTB, but AFB smears have poor sensitivity (30–70%) despite high specificity (98–99%). Mycobacterial cultures are more sensitive than AFB smears (80–85%), but culture results usually require 3–8 weeks

(6). It is also known that in many patients, this stringent criterion cannot be satisfied due to factors like : (a) lack of sputum production, (b) low bacterial yield, and (c) incorrect or improper sampling. Serological immune markers are also not a reliable indicator for diagnosis of disease. According to the Global tuberculosis report 2013, there were 1.29 million notified tuberculosis cases in India in 2012 out of which about 30% were smear negative cases (7). These sputum smear-negative pulmonary tuberculosis (SSN-PTB) poses a common problem faced by the clinicians.

Early diagnosis would help in curtailing the mortality and morbidity of disease. However, even after meticulous sputum examination the bacteriological

positive yield is only between 16% to 50 % (8). This means patients having signs and symptoms along with chest X-Ray consistent with pulmonary tuberculosis are sputum negative. If these patients were left untreated, 64% of them would require chemotherapy within twelve months (9). In 1965, the advent of flexible bronchoscope revolutionized the practice of pulmonary tuberculosis. In such patients bronchoscope is tried for rapid and early diagnosis of the underlying pathology.

Aims and Objectives:

1. Assess the role of fiber optic bronchoscopy in sputum negative patients with high clinical suspicion of pulmonary tuberculosis.
2. To confirm the diagnosis of pulmonary tuberculosis in sputum negative pulmonary tuberculosis.
3. To correlate fiber optic bronchoscopy diagnosed positive and negative patients and different chest X-ray presentations.
4. Role of fiber optic bronchoscopy in early diagnosis of sputum negative pulmonary tuberculosis and to confirm other diseases.
5. To study the risk associated with the procedure.

Materials and Methods:

Inclusion Criteria:

Patients above age of 15 years, these patients are those who are AFB negative, however chest x-ray and clinical profile points towards pulmonary tuberculosis.

Exclusion Criteria:

Patients with bleeding diathesis, history of myocardial infarction or arrhythmia, extra-pulmonary tuberculosis, history of anti-tubercular treatment (ATT) for more than one month, and those with severe dyspnoea were excluded from the study. HIV-positive and non-cooperative patients were also excluded.

Chest X-ray Classification of Disease:

Two respiratory physicians evaluated chest radiographs independently without access to other information. The radiological classification of disease extent was as follows (10): 0= no disease. 1= Mild/minimal PTB (when the lesions did not cross the area above the sternal cartilage of the second rib on one side); 2= Moderate/intermediate PTB (when moderately advanced lesions could be seen in one or both lungs, with disseminated lesions of low to moderate density extending throughout one lung or the equivalent in both lungs, or dense, confluent lesions limited to one-third of the volume of one lung); and 3= Severe/extensive well advanced PTB (when the lesions were even more extensive). On the chest X-rays, lungs were also divided into upper, middle and lower zones, which were delimited by the upper border of the second and fourth anterior ribs, and all six zones were assessed for findings indicative of tuberculosis.

Parenchymal disease was categorized as unilateral or bilateral.

Criterion for Active and Inactive Disease:

The presence of lymphadenopathy, pleural disease, or miliary abnormalities was noted. Lung parenchymal abnormalities were classified as "inactive" or "potentially active". A grading of "inactive disease" denoted isolated fibrotic (reticular) abnormalities or calcified and/or sharply defined tuberculomata. Abnormalities compatible with "potentially active disease" included consolidation (air Broncho grams), an impression of patchy fluffy shadowing (with or without an admixture of fibrotic changes), a miliary pattern, pleural effusion or non-calcified opacities with an indistinct border. If previous radiographs were available, serial appearances were taken into account. In cases with divergent assessments, final grades were reached by consensus.

Procedure:

All procedures were carried out as per the International recommendations. Prior to the procedure an informed written consent was obtained from the patient. The procedure was carried out electively with the patient nil orally for four to six hours. Patients were pre-medicated 30-45 minutes prior to bronchoscopy with 0.6 mg atropine and nebulization was done with two per cent xylocaine via nebulizer. Bronchoscopy was carried out under local anesthesia. Olympus BF type IT 240 Video Bronchoscope was used.

A thorough examination of the bronchial tree was carried out. Bronchial segments which were thought from the chest radiograph to be the site of active or inactive TB were washed with 40 ml normal saline. Bronchial washing was performed by instilling 0.9% isotonic saline at room temperature through the internal channel of the fiberoptic bronchoscope and aspirated into a trap connected to suction tubing. Usually 15-30 ml of fluid was instilled with each washing and about one-fourth to half of this volume was retrieved in the suction trap. Up to one-fourth of the instilled amount retrieved was considered successful. The bronchial washings were sent for AFB staining, AFB culture by BACTEC, and cytology and cell count. Tran's bronchial lung biopsy (TBB) was done with the biopsy forceps and sent for histopathological examination. In cases where an end bronchial growth was seen washing, brushing and bronchial biopsy (BB) were performed.

Post Procedure Care:

After the procedure, the patient was observed for development of pneumothorax, hemorrhage, infection and cardiac arrhythmias for 24-48 hours. The first sputum sample after bronchoscopy (post-

bronchoscopic sputum) was collected and sent for analysis along with bronchial washings.

Diagnostic Yield:

A early/immediate diagnosis of sputum smear-negative PTB by FOB was defined as a diagnosis of PTB through methods that yielded results within 1 week: (1) Positive AFB smear on Bronchial Brush (BS)+Bronchioalveolar Lavage(BAL)+Post Brochoscopy Sputum(PBS) (2) Caseating granuloma upon cytology/ biopsy. In cases diagnosed by cytology/biopsy active PTB was confirmed as caseation granuloma.A final diagnosis of ‘non-TB’was accepted when an alternative diagnosis was reached.

Type of Study:

This is a prospective, Cross Sectional Study.
 Study Place: Department of Pulmonary Medicine, N.K.P.Salve Institute Of Medical Sciences And Research Center And Lata Mangeshkar Hospital, Digdoh Hills Hingna Nagpur.
 Ethical Issues: Study was approved by Institutional Ethics Committee.

Results:

Patient’s Characteristics:

Figure 1: Sex of Patients

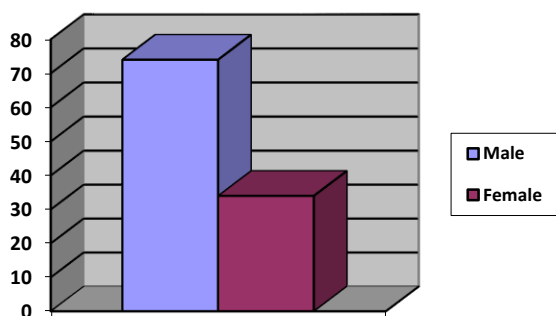


Table 1: Mean Age

| Patients Characteristics | Mean Age |
|--------------------------|---------------|
| Study Group | 43.76 ± 15.43 |
| Male | 43.48 ± 14.42 |
| Female | 44.47 ± 19.25 |

Table 2: Symptoms Characteristics

| Symptoms Characteristics | Frequency | Percent |
|--------------------------|-----------|---------|
| Cough | 98 | 90.74 |
| Expectoration | 78 | 72.22 |
| Fever | 72 | 66.67 |
| Constitutional Symptoms | 60 | 55.56 |
| Breathlessness | 30 | 27.78 |
| Haemoptysis | 04 | 03.70 |

| | | |
|---------------------------|------------|-------|
| Chest Pain | 04 | 03.70 |
| Mean Duration Of Symptoms | 2.1 Months | |

Table 3: Chest X-ray Site of Disease

| Chest X-ray | Frequency (n=108) | Percentage | TB Diagnosed | Percent |
|-------------|-------------------|------------|--------------|---------|
| Right | 65 | 60.19 | 52/65 | 80 |
| Left | 37 | 34.26 | 29/37 | 78.37 |
| Bilateral | 6 | 5.55 | 04/6 | 66.67 |

Table 4: Chest X-ray Extent of Disease

| Chest X-ray Extent of Disease | Frequency (n=108) | Percent | TB Diagnosed | Percent |
|-------------------------------|-------------------|---------|--------------|---------|
| Mild/Minimal | 68 | 62.96 | 53/68 | 77.94 |
| Moderate | 29 | 26.85 | 23/29 | 79.31 |
| Extensive/Advanced | 11 | 10.08 | 9/11 | 81.81 |

Figure 2: Chest X-ray Type of Disease

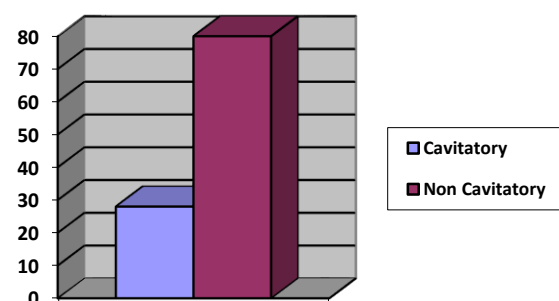


Table 5: Tuberculosis Confirmed and Chest X-ray Disease Type

| Chest X-ray Type Of Disease | TB Diagnosed | Percent |
|-----------------------------|--------------|---------|
| Cavitary | 21/28 | 75% |
| Non Cavitary | 64/80 | 80% |

Table 6: Bronchoscopic Findings/Results in study group

| Bronchosopic Features | Frequency (n=108) | Percent |
|---|-------------------|---------|
| Congestion And Hyperemia | 41 | 37.96 |
| Granulomata and Tubercles with Caseous Material | 21 | 19.44 |
| Narrowing of Segmental Opening | 19 | 17.59 |
| Ulceration and Erosion | 16 | 14.81 |
| Bleeding from bronchus | 7 | 6.48 |
| Necrotic red patches with sloughed mucosa | 6 | 5.56 |
| Endobronchial Growth | 5 | 4.63 |

Multiple findings in some patients

★ The bronchoscopic findings were as follows: Congestion and hyperemia in majority 41 (37.96%) patients, 21 (19.44%) patients had Granulomata and Tubercles with Caseous Material, 19 (17.59%) patients had narrowing of segmental opening, Ulceration and erosion was seen in 16(14.81%)

patients this was the most common finding in patients of cavitary disease, bleeding from the bronchus in 7(6.48%) patients, 6 (5.56%) patients Necrotic red Patches with Sloughed Mucosa and endobronchial growth was seen in 5(4.63%) patients.(Table 6)

Table 7: Diagnostic Yield of fiber optic bronchoscopy in new sputum negative pulmonary tuberculosis

| Specimen | Positive Results | Percent | 95% CI | Exclusively Positive Specimens | |
|--------------------------------------|------------------|---------|-------------|--------------------------------|-------|
| | | | | | |
| Brush Smear | 29/108 | 26.85 | 18.32-35.37 | 11 | 12.94 |
| BAL Smear | 41 /108 | 37.96 | 28.62-47.29 | 22 | 25.88 |
| Post Bronchoscopic Sputum Smear | 30/108 | 27.78 | 19.15-36.40 | 13 | 15.29 |
| Biopsy | 39/56 | 69.64 | 57.35-81.92 | 15 | 17.65 |
| Histopathology(TBB+Bronchial Biopsy) | | | | | |
| Bronchoalveolar Lavage Culture | 57/108 | 52.78 | 43.17-62.39 | 24 | 28.24 |

Through bronchoscope, brush smear, bronchial aspirate, and bronchial alveolar lavage (BAL) were collected and smeared for ZN staining for AFB in all the 108 patients from the affected segment of the lung sent for cytological examination. BAL was sent for culture. In selected patients Transbronchial biopsy and bronchial biopsy were done. After bronchoscopy, PBS was also taken for ZN staining for AFB. In study group of 108 patients, 29 (26.85%) patients were positive for AFB by ZN staining from BS, 41 (37.96%) patients were positive in BAL smear and 30 (27.78%) patients

were positive on PBS smear. 57(52.78%) patients were positive for tuberculosis on culture of the PBS specimen. In 56 patients in whom biopsy was done 39(69.64%) patients showed evidence of tuberculosis on histopathology reports of biopsy specimens. 11(12.94%),22(25.88%),13(15.29%),15(17.65%) and 24(28.24%) patients were exclusively positive for mycobacterium tuberculosis in BS,BAL smear,PBS,Biopsy and BAL culture respectively.(Table7)

Table 8: Result of microscopic examination of bronchial specimens

| Cytological Findings | Frequency | Percent |
|-----------------------------------|-----------|---------|
| Normal | 17 | 15.74 |
| Non Specific Chronic Inflammation | 34 | 31.48 |
| Caseating Granuloma | 15 | 13.88 |
| Non caseating Granuloma | 14 | 12.96 |
| Acute Inflammation | 15 | 13.88 |
| Malignancy | 06 | 5.56 |

Cytology revealed normal findings in 17(15.74%) patients, nonspecific chronic inflammation in 34(31.48%) patients, caseating granuloma in 15(13.88%) patients, non caseating granuloma in

14(12.96%) patients, 15(13.88%) patients acute inflammation and remaining 6(5.56%) patients' features of malignancy. (Table 8)

Table 9: Diagnostic yield of bronchoscopic specimens (n=108)

| Disease Diagnosed | Frequency | Percent |
|---|-----------|---------|
| Pulmonary Tuberculosis Patients Diagnosed | | |
| 1. With smear (BS+BAL+PBS) | 46 | 42.59 |
| 2. With BAL culture | 24 | 22.22 |
| 3. With Biopsy(TBB+BB) | 15 | 13.89 |
| Total | 85 | 78.70 |
| Other Diseases Patients Diagnosed | | |
| 1. Malignancy | 6 | 5.56 |
| 2. Bacterial Pneumonia | 17 | 15.74 |
| Total | 23 | 21.30 |

When all results were combined together it was found that in the study group of 108 patients, 85(78.70%) patients could be diagnosed as a case of pulmonary TB, while 23 (21.30%) patients had a diagnosis other than pulmonary TB. Immediate/early diagnosis was made in 61(56.48%) 95% CI 46.93-66.02 patients, whereas 24(22.22%) 95%CI 14.22-30.22, patients were diagnosed exclusively by Broncho alveolar lavage culture. (Table 9).

Discussion:

The challenge to the respiratory physicians is to diagnose patient of tuberculosis with symptoms and radiography features suggestive of tuberculosis however having negative sputum smear (11). These sputum smear-negative pulmonary tuberculosis (SSN-PTB) still remains a common problem faced by the clinicians. Culture results in these patients' leads to a delay in treatment, on the other hand, empirical treatment initiation in these patients increase the number of unnecessary treatment. Flexible fibreoptic bronchoscopy provides material, aspirate as well as biopsy, from localized affected areas of lung aiding in early diagnosis of smear negative tuberculosis (12, 13).

In the present prospective analysis, we have shown the diagnostic yield of bronchoscopy in smear negative pulmonary tuberculosis.

In present study 37.96% of cases showed congestion with hyperemia of bronchial mucosa on bronchoscopy, 14.81% of patients had erosion, ulceration and granulation on bronchoscopy, segmental narrowing was observed in 17.59% patients, 4.63% of patients with intra-luminal growth were diagnosed as malignancy and later confirmed by the cytological examination of bronchial washing fluid as adenocarcinoma.

Similarly, Purohit SD et al (1983) reported generalized congestion/hyperemia in most of the patients (14). Wallace JM et al (1981) reported congestion of mucosa in 86% with no significant correlation of endoscopic findings with mycobacterial positivity (15). Purohit et al (14) reported ulceration in 64% of patients; 60% had frothy secretion for the bronchus. A moderate hyperemia of bronchial mucosa was observed in all the patients.

Kulpati et al (8) observed the coating of mucosa of involved segments with yellowish white secretions in almost all patients and also revealed mild to moderate hyperemia after bronchial wash. Segmental bronchus was narrowed in 20% patients, and ulceration was seen in 20% patients.

Similar observations were made by Panda et al (16) according to their study, 44% had normal bronchial mucosa, 21% had unhealthy mucosa with granulations, 35% had discharge of mucous from bronchus, 5% had growth, 3% had external compression and three per cent had bleeding from bronchus and some cases had multiple findings.

The smear results 64.81% of bronchial aspirate/washing/brush were comparable with the studies of Sarkar et al (1980) and So et al (1982) who reported it as 67% and 38% respectively and much higher compared to the study of Wallace et al (1981), who reported it as 13% (15,17-18).

The results of stained smear examination of bronchial washing was confirmed by culture in 100% of cases in the present study, which is comparable to the studies by Kulpati et al.(8) (100%), Danek and Bower (19) (95%), Sarkar et al.(20) (87%), Uddenfeldt and Lundgren (83%) (21). In this study, bronchial washing-culture was positive for acid fast bacilli in 52.78% patients, similar to that reported by Kulpati et al (8) Kvale et al.(22) could grow acid fast bacilli only in one third of the patients of suspected tuberculosis. Kato et al (23) reported that higher concentration of lidocaine had an inhibitory effect on mycobacterial growth. Though we did not culture the biopsy material, bacilli were grown in 20%, 60%, and 41% in studies of Wallace et al (15), Funahashi et al (24) and Danek and Bower (19) but this was not the only diagnostic evidence in any of the studies and did not influence the diagnostic contribution of other methods. Wallace et al. (15) and Danek and Bower (19) had reported 95% culture positivity of specimens obtained by flexible fibreoptic bronchoscopy and therefore negative culture provided strong evidence against tuberculosis.

On Chest X-ray Bilateral, Advanced, and non cavitory disease had 52, 53 and 64 patients diagnosed as pulmonary tuberculosis and was more as compared to different site, extent and type of disease as classified initially.

In the present study no major complication or mortality was observed, only minor complications were observed, in 23 patients (sinus tachycardia-8, pneumothorax-4, minimal haemoptysis <10ml -11) for which no active management was required. Contrary to the present study Pereira W et al (1978) observed major complications in 1.7% of the procedures with one death yielding a mortality 0.1%, however reporting minor complications including vasovagal reactions, fever, cardiac arrhythmias, bleeding, obstruction of airway, nausea, vomiting, pneumothorax, psychotic reactions and apnoea occurred in 6.5% of the procedures (25).

In various previous studies flexible fibreoptic bronchoscopy in combination with transbronchial lung biopsy provided early diagnosis in 60% to 85% of smear negative pulmonary tuberculosis. In our

study flexible fibreoptic bronchoscopy provided the diagnosis in 78.70% of patients which is similar to the previous studies.

Comparison of the present study with previous studies in literature.

| Author | Year Of Publication | Country | Yield for tuberculosis % (No. of cases) | Immediate diagnosis % (No. of cases) |
|-----------------------|---------------------|-----------|---|--------------------------------------|
| Danek et al.(19) | 1979 | USA | 95 (39/41) | 34 (14/41) |
| Uddenfeldt et al.(21) | 1981 | Sweden | 83 (25/30) | NS |
| So et al.(18) | 1982 | Hong Kong | 94 (61/65) | 65 (42/65) |
| Stenson et al.(26) | 1983 | USA | 66 (8/12) | 42 (5/12) |
| Russel et al.(27) | 1986 | USA | 100 (25/25) | 12 (3/25) |
| Kulpati et al.(8) | 1986 | India | 60 (20/33) | 40 |
| Palenque et al.(28) | 1987 | Spain 34 | 100 (50/50) | 34 (17/50) |
| Wongthim et al.(29) | 1989 | Thailand | 76 (54/71) | 75 (53/71) |
| Khoo et al.(30) | 1989 | UK | 26 (9/35) | 9 (3/35) |
| Zainudin et al.(31) | 1991 | Malaysia | 100 (33/33) | 55 (18/33) |
| Fujii et al.(32) | 1992 | Japan | 91 (29/32) | 44 (14/32) |
| Present study | 2014 | India | 78 (85/108) | 56(61/108) |

Conclusion:

The diagnostic yield of flexible bronchoscope is determined by indication of its use and the skills of endoscopist as well as the pathologist. In patients where expectoration is negligible and high suspicion, who's sputum is negative fiber optic bronchoscope and Broncho alveolar lavage, analysis for AFB, along with culture would help in rapid and precise diagnosis that will reduce the risk of nosocomial transmission of TB. FOB is also more useful in the diagnosis of end bronchial TB, which can be seen as normal in HRCT, and FOB may be superior in the differential diagnosis of tuberculosis with other commonly encountered diseases such as pneumonia or lung cancer (33).

Our study suggests that fibre-optic bronchoscopy can provide excellent material for diagnosis of suspected cases of pulmonary tuberculosis when smears of expectorated sputum do not reveal mycobacteria. Fibre-optic bronchoscopy combined with trans bronchial lung biopsy helps in early diagnosis of smear negative pulmonary tuberculosis and differentiation of other disorders where clinical picture mimics tuberculosis in our setup RNTCP plays a major role in treatment of tuberculosis. However under RNTCP programme there is no provision of sputum culture in new sputum smear negative patients nor there is provision of bronchoscopy based diagnosis of these patients. The financial constraints limit most of the underprivileged section of society to undertake this procedure. Hence there is need to formulate guidelines where the respiratory physician can make a definitive diagnosis without increasing the number of unnecessary treatment in new sputum negative tuberculosis patients.

Acknowledgement:

I am thankful to Dr Manoj Talapalliwar Assistant Professor department of Preventive and Social Medicine (P.S.M), NKP SIMS RC & LMH for helping me in statistical analysis.

References:

1. Narain JP. Tuberculosis Epidemiology and Control. New Delhi: WHO regional office for south east asia; 2001:p248.
2. Dye C, Scheele S, Dolin P, Pantania V, Raviglione MC. Global burden of tuberculosis: Estimated incidence prevalence and mortality by country. WHO Global surveillance and Monitoring Project. JAMA 1999; 282:67-86.
3. Park, J.E. and Park K. Text Book of Preventive and Social Medicine-12th Ed. Jabalpur. Banarasidas Bhanot, 1989; 132.
4. Roberts G.D: Bacteriology and bacteriological diagnosis of tuberculosis. David Schlosberg ed. Tuberculosis, 2nd Ed, New York. Springer Verlag Publishing Company, 1988: 23- 24.
5. New Delhi Tuberculosis Centre: Annual Report 1987.
6. Foulds J, O'Brien R: New tools for the diagnosis of tuberculosis: the perspective of developing countries. Int J Tuberc Lung Dis 1998, 2:778-783
7. World Health Organization. Global tuberculosis report 2013.
8. Kulpati DD, Heera HS, Diagnosis of sputum smear negative tuberculosis by flexible bronchoscopy. Indian J Tuber 1986; 33:179-82.
9. Hong Kong Chest Service, Tuberculosis Research CenLre, Madras, India and British Medical Research Council. -Sputum smears negative pulmonary tuberculosis -controlled trial of 3 months and 2 months regimen of chemotherapy. First report. Lancet, 1979, 1: 1361-1363.
10. Crofton J, Seaton A, Seaton D, Leitch AG. Crofton and Douglas's Respiratory Diseases. Oxford: Blackwell; 2000.

11. Chawla R, Pant K, Jaggi OP, et al. Fiberoptic bronchoscopy in smear negative pulmonary tuberculosis. *Eur Respir J* 1998; 1: 804-6.
12. Dolin PJ, Raviglione MC, Kochi A (1994) Global tuberculosis incidence and mortality during 1990-2000. *Bull World Health Organ* 72: 213-220.
13. Dhanragir H .The changing spectrum of tuberculosis. *Experta Medica* 1995 ; 2. 6.
14. Purohit SD, Sisodia RS, Gupta PR, SarkarSK and Sharma TN. Fiber optic bronchoscopy in diagnosis of smear negative pulmonary tuberculosis. *Lung India*, 1983; I (4):143-146.
15. Wallace JM, Deutsch AL, Harsell JH and Moser KM. Bronchoscopy and transbrochial Biopsy in evaluation of patients with suspected active tuberculosis. *The American Journal of Medicine* June 1981; 70:1189-1194.
16. Pande BN, Rajan KE, Jena J, Nema SK, Murali M, Patel AP. Diagnostic yield from flexible fibreoptic bronchoscopy in sputum smear negative pulmonary tuberculosis cases. *Indian J Tuberc.* 1995; 42:207-9.
17. Sarkar SK, Sharma TN, Purohit SD, Gupta ML and Gupta PR. The diagnostic value of routine culture of bronchial washings in tuberculosis. *Br. J. Dis. chest*, 1982; 76:358-360.
18. So SY, Lam WK, Yu DY. Rapid diagnosis of suspected pulmonary tuberculosis by fiber optic bronchoscopy. *Tubercle*, 1982; 63(3): 195-200.
19. Danek SJ, Bower JS. Diagnosis of pulmonary tuberculosis by flexible fibreoptic bronchoscopy. *Am Rev Respir Dis.* 1979; 119:677-9.
20. Sarkar SK, Sharma GS, Gupta PR, Sharma RK. Fibreoptic bronchoscopy in the diagnosis of pulmonary tuberculosis. *Tubercle*. 1980 Jun;61(2):97-9.
21. Uddenfeldt M, Lundgren R. Flexible fibreoptic bronchoscopy in the diagnosis of pulmonary tuberculosis. *Tubercle*. 1981 Sep;62(3):197-9.
22. Kvale PA, Johnson MC, Wroblewski DA. Diagnoses of tuberculosis, routine cultures of bronchial washings are not indicated. *Chest*. 1979; 76:140-2.
23. Kato H, Fukuhara T, Mashimo K, Matsushima S, Saito T. Transbronchial bacteriological culture study using flexible fibreoptic bronchoscope: A bacteriological study of lidocaine solutions. *J Jpn Bronchoesophagol Soc.* 1978; 29:291-8.
24. Funahashi A, Lohaus GH, Politis J, Hranicka LJ. Role of fibreoptic bronchoscopy in the diagnosis of mycobacterial diseases. *Thorax*. 1983; 38:267-70.
25. Pereira W, Kovnat DM and Snider GL. A Prospective cooperative study of complications following flexible fiber optic Bronchoscopy. *Chest*, 6 June 1978; 73:813-816.
26. 16. Stenson W, Aranda C, Bevelaqua FA. Transbronchial biopsy culture in pulmonary tuberculosis. *Chest*.1983; 83:883-4.
27. Russell MD, Torrington KG, Tenholder MF. A ten-year experience with fibreoptic bronchoscopy for mycobacterial isolation: Impact of the Bactec system. *Am Rev Respir Dis.* 1986; 133:1069-71.
28. Palenque E, Amor E, Bernaldo de Quiros JC. Comparison of bronchial washing, brushing and biopsy for diagnosis of pulmonary tuberculosis. *Eur J Clin Microbiol.* 1987; 6:191-2.
29. Wongthim S, Udompanich V, Limthongkul S, Charoenlap P, Nuchproyoom C. Fibreoptic bronchoscopy in diagnosis of patients with suspected active pulmonary tuberculosis. *J Med Assoc Thai.* 1989; 72:154-9.
30. Khoo KK, Meadway J. Fibreoptic bronchoscopy in rapid diagnosis of sputum smears negative pulmonary tuberculosis. *Respir Med.* 1989; 83:335-8.
31. Zainudin BM, Wahab Sufarlan A, Rassip CN, Ruzana MA, Tay AM. The role of diagnostic fibreoptic bronchoscopy for rapid diagnosis of pulmonary tuberculosis. *Med J Malaysia.* 1991; 46:309-13.
32. Fujii H, Ishihara J, Fukaura N, Kashima N, Tazawa H, Nakajima H, et al. Early diagnosis of tuberculosis by fibreoptic bronchoscopy. *Tubercle Lung Dis.* 1993; 73:167-9.
33. Araz O, Akgun M, Saglam L, Ozden K, Mirici A: The diagnostic value of bronchoscopy in smear negative cases with pulmonary tuberculosis. *Tuberk Toraks* 2008, 56:150-157.