

Case Report

Early removal of odontoma resulting in spontaneous eruption of the impacted teeth

Achmad Harijadi

Department of Oral and Maxillofacial Surgery
Faculty of Dentistry, Airlangga University
Surabaya - Indonesia

ABSTRACT

Background: Compound odontomas in the anterior maxilla during mixed dentition frequently cause obstruction to the eruption pathway of permanent upper anterior teeth. Removal of the odontomas may or may not lead to spontaneous eruption of the impacted teeth depending on the age when the surgery is performed, the size of the lesion, and the stage of tooth development of the involved teeth. **Purpose:** This paper attempts to emphasize the importance of early removal of compound odontoma to enable spontaneous eruption of the affected teeth. **Case:** A case of odontoma in the anterior maxilla causing failure of eruption and delayed root formation of upper right permanent lateral incisor and canine in a 10-year-old male patient is presented. **Case management:** The odontoma was surgically removed under general anesthesia and histology result confirmed the diagnosis of compound odontoma. A three-year post surgical follow up showed spontaneous eruption as well as continued root formation of the two affected teeth. **Conclusion:** Removal of odontoma may lead to spontaneous eruption of the affected teeth if their root development are not completed.

Key words: Odontoma, delayed root formation, spontaneous eruption

ABSTRAK

Latar belakang: Compound odontoma pada daerah anterior maksila pada masa geligi pergantian sering menyebabkan hambatan erupsi pada gigi permanen penggantinya. Kemungkinan terjadinya erupsi spontan gigi permanen yang impaksi setelah pengambilan odontoma tergantung dari: umur penderita pada saat dilakukan operasi, ukuran lesi odontoma dan tahapan perkembangan gigi permanen yang terlibat. **Tujuan:** Laporan kasus ini ingin menekankan pentingnya pengambilan compound odontoma sedini mungkin untuk memberi kesempatan tumbuhnya gigi permanen yang terlibat dan erupsi secara spontan. **Kasus:** Ditampilkan sebuah kasus compound odontoma pada regio maksila anterior menyebabkan gagal erupsi dan terlambatnya pembentukan akar gigi insisif kedua dan kaninus permanent rahang atas kanan pada penderita anak laki-laki berumur 10 tahun. **Tatalaksana kasus:** Dilakukan eksisi odontoma dengan pembiusan umum dan pemeriksaan histopatologi menunjukkan lesi tersebut adalah compound odontoma. Dalam kurun waktu 3 tahun pasca pembedahan kedua gigi permanen yang impaksi dapat erupsi sempurna secara spontan disertai dengan berlanjutnya proses pembentukan akar. **Kesimpulan:** Pengambilan odontoma dapat menyebabkan erupsi secara spontan gigi permanen yang impaksi dengan syarat proses pembentukan akar gigi yang bersangkutan belum selesai.

Kata kunci: Odontoma, delayed root formation, erupsi spontan

Correspondence: Achmad Harijadi, c/o: Departemen Bedah Mulut dan Maksilofasial, Fakultas Kedokteran Gigi Universitas Airlangga, Jl. Mayjend. Prof. Dr. Moestopo No. 47 Surabaya 60132, Indonesia. E-mail: hariadioesodo@yahoo.com

INTRODUCTION

Odontoma is a pathologic entity known as hamartoma of odontogenic origin, malformation tumor, representing 22% of the odontogenic tumors.¹ Odontomas are the most common benign odontogenic tumors of epithelial and mesenchymal origin. They are composed of mature enamel, dentin, and pulp and may be termed as "compound" or "complex", depending on the extent of morphodifferentiation or on their resemblance to normal teeth.²

Compound odontomas are usually located in the anterior part of the mouth, either over the crowns of unerupted teeth or between the roots of erupted ones. Radiographically, the lesions are usually unilocular, containing multiple radiopaque structures that resemble miniature of teeth which may vary from as few as 2 to 3 miniature tooth-like structures or as many as 20 to 30.² Complex odontomas, on the other hand, are commonly found in the posterior part of the mandible over impacted posterior teeth and can attain sizes up to several centimeters.³ They appear as a solid unilocular, radiopaque mass exhibiting some nodularity and are surrounded by a thin radiolucent zone and a distinct line of cortication, and there is no individual toothlike structures.^{1,3}

Compound odontomas are clinically presented as an asymptomatic, slow growing lesion, and in many cases they do not cause any swelling or facial asymmetry. Therefore, odontomas may grow undetected until diagnostic radiographs are made in cases where one or few anterior teeth fail to erupt. Surgical exposure and elimination of mechanical obstruction is frequently the treatment of choice and spontaneous eruption can then be expected.⁴

A compound odontoma in the anterior part of maxilla which has caused obstacle to normal eruption of two anterior permanent teeth is presented. Surgical excision of the tumor and the post operative follow-ups showed that there was no tumor recurrence and, in addition, it has gradually led to spontaneous eruption of the affected permanent teeth.

CASE

A 10 years old male patient came to a private clinic referred by his dentist for follow up treatment. The patient's parents complained that the unerupted upper right permanent lateral incisor and canine which had caused unacceptable appearance. Clinical examination showed that there was no facial asymmetry. Intra oral examination showed mixed dentition with very good oral hygiene, the upper right permanent lateral incisor and canine were missing with the space being occupied by upper right primary lateral incisor and canine (Figure1). Panoramic x-ray showed radiopaque lesion with tooth-like structure appearance displacing and causing impaction of the right upper permanent lateral incisor and canine (Figure 2).

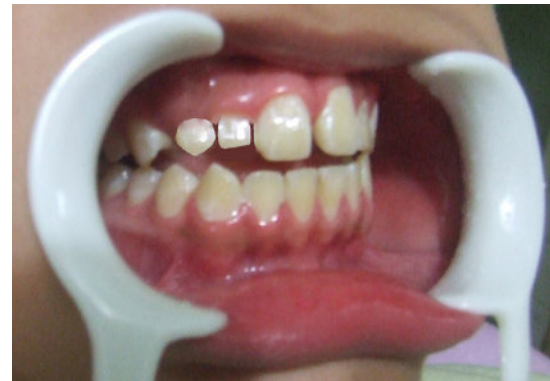

Figure 1. Intraoral view showing the non-exfoliating primary upper right lateral incisor and canine.

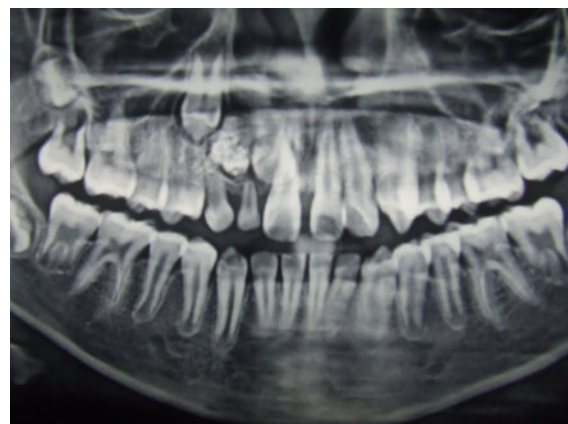


Figure 2. Panoramic radiograph showing the intact primary upper lateral incisor and canine and the compound odontoma obstructing the eruption pathway of permanent upper lateral incisor and canine.

Based on clinical and radiographic presentation the lesion was diagnosed as a compound odontoma.

CASE MANAGEMENT

The case was treated with extraction of the upper lateral primary lateral incisor and canine followed by surgical excision of the odontoma under general anesthesia. The lesion was found relatively large and attached to the adjacent teeth therefore it was cut into few pieces to facilitate its removal while minimizing the risk of damage to the adjacent structures. Upon excision of the lesion it was found many tooth-like structures with various forms and sizes (Figure 3). Histologic examination of the specimen showed that the lesion contained calcified matrix of bone tissue without the presence of odontogenic cells, no evidence of malignancy was found (Figure 4). The clinical appearance and histologic result of the lesion are consistent with those of compound odontoma.

Five weeks after the surgery the patient came back without any complaint. The wound had healed completely.

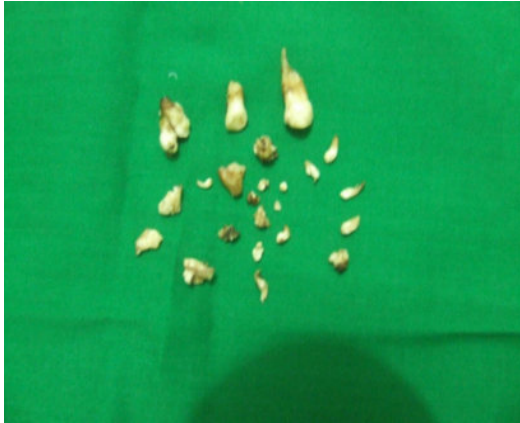

Figure 3. The specimen taken out from the operation site showing numerous miniature tooth-like structures indicating compound type of odontoma, together with

Panoramic radiograph showed that the upper right permanent lateral incisor had slightly moved in disto-incisal direction, and the upper right canine in mesial direction, both towards the space previously occupied by the lesion (Figure 5).

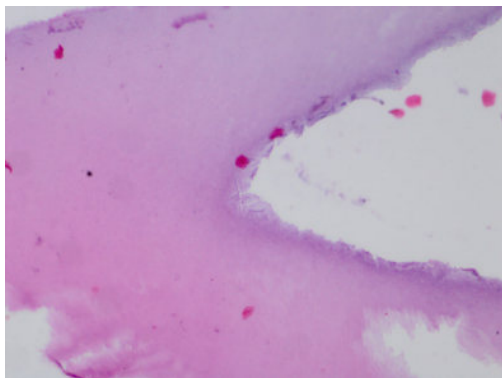


Figure 4. Microscopic view of the specimen showing calcified matrix of bone tissue without the presence of odontogenic cells.

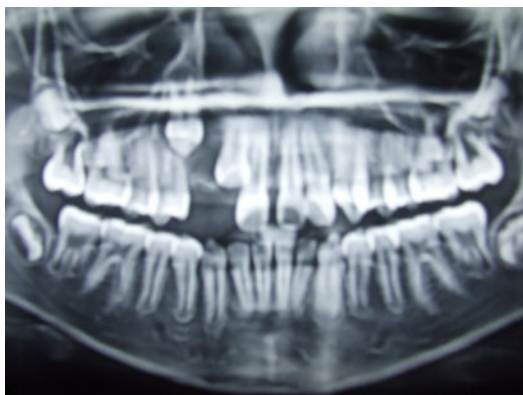


Figure 5. Panoramic radiograph six weeks after surgery showing the developing upper lateral incisor and canine start moving down towards the normal eruption pathway.

Fifteen months post operative review showed that the upper right permanent lateral incisor was clinically almost fully erupted while the canine was not visible. Panoramic radiograph showed that the upper right permanent lateral incisor was almost fully erupted with the root undergoing apex formation. The upper right permanent canine was on its way of eruption with the root being longer, compared with that prior to surgery, indicating an active root formation (Figure 6).

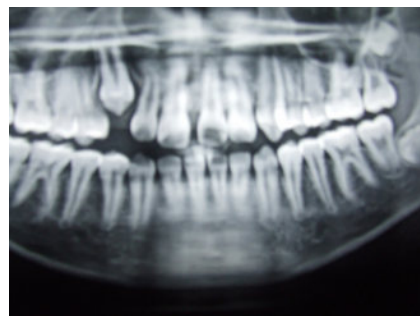
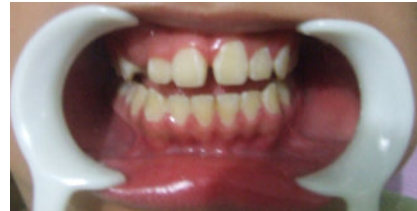

Figure 6. Clinical photograph fifteen months after surgery showing the erupting permanent upper lateral incisor (left); Panoramic radiograph fifteen months after surgery showing the fully erupted upper right permanent lateral incisor and canine on its erupting way (right).

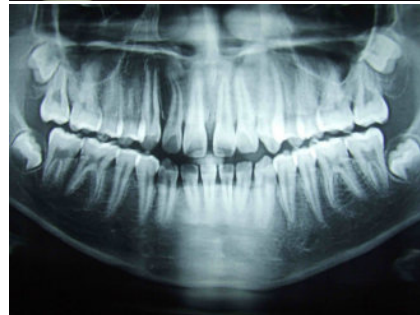
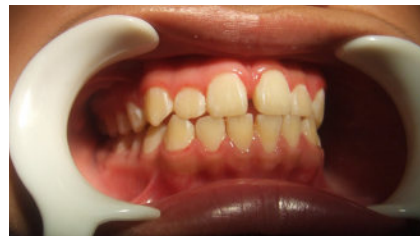
Figure 7. Clinical photograph 3 years after surgery showing the fully erupted and well aligned permanent upper lateral incisor and canine (left); Panoramic radiograph showing the fully erupted upper right permanent lateral incisor and canine which have not achieved complete root formation compared to their counterpart teeth (right).

The final review was made three years after the surgery. Clinically, both upper right permanent lateral incisor and canine were fully erupted and in good alignment. Panoramic radiograph showed that the roots of the upper right permanent lateral incisor and canine were much longer and almost attained their complete root formation, but their apices were not closed yet (Figure 7).

DISCUSSION

Odontoma are the most frequent benign odontogenic tumor in the oral pathology. They are generally asymptomatic and constitute casual findings in the course of routine radiological studies, particularly in the second and third decades of life.⁵ There are two types of odontomas: complex and compound odontomas, the latter being twice as frequent as the former. Compound odontomas show a predilection for the anterior sector of maxilla, while complex odontomas are typically found in the posterior mandibular region.^{2,6} This is in accordance with the odontoma in this case as it is found in the anterior maxilla and appeared as small tooth-like structures. Therefore it is classified as compound odontoma.

In this presented case the reason for which the patient's parents sought dental consult was the retention of two upper anterior primary teeth in addition to delayed eruption of two upper anterior permanent teeth, while the contralateral teeth had already well erupted. The cause of the problem could be revealed only after panoramic radiograph had been made which showed an odontoma in the right anterior maxilla causing displacement of the two unerupted anterior permanent teeth. This condition is appropriate with the previous studies, showing delayed tooth eruption.^{1,7}

The upper left permanent lateral incisor exhibited normal tooth development whereas the upper left canine was showed to have faster tooth development and eruption time. Normally, upper canines should appear intra orally between 11 and 13 years of age and complete their roots formation between 14 and 15 years of age.⁸⁻¹⁰ However, the upper left canine in this case had fully erupted clinically, reached occlusion and attained three quarter of its root length at the age of ten, which is one to three years ahead of its normal chronology. Interestingly and surprisingly, the two unerupted anterior maxillary teeth on the right side showed very much delayed root formation compared with those of the contralateral teeth. It seems logic to say that there should be some relation between the failure of tooth eruption and delayed tooth development in this presented case. One retrospective study seems to support this relation as the result showed that impaction of wisdom teeth can delay the root development.¹¹ Although the exact pathophysiology of this phenomenon is not understood yet, the difference in growth pattern, tooth development and eruption time of permanent dentition are common findings among different individuals and even in the same individuals. The interval from crown completion and the

beginning of eruption until the tooth is in full occlusion is approximately 5 years for permanent teeth.^{6,9}

The delayed root formation of the impacted upper right permanent lateral incisor and canine is considered advantageous in this case as it is believed to have important role in the spontaneous eruption of those affected teeth following removal of the odontoma. Although the exact mechanism has not been clearly understood, the role of incomplete root formation in spontaneous eruption of impacted teeth has been well documented. In a large clinical retrospective study of 140 intruded teeth, it was concluded that in the case of immature root development the best treatment would be observation with anticipation of spontaneous re-eruption.¹² In a retrospective study on the eruption of teeth associated with dentigerous cyst treated with marsupialization, Hyomoto *et al.*¹³ found that eruption potential was closely related to root formation, so that teeth with incomplete root formation had good potential to erupt, whereas those with complete root formation had less potential to erupt.

The spontaneous eruption of the upper right canine in this case into its final position within 3 years duration without any intervention is considered unusual based on the fact that it has been severely displaced away from its correct position by the presence of large odontoma. This phenomenon is contradictory to the result of a study by Ashkenazi *et al.*¹⁴ in which spontaneous eruption of the impacted teeth were significantly impeded if there is higher distraction of the apex of the impacted tooth relative to its estimated correct position and if the obstacle are in the form of tuberculated supernumeraries and odontomas. In their study most of the impacted teeth obstructed by odontomas had to be pulled out with orthodontic appliances into their final position.

The presence of compound odontoma during mixed dentition in the above case has created obstacle to the eruption pathway of two permanent anterior maxillary teeth and appeared to have seized their tooth development, i.e. root formation. After removal of the odontoma, the eruption process as well as the root formation of those teeth were continued until they came into occlusion and functioned normally. It is concluded that removal of odontoma may lead to spontaneous eruption of the affected teeth if their root development are not completed yet.

REFERENCES

1. Shafer WG, Hine MK, Levy BM. A textbook of oral pathology. 5th ed. Philadelphia: WB Saunders Co; 2005. p. 305-17.
2. Chong HL, Gyeong ju P. Complex and compound odontomas are clinico-pathological entities, basic and applied pathology. Departement of Oral and Maxillofacial Pathology, Dental College, Dankook University, Chungnam Korea. 2008. p. 30-3.
3. Sapp JP, Eversole LR, Wysocki GP. Cotemporary oral and maxillofacial pathology. 2nd ed. St. Louis: Mosby; 2004. p. 156-8.
4. Sanadettin D, Mustafa G, Özkan M. Compound odontoma associated with maxillary impacted permanent central incisor tooth: A Case report. The Internet Journal of Dental Science 2007; 5(2).
5. Sciubba JJ, Fantasia JE, Khan LB. Tumors and cysts of the jaw. Washington: Armed Forces Institute of Pathology; 2001. p. 117-20.

6. Steven DB. Compound and complex odontoma. USA: Emory University School of Dentistry, Atlanta, GA; 2005. p. 501–5.
7. Barnes L, Evenson JW, Reicart P, Sidransky D. World health organization classification of tumors. Pathology and genetics of head and neck tumors. Lyon: IARC Press; 2005. p. 310–1.
8. Avery JK, Steele PF. Oral development and histology. 3rd ed. New York: Thieme Med. Publ; 2002. p. 108–22.
9. McDonald R, Avery DR, Dean JA. Dentistry for the child and adolescence. 8th ed. St. Louis: Mosby; 2004. p. 175–9.
10. Pinkham JR, Casamassimo P, Fields Hu, Metique DJ, Maia A. Pediatric dentistry. Infancy through adolescent. 4th ed. St Louis Missouri: Elsevier Saunders; 2005. p. 190–3.
11. Reinhard EF, Ulbricht C, von Maydell AB. The influence of wisdom tooth impaction on root formation. *Ann Anat* 2003; 185(5): 481–92.
12. Andreasen JO, Andreasen FM, Andersson L. Textbook and color atlas of traumatic injuries to the teeth. 4th ed. Victoria: Willey-Blackwell; 2007. p. 432–3.
13. Hyomoto, Shear M, Speight P. Cysts of the oral and maxillofacial region. 4th ed. Oxford, UK: Blackwell Munksgaard; 2007. p. 75.
14. Ashkenazi, M, Greenberg BP, Chodik G, Rakocz M. Post operative prognosis of unerupted teeth after removal of supernumerary teeth or odontomas. *Am J Orthod Dentofac Orthop* 2007; 131(5): 614–9.