

Case Report

Calcium hydroxide as intracanal dressing for teeth with apical periodontitis

Sari Dewiyani

Department of Conservative Dentistry
Faculty of Dentistry Prof. Dr. Moestopo (B) University
Surabaya - Indonesia

ABSTRACT

Background: Root canal infection and periapical diseases are caused by bacteria and their products. Long term infection may spread bacteria throughout the root canal system. Apical periodontitis caused by infectious microbe that persistent in root canals can cause radiographic and histopathology periapical changes. Chemomechanical preparation and intracanal dressing then are recommended to be conducted and used in between visits to eliminate microbes in root canals. Calcium hydroxide ($\text{Ca}(\text{OH})_2$) can be used as intracanal dressing since it can be used as musical physical defense barrier to eliminate re-infection in root canal and to disturb nutrition supply for bacterial development. **Purpose:** The aim of this study is observe the effectiveness of $\text{Ca}(\text{OH})_2$ in treating endodontic teeth with apical periodontitis. **Cases:** Case 1 and 3 are about patients whose left posterior mandibular teeth had spontaneous intermittent pain. Case 2 is about a patient whose left posterior maxillary teeth had gingival abscess and fracture history. Based on the radiographic examination, it was known that the filling of root canal was incomplete and there was radiolucency in the apical area. **Case management:** The cases were treated with triad endodontics, which involves preparation, disinfection by using 2.5% NaOCl as irrigation substance and calcium hydroxide as intracanal dressing, and then the filling of root canal with gutta percha and endomethasone root canal cement. Evaluations were conducted one month, 12 months, and 24 months after the treatment. **Conclusion:** Calcium hydroxide is effective to be used as intracanal dressing in apical periodontitis cases.

Key words: Apical periodontitis, triad endodontic, intracanal dressing, calcium hydroxide

ABSTRAK

Latar belakang: Infeksi saluran akar dan penyakit periapiks disebabkan oleh mikroba dan produknya. Infeksi yang berlangsung lama memungkinkan bakteri masuk ke dalam seluruh sistem saluran akar. Periodontitis apikal disebabkan oleh infeksi persisten mikroba di dalam sistem saluran akar disertai perubahan radiografik dan histopatologik periapiks. Preparasi kemomekanis dan penggunaan obat saluran akar antar kunjungan sangat dianjurkan untuk mengeleminasi mikroba dalam saluran akar. Kalsium hidroksida merupakan obat saluran akar karena dapat berperan sebagai barrier pertahanan fisik, mencegah infeksi ulang dan mengganggu suplai nutrisi untuk perkembangan bakteri. **Tujuan:** Untuk membuktikan efektifitas kalsium hidroksida pada perawatan gigi dengan periodontitis apikal yang disertai dengan keluhan sakit dan adanya gambaran radiolusensi di periapikal. **Kasus:** Kasus 1 dan 3 adalah penderita dengan keluhan gigi belakang bawah kiri sakit dengan nyeri spontan hilang timbul, kasus 2 adalah penderita yang gigi depan atas terdapat benjolan di gusi dan riwayat fraktur. Pada pemeriksaan radiografis terlihat pengisian saluran akar yang tidak sempurna dan gambaran radiolusensi di apikal. **Tatalaksana kasus:** Pada kasus ini dilakukan tindakan triad endodontik, yaitu preparasi saluran akar, desinfeksi dengan larutan irigasi NaOCl 2,5% dan obat intrakanal kalsium hidroksida disertai dengan pengisian saluran akar dengan gutta percha dan semen saluran akar endomethason. Evaluasi dilakukan 1 bulan, 12 bulan, dan 24 bulan. **Kesimpulan:** Kalsium hidroksida efektif sebagai obat intrakanal pada kasus periodontitis apikal.

Kata kunci: Periodontitis apikal, triad endodontik, obat intrakanal, kalsium hidroksida

Correspondence: Sari Dewiyani, Bagian Konservasi Gigi, Fakultas Kedokteran Gigi Universitas Prof. Dr. Moestopo (B). Jl. Bintaro Permai Raya 3 Jakarta 12330, Indonesia. E-mail: sari.drg@gmail.com

INTRODUCTION

Root canal infections and periapical diseases are actually caused by microbes and their products. Long term infection can not only make bacteria spread through root canal system, either within ramifications, isthmus, or dentin tubules, but also can make microbes remain alive through chemomechanical preparation.¹ It means that through chemomechanical preparation can reduce the number of microbes inside the root canal, about 50-70%, the microbes can still survive, especially in the dentin tubules. Thus, the use of root canal dressing in between visits is highly recommended in order not only to prevent microbes from breeding, but also to kill them simultaneously inside the root canal.^{2,3}

Apical periodontitis is a periapical disease caused by persistent microbiology in root canals followed with radiographic and histopathology periapical changes which can cause bone damage.⁴ According to another expert's opinion, apical periodontitis is periapical defense response that can be treated by localizing the infection in order not only to prevent microbes from spreading, but also to eliminate microbes from necrotic root canal caused by microorganisms and their biofilm.^{3,5}

Calcium hydroxide, furthermore, can be used as a intracanal dressing since it has the ability to kill bacteria.⁶ It is because of the constant releasing of hydroxyl ions which can inhibit microbial lipopolysaccharide, as a result, it can reduce inflammatory process, dissolve the remaining necrotic tissue, and make an acidic environment become alkali that can stimulate the growth of bone.⁷ Therefore, calcium hydroxide as intracanal dressing has alkaline character which is considered as effective disinfectants and has useful osteogenic ability to heal periapical tissue.^{8,9}

For those reasons, the purpose of this treatment is to prove the effectiveness of calcium hydroxide as intracanal dressing on teeth with apical periodontitis.

CASE

Case 1: A 65 year old male patient came with complaint of spontaneous intermittent left posterior mandibular tooth pain suffered since one month before. Actually, the tooth was treated six months before. The pain sometimes also occurred on tooth next to it. Based on clinical examination, it was known that tooth 35 was restored with porcelain crown, and not sensitive with thermal and palpation tests, but still sensitive with percussion test. Based on radiographic examination, it was also known that the root canal of tooth 35 restored with porcelain crown was filled with gutta percha, but not in accordance with its length. Furthermore, it was known that the periodontium was widened; lamina dura was thickened; and there was no radiolucency in the apical area. Based on diagnosis, it was known that tooth 35 was pulpless with chronic apical periodontitis.

Case 2: A 27 year old male patient came with complaint of intermittent anterior maxillary tooth pain. The patient also complained about gingival abscess which tasted salty. Moreover, it was known that the tooth was fractured ten years before because of motorcycle accident, and then was treated in Medan, but not completed. Four years ago, the tooth then got dental crown restoration, but it still has been painful until now. Based on clinical examination, it was known that there was dental fistula in the gingival/buccal mucosa of tooth 21. It was also known that the tooth did not react with thermal tests, but still reacted with percussion and palpation tests. Based on radiographic examination, it was known that dental caries in tooth 21 had already reached the pulp; the periodontium was widened; lamina dura was thick and broken; and there was radiolucency in periapical area. Based on diagnosis, it was known that tooth 21 got chronic apical periodontitis with acute exacerbation from pulp necrosis.

On the other hand, the dental crown of tooth 22 was acrylic. Moreover, it did not react with thermal and palpation tests, but still reacted with percussion test. Based on the radiographic examination, it was known that dental caries of tooth 22 had already reached the pulp; periodontium widened; lamina dura was thick and broken; and there was also radiolucency in the periapical area. Based on diagnosis it was known that tooth 22 got chronic apical periodontitis because of untreated pulp necrosis.

Case 3: A 61 year old male patient came with complaint of spontaneous intermittent left lower back tooth pain suffered since 2 weeks ago sick. Moreover, it was known that the tooth was treated 5 years before. It was also known that the crown of tooth next to it was lost, but without any complaints. Thus, the patient had his teeth treated. Based on clinical examination, furthermore, it was known that teeth 34, 35 had already got porcelain crown restorations, and did not react with thermal and palpation tests, but still reacted with percussion test. Besides that based on radiographic examination, it was known that tooth 34 got post-core restoration with porcelain crown. It was also known that the periodontium was widened; lamina dura was lost; and there was no radiolucency in periradicular area. Based on diagnosis, finally, it was known that tooth 34 got chronic apical periodontitis because of pulp necrosis.

On the other hand, based on radiographic examination, it was known that the root canal of tooth 35 was filled less than its length; periodontium widened; lamina dura was thick and broken; and there was no radiolucency in its periapical area. Based on diagnosis, finally, tooth 35 no pulp tissue with chronic apical periodontitis. Therefore, tooth 35 needed root canal re-treatment with post-core restoration by using porcelain crown.

CASE MANAGEMENT

Case 1: Based on the case management procedures, the root canal retreatment of tooth 35 was conducted with




Figure 1. Case 1 teeth 34, 35. a) In the first visit, b) 6 months after treatment, c) 2 years after treatment.

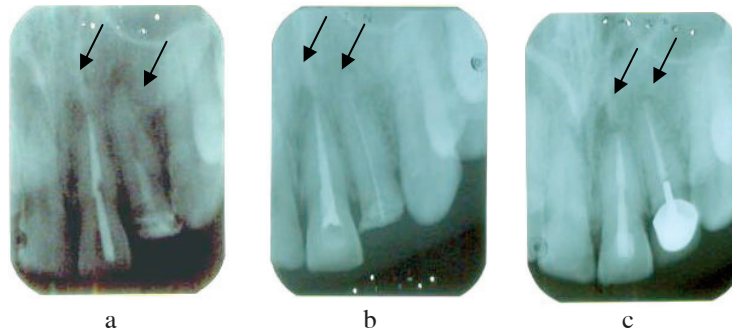


Figure 2. Case 2 teeth 21, 22. a) One month after treatment, b) 6 months after treatment, c) 2 years after treatment.

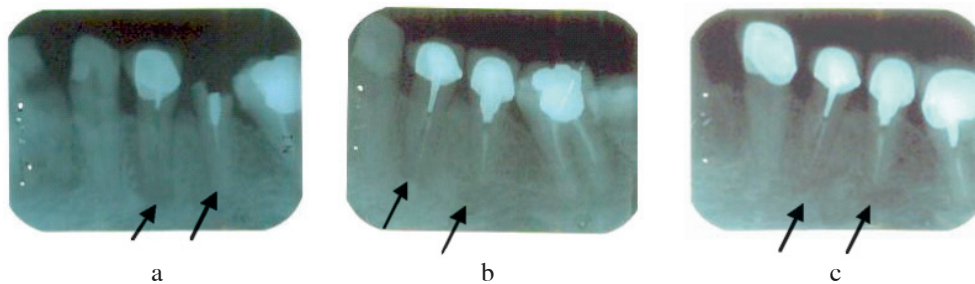


Figure 3. Case 3 teeth 34, 35. a) In the first visit, b) One year after treatment, c) 2 years after treatment.

porcelain crown restoration (Figure 1a). From the first to the third visit, the porcelain crown was demolished, and the root canal preparation was also conducted, in which it was irrigated with 2.5% NaOCl, dried, then filled with calcium hydroxide, and finally casted temporarily. A week later, the measurement of working length was conducted with x-ray images; Master Apical Cone (MAC) 30/25 was also determined; step-back was prepared and irrigated with 2.5% NaOCl; then the root canal was dried and filled with intracanal dressing, calcium hydroxide, and finally the cavity was closed with a temporary cast. In the fourth visit, moreover, the root canals of tooth 35 were filled. Besides that, it was known that dental caries on occlusal and proximal next to distal of tooth 34 reacted with thermal and percussion tests, but not reacted with palpation test. Based on the radiographic image of tooth 34, furthermore, it was also known that dental caries had already reached to the pulp chamber, and periodontium was dilated, but the lamina dura was still normal.

Therefore, tooth 34 was diagnosed with chronic dental pulpitis. Based on the case management procedure of tooth 34, root canal treatment was conducted with post-core restoration by using porcelain crown (Figure 1a). In the first visit, the root canal of tooth 34 was prepared and filled with calcium hydroxide as intracanal dressing. In the second visit, the root canal of tooth 3.4 was filled with gutta percha and root canal cement. After the root canal of both teeth was filled, in the third visit teeth 34 and 35 was casted with porcelain crowns. The re-examination was then conducted 2 years later in which it was known that there was no complaint of pain; it also did not reacted with percussion and palpation test; and finally there was also no radiolucency in periradicular area (Figures 1a, b, and c).

Case 2: Based on the case management procedures, the root canal treatment of tooth 21 was conducted with prophylactic post restoration with composite resin cast. From the first visit to the fourth one, the root canal preparation of tooth 21 was conducted with IF 45/21 mm.

It then was irrigated with 2.5% NaOCl, dried, and finally filled with calcium hydroxide as intracanal dressing. After that, the cavity was casted with temporary cast. In the next visit, based on x-ray images, MAC was 60/21 mm, and it was irrigated with 2.5% NaOCl, dried, and filled with calcium hydroxide medicine. Afterwards, the cavity was covered with temporary cast. In the fifth visit, finally, the root canal of tooth 21 was filled with gutta percha and root canal cement.

On the other hand, the root canal treatment was also conducted on tooth 22 with post-core restoration by using porcelain crown (Figure 2a). In the first visit, the root canal preparation of tooth 22 was conducted. Then, unlike the root canal of tooth 21 which got prophylactic preparation and composite cast, the root canal of tooth 22 was irrigated with 2.5% NaOCl, dried, filled with calcium hydroxide, and finally casted with temporary cast. In the third visit, the root canal of tooth 22 then was filled with MAC 35/24 mm. In the next visit, the porcelain crown insertions of teeth 21 and 22 were conducted. In the control visit of teeth 21, 22, two months after the treatment, there were no reaction with percussion and palpation tests, and there was also no subjective complaint. Finally, the re-examination of teeth 21, 22 was conducted two years later in which it was known that there was no subjective complaints; it did not react with percussion and palpation tests; and the image of radiolucency in the apex area was smaller. (Figure 2-a, b, and c).

Case 3: Based on the case management procedure of tooth 34, the root canal treatment was conducted with post-core restoration by using porcelain crown. From the first to the fourth visit, the previous post-core crown restoration of the tooth 34 was demolished in order not only to prepare access for root canal preparation, but also to be irrigated with 2.5% NaOCl, then dried and filled with intracanal calcium hydroxide dressing, and temporarily casted. In the next visit, the measurement of working length was conducted with x-ray images. MAC the was determined, 30/18 mm, and step back was conducted and irrigated with 2.5% NaOCl, then dried, and filled with calcium hydroxide as intracanal medicine. Afterwards, the cavity was finally closed with a temporary cast. The root canal of tooth 34 then was filled with root canal sealer and gutta percha. In the next visit, the preparation was conducted on tooth 34 in order to make post-core.

In the first control visit, the prophylactic post of the tooth 3 was demolished in order to repair root canal preparation through irrigation with 2.5% NaOCl, and filled with calcium hydroxide as intracanal medicine. In the fourth control visit, the root canal of the tooth 35 was filled by using endomethasone root canal sealer. In the sixth visit, the teeth 34 and 35 were restored with post-core cast, by using porcelain crowns. In control visits conducted 1 and 2 years after the treatment, there was no subjective complaints; there were no reaction with percussion and palpation tests; and there was no radiolucency in periradicular area (tooth 34) (Figure 3a, b, and c).

DISCUSSION

Microorganisms can reach dental pulp through caries, inappropriate clinical procedures (leak restoration, excessive instrumentation, and chemical or endodontic material irritation), fracture, and traumatic occlusion. As a result, it can cause a continuous response followed with clinical symptoms, such as aches and pains. And, when inflammatory process almost attacks pulp-periapical junction tissue, periodontitis will occur in apical.¹⁰

Apical periodontitis is a periapical defense response against pulp tissue damage because of microbial infection in root canal system which is aimed both to localize the infection in the root canal system and to prevent its spreading. Although this defensive reaction can minimize the spread of infection, this reaction still cannot eliminate the microbes that infiltrated into the necrotic root canal because it is protected by biofilm.¹¹

This apical periodontitis treatment can conventionally be conducted with endodontic treatment. The purpose of this treatment, moreover, is not only to eliminate or reduce microbial populations in the root canal system, but also to reduce and prevent re-infection by blocking the root canal. The combination of mechanical instruments, root canal irrigation, and anti-microbial drug application in root canal can reduce the number of microbes. Calcium hydroxide as a intracanal dressing, furthermore, can create a good environment for healing the periapical tissues, stimulating the hard tissue formation, eliminating exudation in the periapical area, and dissolving necrotic tissue.¹² The success of this pulp treatment, however, is determined by the examination and ability to eliminate causative factor and to cut infected tissue so that biological recovery process on the tissue can occur.^{12,13}

In addition, diagnosis in case 1, 2 and 3 were established based on the patients' complaints and their radiographic images. Their complaints of intermittent pain involving discomfort feeling, severe pain in those teeth, and infection spreading into the periapical tissue. The pain can also possibly caused by the filling of the root canal that is not appropriate with the working length (case 1, 3).

Besides that, the use of improper instruments in root canal because of wrong measurement can also push dentin debris, irrigation solutions, toxic components of necrotic tissue into the periapical, and the excessive use of intracanal dressing (in case 2). For example, necrotic tissue still remained in one-third apical of the root canal (in case 1 and 3), and the use of inappropriate mechanical instruments and intracanal medicine causing irritations (case 2) become the focus of infection that causes the inflammation of periapical, which is apical periodontitis.¹⁴

The root canal re-treatment was then conducted in those three cases which aims not only to reduce or eliminate microbes in the root canal system, but also to prevent re-infection. The re-use of calcium hydroxide, thus, is essential in the process of mineralization and its antimicrobial effect. It is because the increasing of concentration caused by

calcium hydroxide can initiate the mineralization process since high concentration with a combination of the ability of Ca^{2+} ions and OH^- can cause an effect on the metabolic enzymes and mineralization processes. Therefore, it means that calcium hydroxide can increase the metabolic processes of the periapical tissue, including collagen synthesis, glycosaminoglicans, and protein synthesis.¹⁵

Furthermore, another reason of using calcium hydroxide as intracanal medicine is because it has qualities in both hydrolyzing some fats derived from bacterial lipopolysaccharide and eliminating its biological action.⁷ Calcium hydroxide is also used to control the exudate (in case 2) with persistent periapical abnormalities. The high concentration of Ca ions then can cause pre-capillary contraction so that the flowing of blood to capillaries is reduced. This condition then can affect the reduction of fluid amount that comes out of plasma into the tissue as a result of inflammatory reaction. With the reduction of plasma fluid that comes out, the tissue can possibly get the healing and calcification processes.¹²

As a result, the healing process then occurred in case 1, 2 and 3, which was about two years after the root canal treatment. The filling of calcium hydroxide dressing into the pulp tissue can stimulate mesenchyme cells to form fibroblasts to arrange new odontoblast cells that can both replace the damaged cells and support the smooth vascularization. Ca^{2+} ions in high concentrations will not only improve the role of pyrophosphatase enzyme, activate adenosine, but also activate triphosphatase so that they can force defense through dentin mineralization.¹⁶⁻¹⁸ It can be concluded that calcium hydroxide can effectively be used as intracanal medicine in apical periodontitis cases.

REFERENCES

- Walton RE, Riviera EM. Cleaning and shaping. In: Walton RE, Torabinejad M, eds. Principles and practice of endodontic. 3rd ed. Philadelphia: WB Saunders; 2002. p. 206–38.
- Schafer E, Bossmann K. Antimicrobial efficacy of chlorhexidine and two calcium hydroxide formulation against *Enterococcus faecalis*. J Endod 2004; 31: 53–6.
- Basrani B, Pascon E, Friedman S. Efficacy of chlorhexidine and calcium hydroxide containing medicament against *Enterococcus faecalis* in vitro. J Oral Surg Oral Med Oral Pathol 2003; 96: 618–2.
- Jiang J, Zoo J, Chen SH, Holliday LS. Calcium hydroxide reduces lipopolysaccharide stimulated osteoclast formation. Oral Surg Oral Med Oral Pathol 2003; 95: 348–54.
- Ingle JL, Simon JH. Endodontic. 5th ed. California: Elsevier; 2002. p. 179–884.
- Podbielski A, Spahr A, Haller B. Additive microbial activity of calcium hydroxide and chlorhexidine on common endodontic bacterial pathogens. J Endod 2003; 29: 340–5.
- Cwikla S, Bellanger M, Giguere S, Fox A, Verticci F. Dentinal tubules disinfection using three calcium hydroxide formulation. J Endod 2000; 31: 50–2.
- O'Brien, William J. Dental material and their selection. 3th ed. Chicago: Quintessence Publishing Co, Inc; 2004. p. 141.
- Weine FS. Histophysiology and diseases of the dental pulp. Endodontic therapy. 5th ed. Toronto: Mosby; 2004. p. 161–73.
- Amanda L, Harrod M. An evidence base analysis of the antibacterial effectiveness intracanal medicaments. J Endod 2004; 30: 689–94.
- Distel JW, Hatton JF, Gillerspie MJ. Biofilm formation in medicated root canals. J Endod 2002; 28: 689–93.
- Akbar SMS. Perawatan endodontik. Jakarta: FKG UI; 2009. p. 1–29.
- Teixeira, Fabricio B. Investigation of pH at different dentinal sites after placement of calcium hydroxide dressing by two method. Oral Surg Oral Med Oral Pathol Endodontology 2005; 99–516.
- Hommez GM, Giard JC, Hartke A, Flahaut S. The relation between apical periodontitis and root-filled teeth in patient with periodontal treatment need. J Endod 2006; 39: 299–304.
- Jaunberzins A, Gutmann JL, Witherspoon DE, Harper HP. Effects of calcium hydroxide and tumor growth factor- β on collagen synthesis in subcultures I and of osteoblast. J Endod 2000; 26: 494–9.
- Sidharta W. Penggunaan kalsium hidroksida di bidang Konservasi Gigi. JKGUI 2000; 7 (Edisi khusus): 435–43.
- Berkitten M, Okar I, Berkitten R. In vitro of penetration of Sanguish and *Prevotella intermedia* strain into human dentinal tubulus. J Endod 2000; 26: 236–9.
- Ferreira FB, Vale MS, Granjeirob JM. Evaluation of pH levels and calcium ion release in various calcium hydroxide endodontic dressing. Oral Surg Oral Med Oral Pathol 2003; 97: 388–92.