

Case Report

Orthodontic treatment with skeletal anchorage system

Arya Brahmanta¹ and Jusuf Sjamsudin²¹Department of Orthodontics, Faculty of Dentistry University of Hang Tuah²Department of Orthodontics, Faculty of Dentistry University of Airlangga
Surabaya - Indonesia

ABSTRACT

Background: Correction of class I malocclusion with bimaxillary dental protrusion and unilateral free end right upper ridge in adult patient is one of difficult biomechanical case in orthodontics. Due to this case that needs proper anchorage for upper incisor retraction with missing teeth in the right posterior segment. **Purpose:** The aim of this study to find an effective therapy for correction of bimaxillary protrusion with unilateral free end ridge. **Case:** A female patient, 36 year old complaining for the difficulty of lip closure due to severe bimaxillary protrusion with incompetence lip. **Case management:** Firstly correction of the maxillary and mandibular incisor proclination were done by extraction of the mandibular first premolar, the maxillary second premolar on left side and finally placement of miniplates implant in the zygomatic process on right side as an absolute anchorage. **Conclusion:** Skeletal anchorage system (SAS) can be considered as an effective therapy for correction of bimaxillary protrusion with unilateral free end ridge.

Key words: Skeletal anchorage system, bimaxillary protrusion, unilateral free end ridge

ABSTRAK

Latar belakang: Koreksi dari maloklusi klas I dari penderita dewasa yang disertai protrusi bimaksiler dengan kehilangan gigi posterior pada regio kanan atas merupakan salah satu kasus sulit untuk dikerjakan terutama berhubungan dengan biomekanik pergerakan giginya dalam perawatan ortodonti. **Tujuan:** Tujuan dari penulisan artikel ini adalah untuk menemukan terapi yang efektif untuk perbaikan protrusi bimaksiler dan kehilangan gigi posterior pada satu sisi. **Kasus:** Seorang penderita wanita usia 35 tahun datang dengan keluhan utama kesulitan untuk menutup mulut oleh karena gigi rahang atas dan rahang bawahnya maju dan bibirnya tidak kompeten. **Tatalaksana kasus:** Koreksi pada gigi insisivus rahang atas dan insisivus rahang bawah yang protrusi dilakukan dengan melakukan pencabutan terlebih dahulu pada gigi premolar pertama dirahang bawah sisi kanan dan sisi kiri serta pencabutan pada gigi premolar kedua di rahang atas sisi kiri dan pemasangan miniplate implant di regio prosesus zigomatikus di sisi kanan sebagai penjangkar absolut. **Kesimpulan:** Sistem penjangkar absolut pada perawatan ortodonti merupakan pilihan terapi perawatan yang efektif pada kasus penderita dewasa dengan protrusi bimaksiler dan kehilangan gigi posterior pada regio kanan atas.

Kata kunci: Sistem penjangkar absolute, protrusi bimaksiler, kehilangan gigi posterior satu sisi

Correspondence: Arya Brahmanta, c/o: Bagian Ortodonti, Fakultas Kedokteran Gigi Universitas Hang Tuah. Jl. Arif Rahman Hakim 150 Surabaya, Indonesia. Email: arya.brahmanta@yahoo.com. Telp. (031) 5912191.

INTRODUCTION

Orthodontics anchorage can also be explained by the third law of Newton which stated, every action creates reaction and reaction is equal in size and opposite in direction. The anatomic unit, antagonizes the active force

and is being called as anchorage in orthodontics.¹ Anchorage preparation is a very important in orthodontic treatment. The success of orthodontics treatment generally depend on the anchorage protocol, especially for particular case. To prepare good anchorage, the clinician must be realistic to predict the possibility of anchorage loss. Anchorage loss

is a consequences from unstable construction and lack of patient cooperation as well. Type of anchorage based on the type of tooth movements.^{1,2}

Anchorage is the greatest problems in orthodontics. Orthodontists always faced with difficulties in trying to achieve maximal anchorage due to the orthodontic movements in response to orthodontic forces. Therefore, to maximize the anchorage, patients need to use headgear as additional anchorage. Reinforced anchorage with extraoral appliances has severe limitations because it requires excellent patient compliance.^{2,3}

The use of implants in orthodontic involves tooth replacement or intraoral rigid anchorage assistance in the movement of teeth. Recent developments in osseointegration made it possible to use implants for orthodontic anchorage. Since the implant is known like an ankylosed tooth, it can be used as a reliable anchorage unit for orthodontic tooth movements. Experimental biomechanic studies on animal models and clinical investigations showed that dental implants placed in the alveolar bone is resistant to orthodontic force.³

It is important to achieve maximal anchorage in correction of severe maxillary protrusion especially in cases with excessive molar anchorage loss on free end ridge. Skeletal anchorage system (SAS) was developed for correcting Class II malocclusions with maxillary protrusion. Using this system, the anterior retraction can be done without unfavorable side effects.⁴

The purpose of this article is to deliver a case of an adult patient with severe bimaxillary protrusion, treated with SAS.

CASE

A patient 36 year old woman, presented a bimaxillary dental protrusion with class I malocclusion and unilateral free end ridge on upper arch came to the orthodontic specialist clinic at Airlangga University Dental Hospital. She complained complaining about the difficulty of lip closure due to severe bimaxillary dental protrusion. Her facial profile was convex with a protrusive upper lip without facial asymmetry. Over jet and over bite 2 mm (Figure 1-b). Occlusal contact recognized only at the premolar and molar on the left side (Figure 1-c). There is no occlusal contact at premolar and right molar. The upper left first molar, second molar and lower first molar were missing (Figure 1-a, e).

Cephalometric analysis showed a skeletal class I jaw base relationship SNA 88°; SNB 84°; ANB 4°. The facial profile was convex FH-NP 88°; NAP 10°; Y-Axis 62.5°. The upper and lower incisor were labially inclined I-NA line 11.5 mm; I-NA angle 35°; I-NB line 16 mm; I-NB angle 45°; Interinsisal angle 96°. The mandibular plane angle was steep 30° and the gonial angle was large 110° (Figure 1-d).

CASE MANAGEMENT

The case was diagnosed as class I malocclusion with bimaxillary dental protrusion and unilateral free end right upper ridge, skeletal class I jaw base relationship. The treatment objectives were extraction of the bilateral

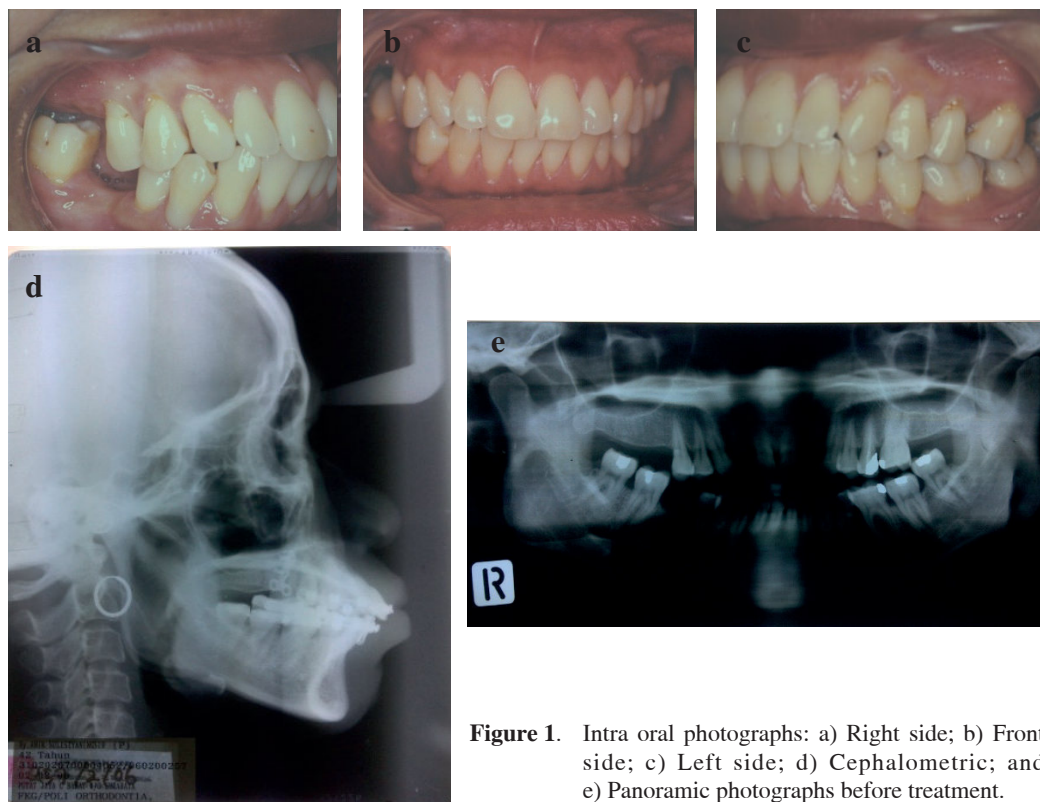


Figure 1. Intra oral photographs: a) Right side; b) Front side; c) Left side; d) Cephalometric; and e) Panoramic photographs before treatment.

mandibular lower first premolar and the maxillary second premolar because it is in poor condition. Placement of Edgewise standart braket with 0.018 inch slot on upper and lower arch, followed by placement of miniplates implant in the zygomatic process as an absolut anchorage. Correction of the maxillary and mandibular incisor by retraction using elastik chain. Retention using Hawley retainer in both jaws.

Before starting orthodontic treatment, the patient received periodontal treatment. Periodontal treatment involved oral hygiene instruction and scaling. The upper

left second molar was extracted because of poor condition. Bilateral mandibular lower first premolar were extracted to gain space for retraction.

Initial phase was levelling with 0.012 inch round NiTi archwire. After leveling with a 0.016 inch NiTi arch wire, the miniplates implanted onto the zygomatic process of the maxilla through buccal mucosa (Figure 2-a,b). The miniplates contoured to fit the bone surface. The head portion of miniplates intraorally exposed and positioned outside the dentition (Figure 2-c).

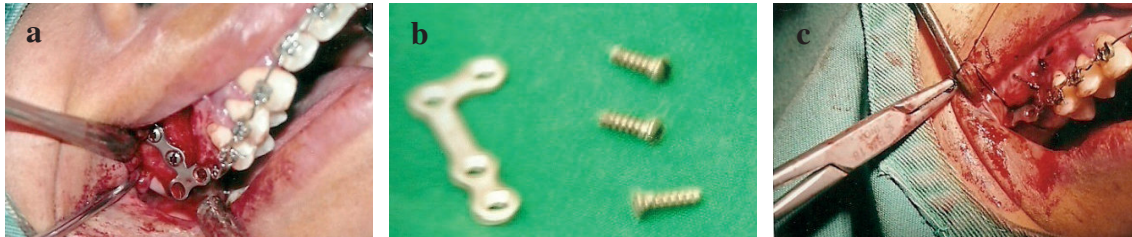


Figure 2. The miniplates implant placement on to zygomatic process a) Miniplates implant placement; b) miniplates implant; and c) suturing

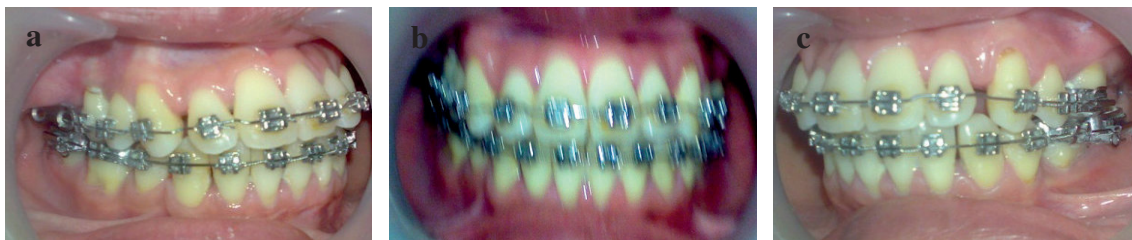


Figure 3. Treatment progress a) right side; b) front side; and c) left side.

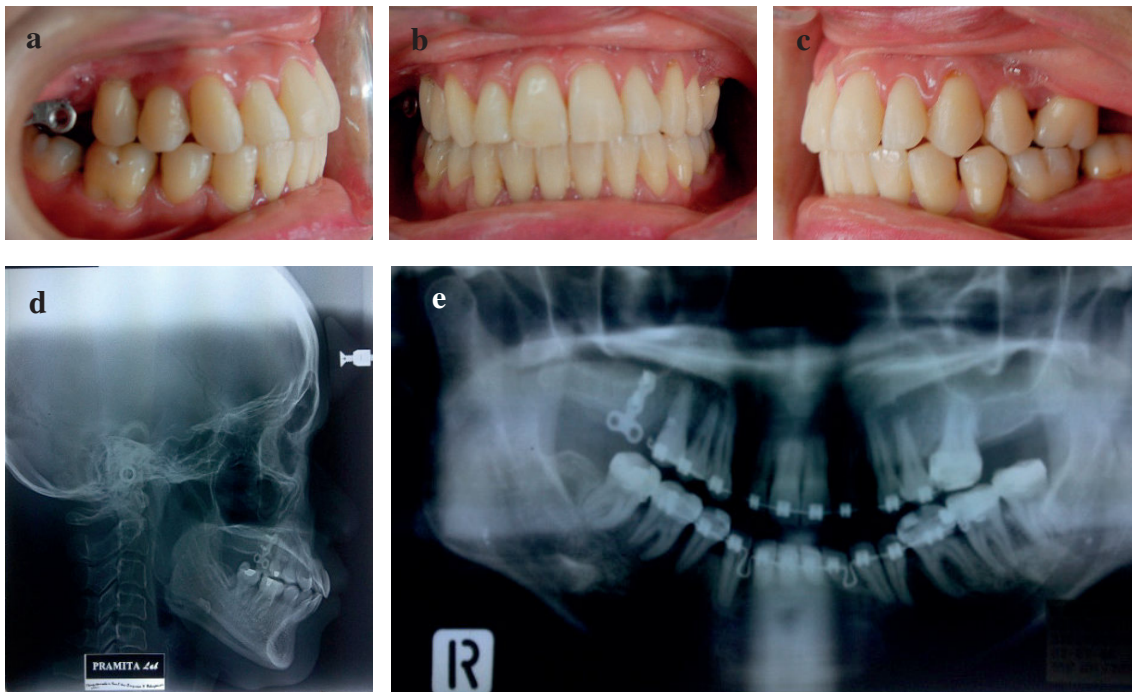


Figure 4. Intra oral photographs: a) right side; b) Front side; c) Left side; d) Cephalometric; and e) Panoramic photographs after treatment.

After a month of healing, integration and adaptation retraction of the anterior teeth was started with elastic chain. An elastic chains was applied from the upper right premolar region to the miniplate as absolute anchorage for retraction with sliding mechanic (Figure 3-a, b, c).

This treatment made spacing in the upper dentition were closed. The upper incisor inclined palatally and the lower incisor lingually inclined. Acceptable occlusion achieved and the overjet and overbite come to normal. The caninus relation were class I on the both sides (Figure 4-a, b, c).

Facial photographs showed overall facial balance was improved. The lips becomes less tension on closure (Figure 5-a, b, c, d). Cephalometric analysis by comparing the superimposing pretreatment and posttreatment cephalometric tracings is indicated the type of retraction movement of the maxillary incisor by relative movement of the incisor crown and the incisor root (Figure 4-d).

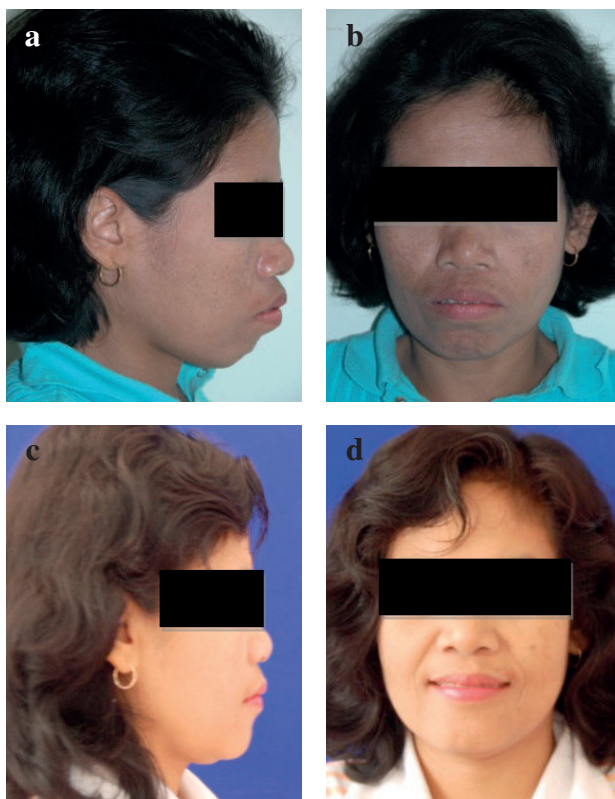

Figure 5. Facial photographs: a) Right side; b) Front side before treatment; c) Right side; and d) Front side after treatment.

Cephalometric superimposing analysis showed a normal SNA 86°; SNB 84°; ANB 2°. The facial profile was becoming straight FH-NP 85°; NAP10°; Y-Ax 62,5°; The upper and lower incisor have been corected: I -NA line 7 mm; 21°; I- NB line 12 mm; 40°; inter incisal 114°. Comparison the pretreatment and posttreatment cephalometric tracings showed that maxillary and mandibular incisor crown had moved posteriorly (Figure 6).

Retention phase with Hawley retainer provided acceptable occlusion. Facial profile was also maintained, indicating a stable occlusion (Figure 7).

DISCUSION

Facial esthetics is a major concern of many orthodontic patients. The negative impacts on the facial profile with upper lip protrusion often lead patients to seek orthodontic treatment. Increased upper lip procumbency is commonly associated with protrusive maxillary dentition in Angle

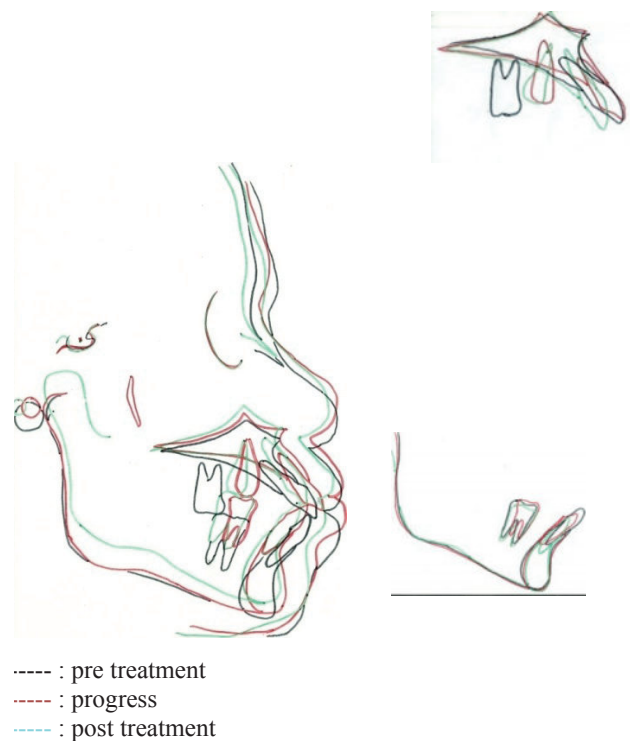


Figure 6. Superimposing cephalometric tracing.

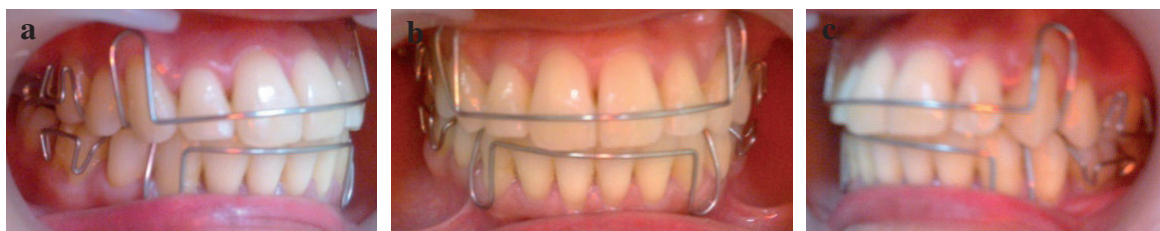

Figure 7. Retention phase: a) Right side; b) Front side; and c) Left side.

class II division 1 malocclusions and class I malocclusions with bimaxillary protrusion.²

In such circumstances, the major orthodontic treatment goal is to reduce the proclination of the maxillary incisors. Consequently, the treatment plan often includes extraction of the bilateral maxillary premolars, followed by retraction of the anterior teeth with maximum anchorage. Maximum anchorage was added to prevent forward movement of the maxillary posterior teeth during anterior teeth retraction and can be provided with different approaches.^{5,6}

Extraoral headgear are commonly used to reinforce posterior anchorage during anterior tooth retraction or are directly applied to retract anterior teeth. Full time headgear wearing is demanding for most patients, extraoral appliances are often rejected by adults for social reasons. Patients cooperation is an important factor for the effectiveness of extraoral appliances.^{6,7}

Application of bony anchorage for tooth movements is efficient, because it is not depending on patient cooperation in wearing extraoral appliance. Several methods of bony anchorage have been reported, such are: dental implants, titanium screws and miniplates. The use of miniplate implant for absolute anchorage has proved to have many advantages. Absolute anchorage makes the treatment plan more reliable and enables treatment time reduction. This anchorage system obviates the dependency on patient compliance.^{5,6,8}

Skeletal anchorage developed from mini plate implant are placed by screwing to engage the cortical bone. The most common areas for mini implant placement are in the zygomatic area and the buccal aspect of the body of the mandible.⁸

In this case, orthodontic treatment was performed in adult patient diagnosed as Angle class I malocclusion with bimaxillary dental protrusion and unilateral free end upper right posterior segment. The only option to correct the proclination of anterior teeth was to move the anterior teeth distally using absolute anchorage. Therefore, SAS offered the best benefit therapy choice. Miniplates were placed in the zygomatic process in the maxilla. The titanium L-shaped (hook of miniplates) facilitated adjustment of the direction of force to retract the upper incisors.^{9,10}

Patients with bimaxillary dental protrusion have specific characteristics, including incisor proclination and convex facial profile. To correct dentoalveolar protrusion, extraction of the premolar is indicated. The treatment mechanic for space closure of the extraction sites was closed by sliding mechanics. The use of miniplates as skeletal anchorage system for patient with insufficient teeth for anchorage is

almost 100% successful, if the right type of implant is used and the clinical situation is properly evaluated.¹⁰⁻¹²

Retraction of the maxillary incisor can be assessed by comparing pre treatment and post treatment on cephalometric tracings. The tipping control assigned by moving maxillary incisor crown posteriorly with the center of rotation at the root of the tooth. Uncontrolled tipping makes the maxillary central incisor crown move posteriorly although the roots move anteriorly. The mechanotherapy control was important for satisfactory correction of dentoalveolar protrusion, leading to a positive soft-tissue response, with lip protrusion reduction.^{11,12}

The patient's main complaints, in which difficulty of lip closure due to severe bimaxillary dental protrusion was improved by the treatment. Since the proclination was corrected, the upper lip became more relaxed and the lips showed less tension.

It is concluded that SAS can be considered as an effective therapy choice for correction bimaxillary dental protrusion with unilateral free end ridge.

REFERENCES

1. Keles A, Erverdi N. Bodily molar distalization with absolute anchorage. *Angle Orthod* 2003; 73: 471–82.
2. Nanda R. Biomechanics and esthetic strategies in clinical orthodontics. St. Louis: Saunders Elsevier; 2005. p. 295–309.
3. Sugawara J. JCO interviews, Dr. Junji Sugawara on the skeletal anchorage system. *J Clin Orthod* 2000; 33: 689–96.
4. Tanaka E, Sasaki-Nishi A, Hasegawa T, Nishio C, Nobuhiko K, Tanne K. Skeletal anchorage for orthodontic correction of severe maxillary protrusion after previous orthodontic treatment. *Angle Orthod* 2008; 78: 181–8.
5. Sugawara J, Nagasaka H, Umemori M, Mitani H, Kawamura H. Skeletal anchorage system (SAS). *Dental Outlook* 2002; 99: 397–406.
6. Lee JS. Application of orthodontic mini-implants. *Hanover Park, Quintessence* 2007; 7(179): 202–6.
7. Fukunaga T, Kuroda S, Kurosaka H, Yamamoto T. Skeletal anchorage for orthodontic correction of maxillary protrusion with adult periodontitis. *Angle Orthod* 2006; 76: 148–55.
8. Wahl N. Orthodontics in 3 millennia. Chapter 15: Skeletal anchorage. *American J Orthod and Dentofac Orthop* 2008; 134: 707–10.
9. Bong KC, Dong SC, Jang I, Brinkmann J, Peter Ngan. Maxillary protraction using miniplates as skeletal anchorage. *Hong Kong Dent J* 2010; 7: 87–93.
10. Yao CJ, Hualai EH, Chang C, Chen I. Comparison of treatment outcomes between skeletal anchorage and extraoral anchorage in adults with maxillary dentoalveolar protrusion. *Am J Orthod Dentofac Orthop* 2008; 134: 615–24.
11. Labanauskaitė B, Jankauskas G, Vasiliauskas A, Haffar N. Implants for orthodontic anchorage. Meta-analysis. *Stomatologija Baltic and Maxillofacial J* 2005; 7: 128–32.
12. Lee K, Leung C, Wong K, Rabie. Versatility of skeletal anchorage in orthodontics. *World J Orthod* 2007; 9: 221–32.