

Case Report

Aesthetic treatment on anterior teeth crown fracture caused by dental trauma

Nanik Zubaidah

Department of Conservative Dentistry
Faculty of Dentistry, Universitas Airlangga
Surabaya - Indonesia

ABSTRACT

Background: Complicated crown fracture is a tooth fracture that involve enamel, dentine and pulp. The incidence of complicated crown fracture ranges from 2% to 13% of all dental injuries and the most commonly involved teeth are the maxillary central incisors. Various treatment modalities are available depending on the clinical, physiological and radiographic examination of the involved teeth. **Purpose:** The aim of this case report is to present the management of crown fractures with pulpal exposure caused by traumatic injury, through endorestitution approach to reconstruct the shape and function of the teeth. **Case:** A 17 years old male with complicated crown fractures of anterior teeth #11 #21 and #22. The patient wish for aesthetic dental treatment in both of its form and function. **Case management:** Crown fractures of anterior teeth with exposed pulp caused by traumatic injury were reconstructed by endorestitution approach. The endodontic treatment with post and core insertion in the root canal which will increase its retention and porcelain fused to metal crown which will aesthetically recover its original form and function. After restoration the patient feel very glad and confident with the result. **Conclusion:** Endorestitution treatment on anterior teeth with complicated crown fractures and exposed pulp is able to recover the normal form, function and dental aesthetic in accordance with stomatognathic system and self confidence.

Key words: Traumatic dental injury, complicated crown fracture, endorestitution

ABSTRAK

Latar belakang: Fraktur mahkota kompleks (complicated) adalah fraktur pada mahkota gigi yang melibatkan enamel, dentin dan pulpa. Kejadian dari fraktur mahkota kompleks bervariasi antara 2-13% dari semua trauma gigi dan sebagian besar gigi yang terkena adalah gigi insisif pertama rahang atas. Berbagai macam cara perawatan yang dilakukan tergantung pada hasil pemeriksaan klinis, psikologis dan radiografis dari gigi yang terkena. **Tujuan:** Laporan kasus ini menjelaskan penatalaksanaan fraktur mahkota gigi dengan pulpa terbuka akibat trauma dengan perawatan endorestitusi untuk mengembalikan bentuk dan fungsi gigi. **Kasus:** Penderita pria umur 17 tahun dengan fraktur mahkota pada gigi anterior #11, #21 dan #22. Penderita tersebut menginginkan perawatan estetik untuk mengembalikan estetik baik bentuk maupun fungsi giginya. **Tatalaksana kasus:** Fraktur mahkota gigi anterior dengan pulpa terbuka akibat trauma gigi dikembalikan melalui pendekatan perawatan endorestitusi. Perawatan endodontik dengan pasak tuang dan inti yang dimasukkan ke dalam saluran akar akan meningkatkan retensi dan kemudian ditutup dengan mahkota porselen fused to metal dapat mengembalikan bentuk maupun fungsinya. Selesai perawatan, pasien merasa senang dengan hasil perawatan tersebut dan hal ini menunjukkan peningkatan kepercayaan diri pasien. **Kesimpulan:** Perawatan endorestitusi gigi anterior dengan fraktur mahkota kompleks gigi anterior dengan pulpa terbuka dapat mengembalikan bentuk, fungsi dan estetik yang normal sesuai dengan sistem stomatognatik dan meningkatkan kepercayaan diri.

Kata kunci: Jejas gigi traumatik, fraktur mahkota kompleks, endorestitusi

Correspondence: Nanik Zubaidah, c/o Departemen Konservasi Gigi, Fakultas Kedokteran Gigi Universitas Airlangga, Jln. Mayjend. Prof. Dr. Moestopo No. 47 Surabaya 60132, Indonesia. Email: nanikzubaidah@yahoo.com

INTRODUCTION

Dental traumatic injury treatment is an important aspect of dentistry. Dental traumatic injury occurs mostly in young patients with varying degrees of severity ranging from enamel fracture to avulsion that will affect psychologically to parents and children, especially if the injury affects permanent teeth and involves extensive loss of tooth structure.¹⁻³ The trauma, moreover, can also cause either damage to the pulp of teeth, with or without crown or root damage, or removal of teeth from the socket. Sweet stated that a high percentage of the anterior teeth in the upper jaw suffer from fractures, and 90% of which really stand out, so the lip can not adequately cover them.^{1,4}

Teeth can suffer from trauma caused by activities, such as falling off a bike, car accidents, crashes, domestic violence, sports or other causes that may lead to disability wound in individuals as well as various forms of fractures, including crown fracture and tooth root fracture. Crown fracture with open pulp involving enamel, dentin, and pulp known as complicated crown fracture.⁵ Complicated crown fracture occurs about 2-13% of all dental injuries, most of which involve maxillary first incisors.^{2,6,7} According to Chan,⁸ the frequency of fracture in permanent incisors occurs in children about 5-20%. The degree of the open exposed pulp can vary from a hole with needle size to a hole opened on coronal pulp. If the surface is left open, there will be necrosis process caused by bacterial contamination. The result of treatment depends on the extent of injury, the quality and timeliness of initial care, and the technique of treatment.

Trauma followed with fracture of anterior teeth, especially permanent incisor, is considered not only as a tragic experience for young people, but also as the loss of anterior teeth that have a strong psychological impact on children and parents. If trauma involves both extensive loss of tooth structure and pain and discomfort sensation, it will change the appearance of the child and become the subject of bully by his or her peers. However, with recent advances in the field of esthetic in dentistry, restoration treatment is considered as the best solution to meet the high expectations of patients to be able to smile confidently.^{9,10}

A violent blow from frontal and horizontal direction can cause fracture line from several points on the crown, and then can longitudinally extend, with or without the involvement of the pulp, to mesial or distal subgingival area. Fractures of teeth can be classified into six classes: class 1: enamel fracture; class 2: dentin fracture without opening the pulp; class 3: crown fracture with opening the pulp; class 4: root fracture; class 5: subluxation teeth; and grade 6: intrusion teeth. Meanwhile, crown fracture can be classified into fracture class 3.⁴

Crown fracture with pulp exposed due to trauma can be treated with four kinds of treatment: pulpotomy, apexification, pulpectomy and root resection.¹¹ The appropriate treatment for the pulp and its required restoration, nevertheless, is determined with the extent of the fracture. Extensive fracture also requires root canal treatment using post and core that support the crown, but it still depends on the age of patients. In dentistry, especially in aesthetic dental conservation, fracture is a kind of tooth decay requiring an aesthetic care. A tooth suffering from complicated crown fracture with open pulp can be treated with endorestitution treatment including endodontic treatment using post-core retention and porcelain fused to metal crown.^{1,5,12} This case report is aimed to report the esthetic improvement of the anterior teeth the anterior teeth suffering from complicated crown fracture with open pulp due to trauma by conducting endorestitution treatment in order to improve its forms, functions, and aesthetics as normal as the original ones with stomatognathic system. A case of trauma to the maxillary incisors suffering from complicated crown fracture and treated with endorestitution treatment, including endodontic treatment, followed by insertion of casting post-core and of porcelain fused to metal crown will be reported.

CASE

A 17 years old male came to Universitas Airlangga dental hospital. He had motorcycle accident four days ago. The crown of his anterior teeth #11, #21 and #22 fractured around the cervical areas. Torn ragged wound and swelling

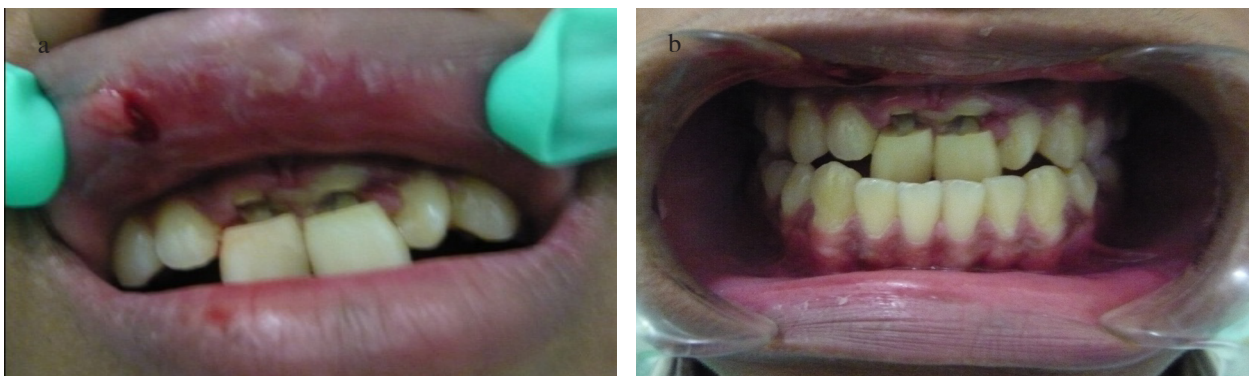


Figure 1. a) The condition of upper lip with torn ragged wound; b) The initial condition of complicated crown fracture on teeth #11, #21 and #22.

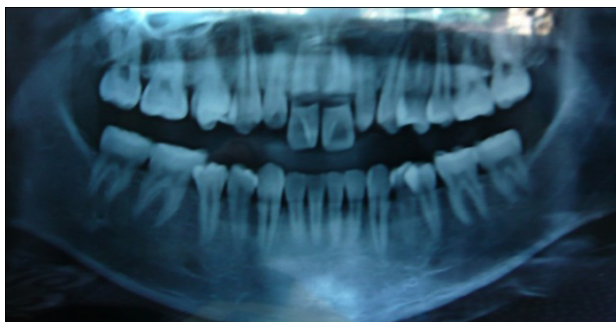

Figure 2. Panoramic x-ray image.

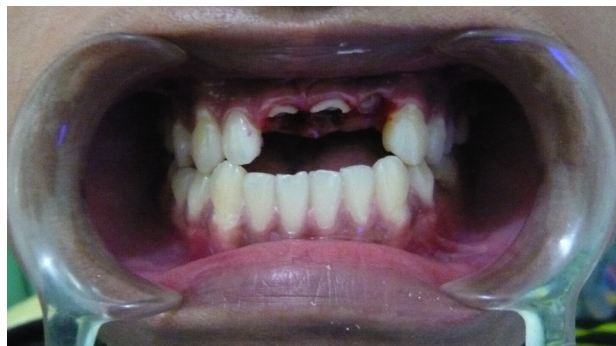

Figure 3. The Condition of teeth after the releasing the crowns of #11, #21, #22 prior to the treatment.

was found around the vestibule areas of the teeth #11, #21, #22 and the upper lip (Figure 1a). The patient wanted to have his anterior teeth aesthetically improved to normalized its form and function.

Intra oral examination was conducted on the teeth #11, #21 and #22 suffering from complicated crown fracture causing an fully opened pulp around tooth cervical areas (Figure 1b). Panoramic and local x-rays were conducted (Figure 2). Based on the results, there was radiolucency appeared on the periodontal ligament of the teeth #11, #21 and #22. The teeth #11, #21 and #22 were then diagnosed as pulpitis irreversible.

CASE MANAGEMENT

At the first visit, to dental hospital emergency treatment that consisted of soft tissue cleansing around the mouth and lips with saline and hydrogen peroxide and giving antibiotics, analgesics, and anti-inflammatory were conducted. The patient was also suggested to maintain his oral hygiene by using chlorhexidine mouthwash and having soft food diet. The emergency care should immediately be taken to prevent the patient from soft tissue.²

The crowns of fractured teeth #11, #21 and #22 were extracted until the cervical areas and gingivectomy was done in the palatal rugae frenulum areas to improve the shape of excessive gingival contour lines that corresponded to palatal and labial cervical portion of the anterior teeth (Figure 3). After wound healed, an impression were taken on maxillary and mandibula for model study. Dental records

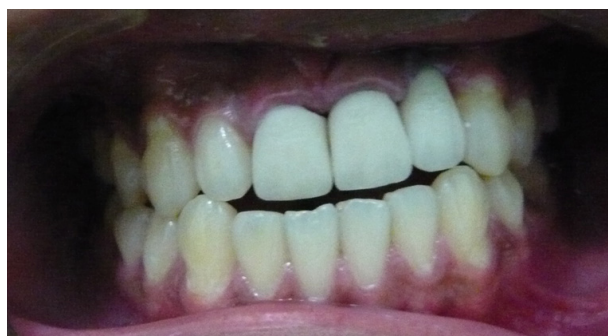

Figure 4. Temporary tooth crown on teeth #11, #21 and #22.

were then also conducted in order to record occlusion and relationship, and to be used as temporary jacket crowns on teeth #11, #21 and #22 to prevent bad appearance during the dental treatment.

Moreover, pulpectomy treatment was conducted for one visit on the teeth #11, #21 and #22 with crown down pressureless technique by using file Pro Taper preparation tools and single cone filling technique by using ultracal pasta sealer material. In the next stage, the preparation of post channel was conducted by taking gutapercha using gates gliden drill, and then followed with conducting peeso reamer leaving the gutta-percha about 4-5 mm from the apex of the root canal. Afterwards, the root canal was printed by using elastomer print materials to make post and core. The temporary crown was then inserted for maintaining the aesthetics of the teeth during manufacturing process of casting post and core in dental laborioium (Figure 4).

Few days later cast posts and cores were inserted into the root canal of teeth #11, #21 and #22 by using glass ionomer cement type I luting cement (Figure 5a). Local x-ray were conducted (Figure 5b). Impression was done on teeth #11, #21 and #22 by double impression technique. In the next stage, temporary crown was inserted and the print result was sent to the dental lab for making porcelain fused to metal crowns. Then, the porcelain fused to metal crowns were inserted on the teeth #11, #21 and #22 by using glass ionomer cement type I luting cement (Figure 6). Evaluation was followed 3 and 6 months after treatment in which the patient got a good result (Figure 7).

DISCUSSION

Various conditions of trauma can generally cause crown fractures although many literatures suggest several predominant causes, such as falling either while playing and running or during sports activities, as well as having car accidents and a blow on the face. Anterior teeth are actually more susceptible to trauma, approximately 80% it the central maxillary incisors followed by lateral maxillary incisors and central mandibular incisors.¹

Generally dental trauma can involve pulp both directly and indirectly, so endodontics is considered to play an important role in the evaluation and treatment of dental

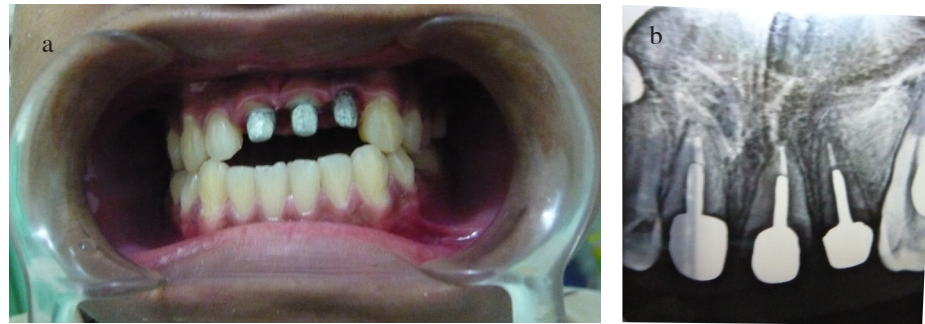

Figure 5. a) The inserted of casting post and core on teeth #11, #21 and #22; b) Casting post and core insertion in the root canal.

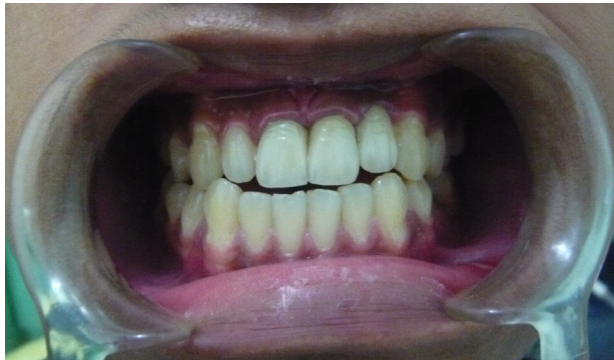

Figure 6. The insertion of porcelain fused to metal crown on teeth #11, #21 and #22.

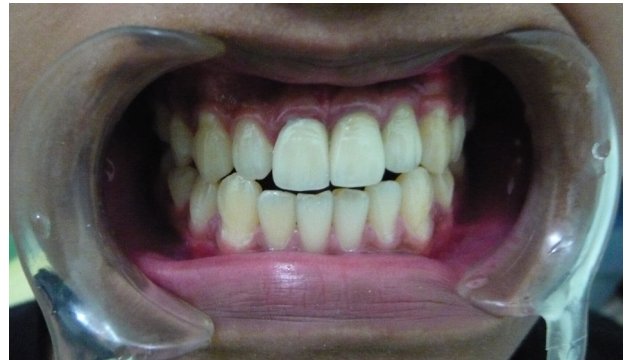

Figure 7. Control after 3 month.

injuries. Fractures that involving the edge of gingiva area need an endodontic treatment followed with crown restorations using post and core but it depend on the age of patient.⁵

In this case, teeth #11, #21 and #22 suffering from complicated crown fracture were treated by endorestoration treatment, which was pulpectomy care followed by the installation of retention, such as casting post and core, and finished with the insertion of porcelain fused to metal crown. If patient with an open pulp tooth fracture case came to be treated after 72 hours or more, the treatment option is endodontic treatment by removing all affected pulp tissue; but if more than half the coronal missing, it is necessary for post and core to be inserted restored with core crown. The post and core restorations are used to reshape the structure of the lost crown.^{9,12} Restoration of a fractured tooth after endodontic treatment depends on the structure lost of tooth crown. If the fracture is only on the enamel and dentin, it can be restored with a simple composite or porcelain veneers, but, if it is more than half of the crown missing, the tooth will require post and core crowns.⁹

The dental care after endodontic treatment is restore the remaining root and crown of tooth by using retentive and stable post crown, so it will not easily broken and can be used as long as possible in the oral cavity to replace the original tooth. Characteristic of tooth is relatively more brittle and prone to fracture than vital one due to tooth internal moisture decrease and it weaken after endodontic treatment are weaken the remaining tooth structure and non-vital tooth often get color shifts.^{8,21}

Therefore, one visit endodontic treatment was conducted on teeth #11, #21 and #22 because the shape of the root canals was normal and single-rooted with the diagnosis of pulpitis irreversible with periodontal ligament abnormalities without clinical symptoms. Thus, this one visit endodontic treatment aimed not only to prevent the spread of the disease from pulp into periapical tissues, but also to restore the periapical tissues. It also gives the advantage to reduce the risk of infection between visits.⁴

Preparation of the root canal #11, #21 and #22 was then conducted by using crown down pressureless technique with a ProTaper tool through the coronal-apical approach. This technique is very beneficial because 1/3 of microorganisms are located in coronal, another 1/3 that has drawn first before going into the apical area is located in center, and the other 1/3 that had more perfect irrigation are located in apical.¹³

Afterwards, intracanal retention was conducted to restore the crown by using post as retention on its restoration. Post used in this case was casting post (artificial post) and core also used was aimed to increase the retention of teeth and position of porcelain fused to metal crown restoration. Position of teeth with crowns that have been depleted or with heavy occlusal forces can be indicated by the crown with the casting post and core. Teeth both with short clinical crowns or without clinical crowns, but still having adequate roots in terms of length, thickness and embedded in the alveolar bone, and with the ratio between the root and the crown of the teeth can qualify for post length inserted into the root canal length at least equal to the crown length, thus, casting post and core are the best choices.^{15,16}

Moreover, the selection of the post and core designs as the retention in the root canal is depend on to the rest of the crown, the occlusal pressure force (chewing power), the diameter of the root canal, the location of the teeth, and the health of the periodontal tissue as post crown supporter.⁸ In determining the type of post crown, it can not be separated from efforts to design the post. The procedure of selection of design and preparation of root canal should be done in such a choice that does not further debilitating the remaining tooth tissues and cause a risk of post disposition.¹⁷

Furthermore, the teeth #11, #21 and #22 used post and core since it generally had several advantages such as: post and core become one unit, and could accurately adapt the shape of root canal preparation, as a result, it become retentive and stable, it does not require additional retention form pin, and could easily adjust to the irregular shape of root canal that result strong and effective post and core. The setting of post and core on the teeth #11, #21, and #22 was prepared one by one at the same time, to get the shape and size similar to the normal size of each tooth and anterior dental arch with normal overbite and overjet to achieve a good and harmonious aesthetics.¹⁵

The principle of dental care that has already obtained endodontic treatment is actually to restore tooth root and crown by using retentive and stable post and core crowns, so they are not easily malpositioned and can be used as long as possible in the oral cavity like the original tooth. Moreover, it should be noted that tooth having endodontic treatment is relatively more brittle and fragile (easily fracture) than healthy tooth due to organic and biological changes caused pulp necrose, the reduction of the tooth internal tissue, as well as the lack of the linkage between the tooth enamel and dentin due to the grinding of dentin tissue during preparation of root canal, that can caused discoloration. Therefore, comprehensive protection is necessary by strengthening post and core as well as porcelain fused to metal crown restoration in order to prevent the tooth from fracture.^{8,15}

Porcelain fused to metal crown restoration is the best option to restore tooth aesthetics, especially the shape and color of the tooth anatomy in accordance with natural teeth, and to be able to function naturally. Similarly, Hume¹⁸ also said that the porcelain jacket crown is the best choice to restore the aesthetics of the central incisors optimally. Furthermore, among 956 patients, only 63% of them were satisfied with the appearance of the anterior tooth using a crown veil, and 79% of them were satisfied with 4 or more anterior teeth using porcelain fused to metal crowns.¹⁹ Porcelain is also considered to be the most satisfying treatment because of its natural color and aesthetics. The cementation of the porcelain fused to metal crown towards post-core uses glass ionomer cement type I (luting sement).²⁰

The success of a restoration, however, is determined by retention, stability, aesthetics (especially anterior teeth) as well as biological aspects. Cooperation and understanding between patient and dentist is also the basis of success. Improvement on aesthetic appearance becomes increasingly

important in today's modern dental practice.²¹ This case showed that that tooth with complicated crown fracture due to trauma can be treated with endorestitution care not only to maintain the tooth as long as possible in the oral cavity, but also to restore the form, function and aesthetic of the tooth in accordance with stomatognathic system.

REFERENCES

- Mutan HA, Erdal O, Yahya OZ, Muzaffer A. Treatment of traumatized maxillary permanent lateral and central horizontal root fractures. *A Case Report. Indian J Dent Res* 2008; 19(4): 354–6.
- Aggarwal V, Logami A, Shah N. Complicated crown fractures-management and treatment option. *Int Endod J* 2009; 42(8): 740–53.
- Biner S, Dang L, Gomes J, Mc Murran T, Schneiders. What's is the best treatment of horizontal root fracture teeth. *An Evidence Based Report. Toronto: Faculty of Dentistry Toronto On Canada; 2010.* p. 1–23.
- Grossman LI, Oliet S, del Rio CE. 1988 Ilmu endodontik dalam praktek. 1st ed. Jakarta: Penerbit buku Kedokteran ECG; 1995. p. 196–380.
- Torabinejad M, Walton RE. Endodontics principles and practice. 4th ed. St Louis: Missouri; 2009. p. 165–7.
- Parirokh M, Kakoel S, Aeskandizadeh A. Maturogenesis of complicated crown fracture: Case report with 8 years follow up. *Iranian Endod J* 2007; 2: 32–6.
- Altinok B, Kargul B. Case Report. Use of mineral trioxide aggregate in permanen incisor with horizontal root fractures: A Five Year Follow up. 2010, December (IX), 4: 2–6.
- Chan DCN, Myers ML, Chipped. Fracture, or endodontically treated teeth. In: Goldstein RE, editor. *Esthetics in dentistry.* 2nd ed. Hamilton, London: BC Decker Inc; 2002. p. 537–9.
- Jain V, Gupta R, Duggal R, Parkash H. Restoration of traumatized anterior teeth by interdisciplinary approach: Report of three cases. *J Indian Soc Pedod Prev Dent-December* 2000; 20(1): 193–6.
- Heda CB, Heda AA, Kulkarni SS. A multi-disciplinary approach in the management of traumatized tooth with complicated crown-root fracture: A case report. *J Indian Soc Pedod Prev Dent* 2006; 24(4): 197–200.
- Schulze A. Dental traumatic injuries in sport accident. *Clinic Sports Medicine International (CSMI)* 2008; 1(8): 13–5.
- Catagay B, Osman TH, Mehmet Y. Restoration of crown fracture with a fiber post, polyethylene and composit resin. *Rev Clin Pesq Odontol Curitiba* 2009; 5(1):73–7.
- Nesha G, Amit G. *Textbook of endodontic.* 1st ed. Jaype Brothers Medical Publishers; 2007. p. 196.
- Shillingburg HT, Kessler W. Restoration of endodontically treated tooth. Chicago, Quintessence Publishing Co. Inc; 1982. p. 17–8.
- Tohiroh DJ, Rahardo TBW. Retensi mahkota pasak berdasarkan desain pasak. *Kumpulan Naskah Temu Ilmiah Nasional I (TIMNAS I) Peringatan 70 tahun Pendidikan Dokter Gigi Indonesia, 1998;* p. 145–6.
- Kamizar. Etiologi dan pencegahan kasus-kasus iatrogenic dalam restorasi pasca endodontic. *JKGUI* 2000; (Edisi khusus): 470–4.
- Ziebert GJ. Restoration of endodontically treated teeth. In: Malone WFP, Koth DL, Kaiser DA, Morgano SM, eds. *Tylman's theory and practice of fixed prosthodontic.* 8th ed. St Louis, Tokyo: Ishiyaku Euro America Inc; 2009. p. 407–17.
- Hume WR. Preservation and restoration of tooth structure. London: The CV Mosby Co; 1998. p. 185–90.
- Qualthrough AJE, Burke FJT. A look at dental esthetics. *J Quintessence International* 1994; 25(1): 7–9.
- Yuzugullu B, Canay S. Metal-ceramic dowel crown restoration for severely damaged teeth: A clinical report. *Indiana J Dent Res* 2009; 20(1): 110–2.
- Zubaidah N. The management of horizontal crown fracture caused by traumatic injury with endorestitution treatment. *Dent J (Majalah Kedokteran Gigi)* 2011; 44(3): 154–8.