

The diagnostic challenges and two-step surgical approach to an infected dentigerous cyst resembling a unicystic ameloblastoma: A case report

Cokorda Gde Suryabharata¹, Andra Rizqiawan^{2,3}, Indra Mulyawan^{2,3}, Sisca Meida Wati⁴, Mohammad Zeshaan Rahman⁵

¹Resident of Oral and Maxillofacial Surgery, Faculty of Dental Medicine, Universitas Airlangga, Surabaya, Indonesia

²Staff of Oral and Maxillofacial Surgery, Universitas Airlangga Academic Dental Hospital, Surabaya, Indonesia

³Department of Oral and Maxillofacial Surgery, Faculty of Dental Medicine, Universitas Airlangga, Surabaya, Indonesia

⁴Department of Oral and Maxillofacial Pathology, Faculty of Dental Medicine, Universitas Airlangga, Surabaya, Indonesia

⁵Department of Oral and Maxillofacial Surgery, Pioneer Dental College and Hospital, Dhaka, Bangladesh

ABSTRACT

Background: A dentigerous cyst is the second-most frequently observed odontogenic cyst, and an ameloblastoma is one of the most frequently observed odontogenic tumors. Both are mostly associated with an impacted mandibular third molar and have similar characteristics. Diagnostic difficulties often result in misdiagnosis and remain a challenge to overcome. Comprehensive clinical, radiographic, and histopathological views are essential to correctly diagnose the problem and formulate the most suitable treatment plan. **Purpose:** This case report aims to present a thorough approach to the diagnostic and surgical procedures involved in treating a dentigerous cyst that resembles an ameloblastoma by using marsupialization followed by enucleation. **Case:** This article presents the case report of a 27-year-old male patient with an infected dentigerous cyst resembling a unicystic ameloblastoma associated with a totally impacted lower mandibular left third molar. The patient had a history of swelling, pain, and pus drainage in the retromolar area. Symptoms subsided after antibiotic and analgesic prescriptions, but the lesion remained and was slowly progressing. The diagnostic approach began with a fine-needle aspiration biopsy, and the result confirmed a benign cystic lesion that was suspected to be an odontogenic tumor. Then an incisional biopsy was conducted under local anesthesia, diagnosing an infected dentigerous cyst. **Case Management:** Marsupialization and decompression using an obturator was preferred, followed by enucleation. Nine months later, a radiographic examination revealed satisfactory bone regeneration without recurrence. **Conclusion:** An incisional biopsy plays a vital role in establishing a definitive diagnosis. Marsupialization followed by enucleation offers an excellent combination of treatments achieving complete cyst removal, anatomical structure preservation, and bone regeneration with minimal complications.

Keywords: dentigerous cyst; marsupialization; enucleation; obturator; medicine

Article history: Received 10 January 2023; Revised 3 February 2023; Accepted 1 March 2023; Published 1 September 2023

Correspondence: Andra Rizqiawan, Department of Oral and Maxillofacial Surgery, Faculty of Dental Medicine, Universitas Airlangga, Jl. Mayjen Prof. Dr. Moestopo 47 Surabaya, 60132 Indonesia. Email: andra-r@fkg.unair.ac.id

INTRODUCTION

The remaining odontogenic epithelium involved in the process of odontogenesis associated with impacted teeth has the potential to transform into various odontogenic cysts and tumors.¹ According to classification by the World Health Organization (2017), a dentigerous cyst is a developmental cyst that surrounds and envelops the crown of an unerupted tooth and is attached at cervical areas or the cemento-enamel junction of the tooth.^{2,3} Clinically

and radiographically, there are similarities between a dentigerous cyst and a unicystic ameloblastoma.⁴ In a number of cases it was found that an ameloblastoma was associated with dentigerous cysts and was common in patients younger than 30 years old.⁵

Early diagnosis of jaw lesions such as odontogenic cysts and tumors is very important in order to determine the appropriate treatment plan and prevent misdiagnosis and overtreatment that can cause morbidity. A fine-needle aspiration biopsy (FNAB) is a diagnostic modality that is

frequently used, but it has several drawbacks so it must be supported by other examinations such as an incisional biopsy or excision. A biopsy provides a high degree of accuracy because it can detect the morphology of the cells required for the correct diagnosis.^{6–8} Surgical management and treatment of a dentigerous cyst consist of enucleation and extraction of the affected tooth.⁹ Marsupialization and decompression release the pressure on the cyst and allow the bone cavity to progressively decrease in volume with the gradual apposition of bone.^{10,11} An obturator is used after marsupialization for decompression and to keep the cyst lumen open. Its smooth surface can prevent the formed blood clot from lifting and avoid the formation of scar tissue. In marsupialization treatment, the cyst is left open and connected to the oral mucosa.^{12–15}

The aim of this case report is to present and discuss a comprehensive management plan in terms of establishing a definitive diagnosis due to the clinical and radiological similarities between a dentigerous cyst and a unicystic ameloblastoma. In this case, a FNAB and an incisional biopsy were performed to confirm the diagnosis. The operative treatments performed were an odontectomy of the affected bony impacted third molar, marsupialization and decompression using an obturator, and enucleation followed by curettage.

CASE

A 27-year-old male patient visited the oral and maxillofacial surgery clinic at the Universitas Airlangga Teaching Hospital chiefly complaining of a painful swelling on the left cheek that had been gradually increasing over the past year. The swelling had reduced in size due to an intraoral fluid discharge a week before the patient visited the hospital. There was no numbness in the lower left jaw, no significant weight loss in the past three months, no history of accidents or blows to the lower left jaw, and no lumps

in other areas of the body. No history of systemic disease or allergies was confirmed.

A physical examination revealed the patient was in good general condition. The results of an extraoral examination by inspection did not uncover facial asymmetry, oedema, hyperemia, or ulcers and fistulas in the buccal sinistra region. On extraoral palpation, the lump was evident on the buccal sinistra corpus region of the mandible around teeth 36 and 37. It was well-defined and was of a firm and solid consistency, and its temperature was equal to that of the surrounding tissue. There was minimal tenderness, no palpable paresthesia, and an intact inferior border of the sinistra mandible. There was no palpable enlargement nor pain in the regional lymph nodes of the head and neck.

An intraoral examination revealed a lump with oedema on the buccal area from the retromolar pad to the region of teeth 36 and 37. The vestibulum was shallower and diffused. It was the same color as the surrounding tissue, and there was no expansion to the lingual, no ulcer, and visible pus drainage on the distal of tooth 37 when palpated. There was a palpable lump on the retromolar pad 38 to 36 in region 37, a cystic consistency originating from retromolar pad 38 to region 37, a hard solid consistency on region 36, no palpable fluctuation, a temperature equal to the surrounding tissue, and an intact lingual and buccal plate. There was no mobility of the surrounding tooth, and the vitality test on 36 and 37 was positive. Several follow-up examinations were performed, including a hematological examination, panoramic radiography (Figure 1), and anatomic pathology. The hematological examination was normal. Radiography revealed a well-defined radiolucent lesion resembling a cyst in the region of 37 and 38 as well as an impacted third molar in both side of mandibula.

An anatomic pathology examination was conducted using the FNAB method first, revealing a benign cystic lesion with suspicions of an ameloblastoma. Then an incisional biopsy was performed under local anesthesia to confirm a definitive diagnosis (Figure 2).

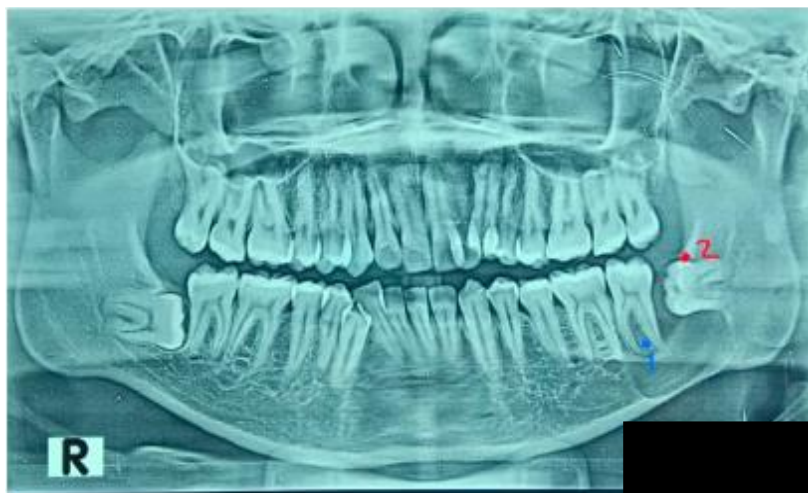

Figure 1. Pre-operative radiograph, location of lesion, and specimen collection point. Blue dot is an ameloblastoma. Red dot is the impacted third molar (#36).

Intraoral and extraoral asepsis was performed using a sterile drape before the surgical procedure. The patient was anesthetized using the local anesthetics lidocaine and adrenaline at the ratio 1:80,000. The incision was made according to the planned diagram on the retromolar pad area to the distal of 37, extended along the gingival margin of 37, and followed by a vertical oblique incision on the mesial of 37 to the anterior. The surgeon retracted the mucoperiosteal flap until the cyst wall was lined with epithelium and no solid mass was visible in the area. The cyst was punctured, and a cloudy red-black-brown fluid

was obtained. The defect on the left mandible revealed the presence of a cavity with no septum. The walls of the buccal cortex, the lingual, and the inferior border of the mandible were intact. Specimens were collected and then subjected to an anatomic pathology examination that demonstrated that the tissue section included cyst walls that were partially lined with squamous epithelium. The stroma revealed a dense infiltration of inflammatory cells including lymphocytes, histiocytes, and plasma cells, and no signs of malignancy were observed, confirming an infected dentigerous cyst.

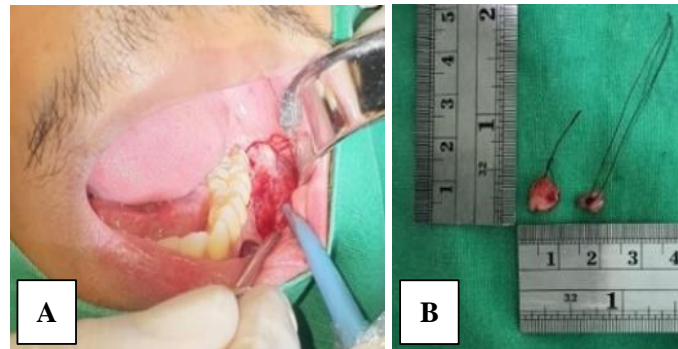


Figure 2. Incisional biopsy (A). Specimen (B).

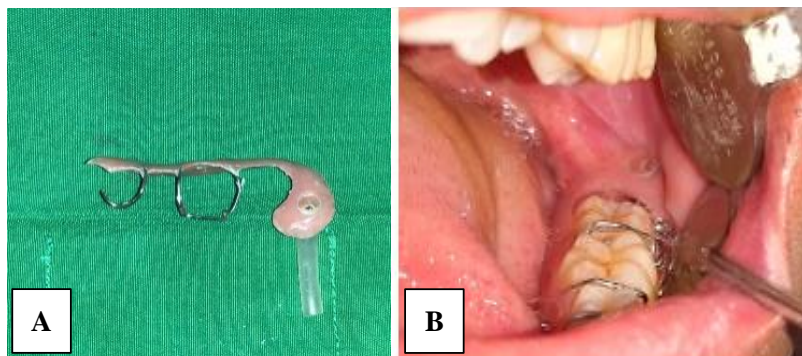


Figure 3. Obturator (A). Obturator insertion (B), in the region of the left mandible.

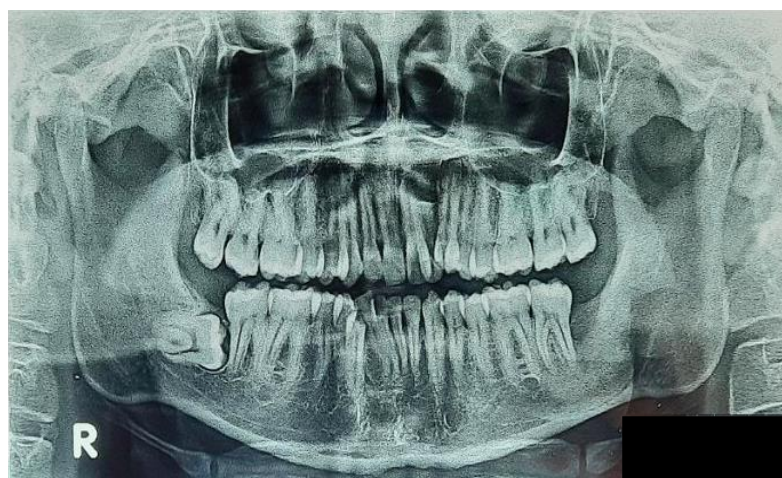

Figure 4. Post-operative panoramic radiograph, in the region of the left mandible.

CASE MANAGEMENT

Based on the histopathological result, the treatment plan for this case featured marsupialization, decompression using an obturator, and an odontectomy of the affected impacted left mandibular third molar under local anesthesia. The mucoperiosteal flap was lifted using the same procedure as the earlier incisional biopsy. Exploration of the third molar was conducted that confirmed it was mobile and involved in the cyst. A further split technique without bone reduction was performed to atraumatically extract the third molar and preserve the adjacent anatomical structure. Marsupialization was conducted using silk 3.0 surgical suture to suture the cyst epithelium to the oral mucosa to adequately drain the cystic fluid and convert the cystic mucosa into normal oral mucosa. Kalmicetine gauze was inserted in the cystic lumen to prevent dead space and infection.

An inspection was performed on the third day post-operative to remove the kalmicetine gauze and create an impression for the obturator. The marsupialization window was still maintained, and measurements of the canal were taken to manufacture the obturator. An impression was generated using hydrocolloid impression material with a silicone tube inserted in the lumen. Subsequently, a decompression obturator was created with acrylic, featuring clasps for retention and a silicone tube to adequately drain the cystic fluid and facilitate irrigation. The patient returned for an examination on the seventh post-operative day. Irrigation was performed through the marsupialization canal using 0.9% NaCl with a 10cc syringe and fill the syringe with 20cc of the fluid until the cavity appeared clean. Irrigation then continued using 1% or 3% hydrogen peroxide dissolved in 0.9% NaCl at a ratio of 3:1. Irrigation was conducted through the marsupialization canal with a 10cc syringe and as much as 10cc of fluid, and the foam was left for ten seconds before the patient was instructed to spit. The final stage of irrigation used 0.1% or 0.2% chlorhexidine digluconate dissolved in 0.9% NaCl at a ratio of 1:1. Irrigation was performed through the marsupialization canal using a 10cc syringe and as much as 20cc of fluid until it was clean, and then the patient was instructed to spit. After the marsupialization window was clear, the insertion of the obturator could be attempted.

After the insertion of the obturator, the patient returned for examinations after one week, one month, three months, and ten months (Figure 3). In the third month and the ten months, a panoramic radiograph was taken to evaluate the post-operative condition and readiness for the second surgery (Figure 4). At every examination, the cystic lumen was irrigated using the same irrigation protocol explained above.

In the tenth month, enucleation and curettage were performed to retrieve the remaining cyst, and then an evaluation was performed at eight days post-operative. The results revealed that there was adequate bone formation without any sign of recurrence.

DISCUSSION

Establishing a definitive diagnosis and formulating the most appropriate treatment plan to manage odontogenic cysts remains a challenge for oral and maxillofacial surgeons.¹⁶ In this case, many similarities between a dentigerous cyst and a unicystic ameloblastoma were found that, if not correctly diagnosed and managed, could lead to a clinical misdiagnosis resulting in the patient's morbidity.^{17–19}

Numerous diagnostic modalities, such as oral radiography and anatomic pathology, exist. Radiographic images such as panoramic radiographs could highlight the anatomical position of the pathologic lesion, but they also present disadvantages because many lesions have a similar radiographic appearance.²⁰ A biopsy is the gold standard for obtaining a microscopic image through a histopathologic examination, as conducted in this case. To determine the diagnosis, a triple analysis should be performed based on clinical signs, radiographic images, and histopathology.²¹ Before conducting a histopathologic examination with an incisional biopsy, a procedure called FNAB must be performed to ensure there is no malignancy in the lesion. After ensuring the absence of malignancy, an incisional biopsy can then be conducted if the FNAB result is inconclusive and requires a more definitive result.²²

The most frequently occurring jaw lesions that require a biopsy for an anatomic pathology examination are dentigerous cysts, odontogenic keratocysts, and unicystic ameloblastomas. These lesions display similarities in radiographic images, which can be a well-defined unilocular radiolucent lesion with a sclerotic border or a multilocular radiolucent with a scalloped border and involving an impacted tooth.^{14,16,17} The management of these three kinds of conditions necessitates different approaches, so a proper diagnosis is required to determine an adequate treatment plan. When the result reveals an ameloblastoma, resection is the treatment choice. However, when the histopathologic examination uncovers a cyst, the treatment plan involves enucleation or marsupialization.^{23,24}

This case report highlighted an extensive dentigerous cyst related to an impacted left mandibular third molar. The patient presented with a pus-filled lump that could be diagnosed as a neoplasm, cyst, or infection. A dentigerous cyst is an odontogenic cyst that is generally associated with an unerupted or impacted tooth. This cyst forms around the crown of the unerupted tooth. It begins when there is an accumulation of fluid in the rest of the enamel epithelium and extends around the crown of the unerupted tooth.^{25–27} A dentigerous cyst can be treated by enucleation, marsupialization, or both of these surgical treatments in two steps. A decision about the management of a dentigerous cyst depends on several considerations, such as the size and location of the cyst, the removal of an unerupted tooth, and the possibility for follow-up with the patient.¹⁹ Enucleation and extraction of the tooth directly risk weakening the jaw and causing a pathological fracture.²⁸

Marsupialization and decompression were performed in this case to adequately decompress the cyst and prevent injury to adjacent vital anatomical structures. This surgical step is a decompression stage to decrease intracystic and internal hydrostatic pressure.^{29,30} Decompression eliminates tension in the surrounding bone surface that inhibits proliferation and differentiation of the osteogenic precursor, so this procedure induces a signaling pathway that promotes osteogenesis.³¹ The goals of marsupialization are to decrease the size of the lesion, promote bone growth, and convert cystic epithelium to normal oral epithelium.³² There are several disadvantages of marsupialization, including the duration of treatment, dependency on the patient's cooperation, discomfort, and the risk of recurrence and transformation into neoplasia and malignancy.³³ Irrigation is a mandatory protocol during marsupialization to eliminate the pathologic tissues. In this case, the irrigation protocol was performed two to three times per day with chlorhexidine 0.12%. Using a syringe, 5ml of chlorhexidine was inserted, and the liquid was left behind to recede after irrigating the cavity. Irrigation was conducted for at least six months to support the bone-healing process.^{30,31} Chlorhexidine is a broad-spectrum antimicrobial agent. Concentrations of chlorhexidine that are greater than 0.1% can cause leakage of intracellular components out of the cell and undertake a bactericidal effect that prevents bacterial contamination that could hinder bone regeneration.³²

In this case, the use of two-step surgery was based on research by Marin et al.²⁶ that demonstrated that enucleation after marsupialization is necessary in 54.4% of cases, especially in the posterior region. In this case, the odontectomy of the mandibular third molar was also performed to eliminate the possible main cause of the cyst.²⁷ Another case reported by Irimia et al.³⁴ revealed that six months after marsupialization, a stable decompression was achieved and enucleation was performed at that time. Panoramic radiography is one of the parameters for assessing the improvement in the lesion after the first surgery. The area and ratio of lesion regression can be measured through a panoramic radiograph. In this case, an assessment of the bone regeneration and the size of the cyst was performed by comparing the preoperative panoramic radiograph and those taken three months and nine months after marsupialization. In the tenth month, after regression and bone regeneration had been achieved, the second stage of surgery could be performed. In conclusion, an incisional biopsy plays a vital role in establishing a definitive diagnosis. Marsupialization using an obturator followed by enucleation offer an excellent combination of treatments to achieve complete cyst removal, anatomical structure preservation, and bone regeneration with minimal complications. Routine long-term follow-up is required to monitor recurrence.

REFERENCES

- Caruso D, Lee C, Peacock ZS. What factors differentiate dentigerous cysts from other pathologic entities in pericoronal radiolucent lesions? *J Oral Maxillofac Surg.* 2021; 79(10): e57–8.
- Suluk-tekketin M, Wright JM. The world health organization classification of odontogenic lesions: a summary of the changes of the 2017 (4th) edition. *Turkish J Pathol.* 2018; 34(1).
- Thompson LDR. Dentigerous cyst. *Ear, Nose Throat J.* 2018; 97(3): 57.
- Rajendra Santosh AB. Odontogenic cysts. *Dent Clin North Am.* 2020; 64(1): 105–19.
- Abu-Mostafa N, Abbasi A. Marsupialization of a large dentigerous cyst in the mandible with orthodontic extrusion of three impacted teeth. A case report. *J Clin Exp Dent.* 2017; 9(9): e1162–6.
- Mortazavi H, Baharvand M. Jaw lesions associated with impacted tooth: A radiographic diagnostic guide. *Imaging Sci Dent.* 2016; 46(3): 147–57.
- Martin LHC, Speight PM. Odontogenic cysts: an update. *Diagnostic Histopathol.* 2017; 23(6): 260–5.
- Rioux-Forker D, Deziel AC, Williams LS, Muzaffar AR. Odontogenic cysts and tumors. *Ann Plast Surg.* 2019; 82(4): 469–77.
- Hallikeri K, Babu B, Sudhakaran A, Monteiro R. Cell block and its impact in the diagnosis of jaw lesions over fine needle aspiration cytology. *Acta Cytol.* 2021; 65(5): 361–7.
- Riachi F, Khairallah CM, Ghosn N, Berberi AN. Cyst volume changes measured with a 3D reconstruction after decompression of a mandibular dentigerous cyst with an impacted third molar. *Clin Pract.* 2019; 9(1): 1132.
- Patil M, Patil RU, Panse AM, Patil AS, Jathar PN, Bahutule SR. Infected dentigerous cyst and its conservative management: A report of two cases. *Int J Clin Pediatr Dent.* 2019; 12(1): 68–72.
- Salama AA, Abou-ElFetouh A. Marsupialization and functional obturator placement for treatment of dentigerous cyst in child: A successful blend. *Oral Maxillofac Surg Cases.* 2020; 6(4): 100200.
- Chouchene F, Ameur W Ben, Hamdi H, Bouenba M, Masmoudi F, Baaziz A, Maatouk F, Ghedira H. Conservative approach of a dentigerous cyst. *Radnai M, editor. Case Rep Dent.* 2021; 2021: 5514923.
- Robinson RA. Diagnosing the most common odontogenic cystic and osseous lesions of the jaws for the practicing pathologist. *Mod Pathol.* 2017; 30: S96–103.
- Kamadajaja DB, Satriyo H, Setyawan A, Lesmaya YD, Safirli JW, Sumarta NPM, Rizqiawan A, Danudiningrat CP, Tran TT. Analyses of bone regeneration capacity of freeze-dried bovine bone and combined deproteinized–deminerallized bovine bone particles in mandibular defects: The potential application of biological forms of bovine-bone filler. *Eur J Dent.* 2022; 16(02): 403–13.
- Emamverdzadeh P, Arta SA, Ghanizadeh M, Negahdari R, Ghavimi MA, Ghoreishizadeh A, Tojih MR. Compatibility of clinical and histopathological diagnosis of oral lesions in Iranian patients. *Pesqui Bras Odontopediatria Clin Integr.* 2019; 19(1): 1–7.
- Siregar M, Sitam S, Lita YA, Hadikrishna I. Analysis of dentigerous cyst, ameloblastoma, and odontogenic keratocyst panoramic radiograph and CBCT: a scoping review. *ODONTO Dent J.* 2022; 9: 115–30.
- Wulandari P, Widkaja D, Nasution AH, Syahputra A, Gabrina G. Association between age, gender and education level with the severity of periodontitis in pre-elderly and elderly patients. *Dent J.* 2022; 55(1): 16–20.
- Vyas T. Biopsy of oral lesion -a review article. *J Adv Med Dent Sci Res.* 2018; 6(1): 27–35.
- Nugraha AP, Kamadajaja DB, Sumarta NPM, Rizqiawan A, Pramono C, Yuliati A, Hendrianto E, Rahman MZ. Osteoinductive and osteogenic capacity of freeze-dried bovine bone compared to deproteinized bovine bone mineral scaffold in human umbilical cord mesenchymal stem cell culture: an in vitro study. *Eur J Dent.* 2023;
- Bose DS, Sur DJ, Khan DF, Dewangan DD, Roul DA. Diagnostic dilemma of dentigerous cyst mimicking a radicular cyst: a case report. *Saudi J Oral Dent Res.* 2021; 6(3): 112–5.

22. Rajae EG, Karima EH. Dentigerous cyst: enucleation or marsupialization? (a case report). *Pan Afr Med J.* 2021; 40: 149.
23. Soesilawati P, Rachmat EA, Arundina I, Naomi N. The possibility of polymorphonuclear leukocyte activation in dental socket healing by freeze-dried Aloe vera induction. *Dent J.* 2021; 54(3): 124–7.
24. Abu-Mostafa N. Marsupialization of dentigerous cysts followed by enucleation and extraction of deeply impacted third molars: two case reports. *Cureus.* 2022; 14(4): e23772.
25. de Moraes ATL, Soares HA, Viana Pinheiro J de J, Ribeiro Ribeiro AL. Marsupialization before enucleation as a treatment strategy for a large calcifying odontogenic cyst: Case report. *Int J Surg Case Rep.* 2020; 67: 239–44.
26. Marin S, Kirnbauer B, Rugani P, Mellacher A, Payer M, Jakse N. The effectiveness of decompression as initial treatment for jaw cysts: A 10-year retrospective study. *Med Oral Patol Oral y Cir Bucal.* 2018; 24(1): e47–52.
27. Consolo U, Bellini P, Melini GM, Ferri A, Lizio G. Analysis of marsupialization of mandibular cysts in improving the healing of related bone defects. *J Oral Maxillofac Surg.* 2020; 78(8): 1355.e1-1355.e11.
28. Kivovics M, Péntzes D, Moldvai J, Mijiritsky E, Németh O. A custom-made removable appliance for the decompression of odontogenic cysts fabricated using a digital workflow. *J Dent.* 2022; 126: 104295.
29. Fathi AL-Omar A, Elmorsy K. Treatment of a large maxillary cyst with marsupialization (case report). *Oral Heal Care.* 2017; 3(1): 1–4.
30. Oliveros-Lopez L, Fernandez-Olavarria A, Torres-Lagares D, Serrera-Figallo M, Castillo-Oyague R, Segura-Egea J, Gutierrez-Perez J. Reduction rate by decompression as a treatment of odontogenic cysts. *Med Oral Patol Oral y Cir Bucal.* 2017; 22(5): e643–50.
31. AboulHosn M, Noujeim Z, Nader N, Berberi A. Decompression and enucleation of a mandibular radicular cyst, followed by bone regeneration and implant-supported dental restoration. *Case Rep Dent.* 2019; 2019: 9584235.
32. Brookes ZLS, Bescos R, Belfield LA, Ali K, Roberts A. Current uses of chlorhexidine for management of oral disease: a narrative review. *J Dent.* 2020; 103: 103497.
33. Demir E, Günhan Ö. Treatment results of dentigerous cysts managed by marsupialisation, enucleation or enucleation with platelet rich plasma-a retrospective study. *Meandros Med Dent J.* 2021; 22(2): 116–24.
34. Irimia A, Moraru L, Ciubotaru DA, Caruntu C, Farcasiu A-T, Caruntu A. Minimally invasive two-staged surgery in the treatment of large cystic lesions of the jaw. *Healthcare.* 2021; 9(11): 1531.