

The expression of BMP4 and FGF2 in Wistar rats (*Rattus norvegicus*) post application of gourami fish (*Osphronemus goramy*) collagen

Chiquita Prahasanti¹, Niken Luthfiyya Arini², Kurnia Dwi Wulan², Onge Victoria Hendro³, I Komang Evan Wijaksana¹, Noer Ulfah¹, Banun Kusumawardani⁴, Padmini Hari⁵, Shahabe Saquib Abullais⁶

¹Department of Periodontics, Faculty of Dental Medicine, Universitas Airlangga, Surabaya, Indonesia

²Undergraduate student, Faculty of Dental Medicine, Universitas Airlangga, Surabaya, Indonesia

³Department of Periodontology, Faculty of Dentistry, Universitas Hang Tuah, Surabaya, Indonesia

⁴Department of Biomedical Sciences, Faculty of Dentistry, Universitas Jember, Jember, Indonesia

⁵Faculty of Dentistry, MAHSA University, Kuala Lumpur, Malaysia

⁶Department of Periodontics and Community Dental Sciences, College of Dentistry, King Khalid University, Abha, Saudi Arabia

ABSTRACT

Background: Periodontitis is a chronic inflammatory disease of the periodontal tissue that is characterized by alveolar bone resorption. This occurs due to an imbalance of osteoblast and osteoclast during the bone formation and resorption processes. In order to obtain complete regeneration of periodontal tissue, bone grafting is frequently used in periodontal surgical therapy. Although each material has disadvantages, safe graft materials derived from animal sources can be employed as an alternative to bone graft materials. Osteoblast, osteoclast, calcified bone matrix, type I collagen, osteonectin, and hydroxyapatite can all be found in gourami scales, a form of food waste. BMP4 has osteoinduction functions, which are important in bone metabolism. Through angiogenic activity, FGF2 also contributes to periodontal regeneration. **Purpose:** The aim of the study was to assess the expression of BMP4 and FGF2 after the treatment group had been given gourami fish scale extract. **Methods:** Thirty-two experimental three-month-old male Wistar rats (150–200g) were randomly divided into four groups: a seven-day control group, a seven-day treatment group, a 14-day control group, and a 14-day treatment group. One mandibular incisor was extracted from each Wistar rat. The post-extraction socket was filled with blood for the control group and collagen extract for the treatment. **Results:** The one-way ANOVA test showed a significance level of 0.000 ($p = <0.05$). **Conclusion:** The expression of BMP4 and FGF2 increased after the application of collagen extract from gourami scales.

Keywords: BMP4; collagen; FGF2; gourami fish scales; medicine

Article history: Received 26 July 2022; Revised 6 September 2022; Accepted 22 September 2022

Correspondence: Chiquita Prahasanti, Department of Periodontics, Faculty of Dental Medicine, Universitas Airlangga. Jl. Mayjen. Prof. Dr. Moestopo 47, Surabaya 60132, Indonesia. Email: chiquita-p-s@fkg.unair.ac.id

INTRODUCTION

Periodontitis is defined as a chronic inflammatory disease indicated by the infiltration of immune cells in the gingiva, which leads to connective tissue damage, clinical attachment loss, and resorption of the alveolar bone.^{1,2} Poor oral hygiene and lifestyle choices lead to the onset and progression of periodontitis, one of the most prevalent chronic inflammatory diseases in humans.³ Periodontitis is a risk factor for a number of diseases, such as infectious endocarditis, cardiovascular disease, fatal or nonfatal stroke, premature birth, diabetes mellitus, pulmonary disease, and sinus disease.⁴

The most common periodontal diseases are gingivitis and periodontitis; in gingivitis, inflammation is limited to the gingival area, whereas in periodontitis, there is a destruction of connective tissue and alveolar bone.⁵ When there is an increase in attachment loss caused by periodontitis, both in terms of the number of teeth and the severity, this will affect a person's quality of life. This is due to the possibility that it will enhance masticatory dysfunction by causing tooth migration, tooth extrusion, tooth hypermobility, and tooth loss.⁶

The use of collagen-based biomaterials in tissue engineering applications has increased over the last few

decades. Collagen is a versatile material that is frequently used in the fields of medicine, dentistry, and pharmacology because it has several advantages, including biocompatibility, biodegradability, adequate mechanical strength, flexibility, and the ability to absorb body fluids for nutrient transfer.⁷ Collagen has great vascularity and a superior ability to repair wounds, which makes it biocompatible.⁸ An alternative source of collagen production is fish scales. Type I collagen can be found in gourami fish scale extract (*Osphronemus goramy*). The ideal porosity size for bone regeneration is between 100 and 500 μm ; gourami scale collagen extract has pores ranging in size from 191.6 to 385.3 μm . The collagen scaffold's porosity size contributes to the availability of spaces for cells to penetrate and grow.⁹

Bone morphogenetic protein 4 (BMP4) is a member of the bone morphogenetic protein family which is part of the transforming growth factor-beta superfamily that plays an essential role in bone formation.¹⁰ In the early stages of bone formation, BMP4 acts as a stimulatory factor in cartilage ossification. BMP4 can be found in bone marrow cavities, periosteum, mesenchymal cells, cartilage cells, and muscle cells near fractured bones. BMP4 stimulates bone formation indirectly by inhibiting osteoclastogenesis, which is important in fracture repair.¹¹

In periodontitis, the addition of fibroblast growth factor 2 (FGF2) is able to promote the establishment of cementum, periodontal ligament, and alveolar bone.¹² FGF2 has been researched for its role in periodontal regeneration due to its angiogenic and mitogenic activities during the wound healing process. This protein elevates the expression of bone morphogenetic protein 2 (BMP2), which leads to an increase in bone deposits. It also stimulates fibroblast cell proliferation and increases angiogenesis.

Numerous studies have found that scaffolds derived from gourami fish scale extract have good biological properties that are safe for the viability of human gingival fibroblast,¹³ baby hamster kidney fibroblasts-21 fibroblast cell culture,⁹ and osteoblast cell culture.¹⁴ Scaffolds derived from gourami fish scale extract can enhance the expression of osteoprotegerin (OPG), receptor activator of nuclear factor kappa- β ligand (RANKL),¹⁵ alkaline phosphatase (ALP), transforming growth factor beta (TGF- β),¹⁶ BMP2, and vascular endothelial growth factor (VEGF)¹⁷ in osteoblast cell cultures, which can accelerate angiogenesis and osteogenesis. However, no study has determined the effect of type I collagen scaffold derived from gourami fish scale extract (*O. goramy*) on the expression of BMP4 and FGF2 during the bone regeneration process. This study

aims to assess the expression of BMP4 and FGF2 after the treatment group is given type I collagen scaffold derived from gourami fish scale extract (*O. goramy*) during the in vitro bone regeneration process.

MATERIALS AND METHODS

The Faculty of Dental Medicine, Universitas Airlangga, issued a Certificate of Ethical Eligibility for this study with the number 423/HRECC.FODM/IX/2020, and the study was conducted in compliance with the standards of animal ethics and care. This study employed 32 experimental white male rats (*Rattus norvegicus*) that were three months old and weighed 150–200 grams in vivo in an experimental lab setting with a post-test-only design. Samples were chosen at random, and the Lemeshow sample size formula was used to calculate the sample size, which led to eight samples for each sample group. For pain relief while extracting the mandibular incisor from each animal to create an alveolar bone defect, 0.2 ml of ketamine was intramuscularly injected into the gluteus muscle. Each mandibular incisor socket was left with blood in the control group. Extracted gourami scale collagen was used to fill each mandibular incisor socket in the treatment group. BMP4 and FGF2 markers were examined on seventh and 14 days after the rats in the treatment group were given 30 mg of gourami scales collagen extract.

The gourami scales were obtained by washing fish scales and freezing them; then, 100 grams were taken and soaked in a 6% acetic acid solution for seven days. During the soaking process, the acetic acid solution was changed daily. After seven days, the process continued by running water over the fish scales until a pH of neutral was reached. Collagen strands emerged during rinsing, and collagen clots formed. The collagen was then freeze-dried for 12 hours at a condensing temperature of -76°C and an ambient temperature of 23.6°C to completely eliminate all water content. The sterilizing of the collagen products was accomplished utilizing ethylene oxide gas. After being cultured for seven and 14 days, the levels of BMP4 and FGF2 expression in the osteoblast cells were analyzed using an immunohistochemical test. The data collection was based on the number of osteoblasts expressing BMP4 and FGF2. Immunohistochemical representation of incisor socket preparations stained with immunohistochemical techniques, using monoclonal antibodies BMP4 (3C11C7) NBP2-52424 and FGF2 (C-2): sc-74412 (St Cruz, US).

Table 1. Mean and standard deviations of BMP4 and FGF2 expression

Marker	Group	Day	Mean \pm SD
BMP4	Control	7	5.09 \pm 1.494
		14	10.22 \pm 1.863
	Treatment	7	9.50 \pm 2.615
		14	15.75 \pm 3.251
FGF2	Control	7	5.56 \pm 1.870
		14	8.69 \pm 1.782
	Treatment	7	13.41 \pm 2.074
		14	17.63 \pm 1.350

RESULTS

The data collection was based on the number of osteoblasts expressing BMP4 and FGF2. Table 1 shows that on days seven and 14, the average expression level of BMP4 in the treatment group was higher than that in the control group. The highest average was obtained in the treatment group on day 14. Table 1 also suggests that when compared with the control group, the expression of FGF2 was significantly higher in the treatment group. The treatment group's greatest average was achieved on day 14.

Images of the immunohistochemical representations of incisor socket preparations using monoclonal antibody BMP4 (3C11C7) NBP2-52424 stained using

immunohistochemical techniques can be seen in Figures 1 and 2. Using various magnifications, images A, B, and C represent the expression of BMP4 in the control group. Image A is magnified 40x, image B is magnified 200x, and image C is magnified 1000x until BMP4 is clearly visible. In contrast, images D, E, and F show the results of the treatment group with magnifications of 40x, 200x, and 1000x. In Table 1, it can be seen that the treatment group had more BMP4 than the control group. It can be concluded that the expression of BMP4 on treatment group day 14 showed highest results, with an average number of 15.75.

Data retrieval research results were based on the number of osteoblasts expressing FGF2. Images of the

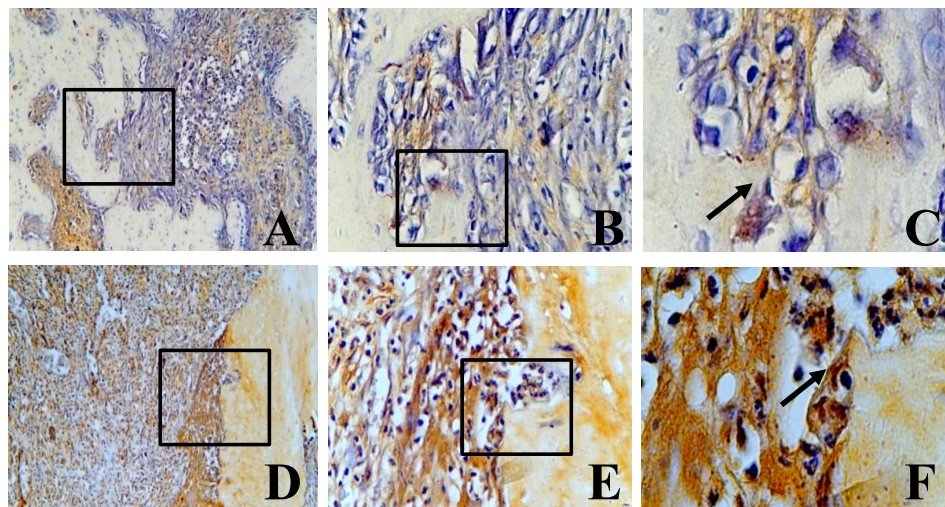


Figure 1. Expression of BMP4 in incisor socket preparations with monoclonal antibody BMP4 stained using immunohistochemical techniques. A–C show BMP4 expression in the control group after seven days at 40x, 200x, and 1000x magnification, respectively. D–F show BMP4 expression in the treatment group after seven days at 40x, 200x, and 1000x magnification, respectively.

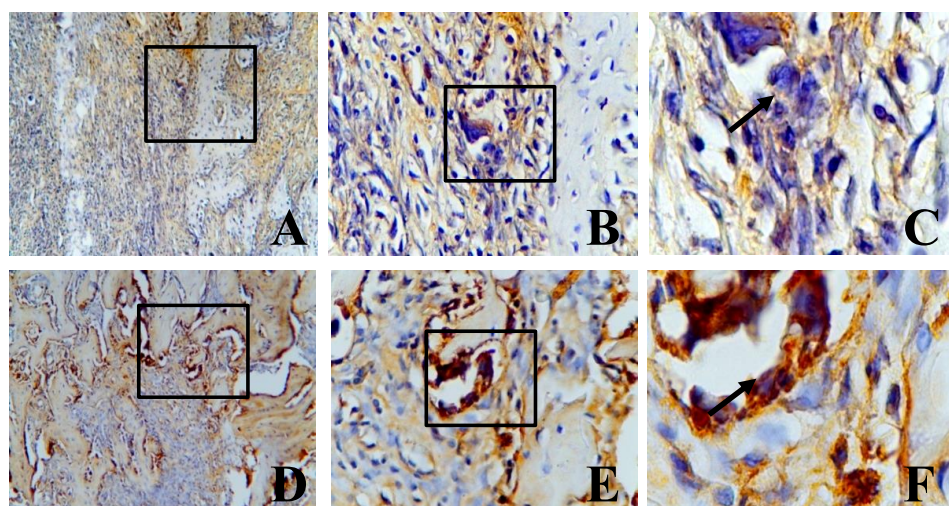


Figure 2. Expression of BMP4 in incisor socket preparations with monoclonal antibody BMP4 stained using immunohistochemical techniques. A–C show BMP4 expression in the control group after 14 days at 40x, 200x, and 1000x magnification, respectively. D–F show BMP4 expression in the treatment group after 14 days at 40x, 200x, and 1000x magnification, respectively.

immunohistochemical representation of incisor socket preparations using monoclonal antibody FGF2 (C-2): sc-74412 stained using immunohistochemical techniques can be seen in Figures 3 and 4. Similar to Figures 1 and 2, Figures 3 and 4 show the expression of FGF2 in the control group (Figures A, B, and C) and the treatment group (Figures D, E, and F). In the treatment group, the amount of FGF2 also increased compared with the control group, with highest results on day 14, as shown in Figure 4, with an average number of 17.63.

The results of the study were analyzed using SPSS 16 software, and the output of the results of the analysis can be seen in the attachment sheet, while the explanation of the test results will be discussed below. The data needed to be normally distributed in order to be used in the parametric

analysis. The testing of the data distribution for each group was carried out using the Shapiro–Wilk test. Significant value of normality test with Shapiro–Wilk test for marker BMP4 was $p: 0.101$ ($p > 0.05$) and FGF2 was $p: 0.209$ ($p > 0.05$), which meant that all the data were normally distributed (Table 2). Levene’s test of homogeneity showed $p > 0.05$, indicating that the BMP4 and FGF2 markers

Table 2. BMP4 and FGF2 normality tests

Marker	Shapiro–Wilk		
	Statistic	df	Sig.
FGF2	0.945	32	0.101
BMP4	0.956	32	0.209

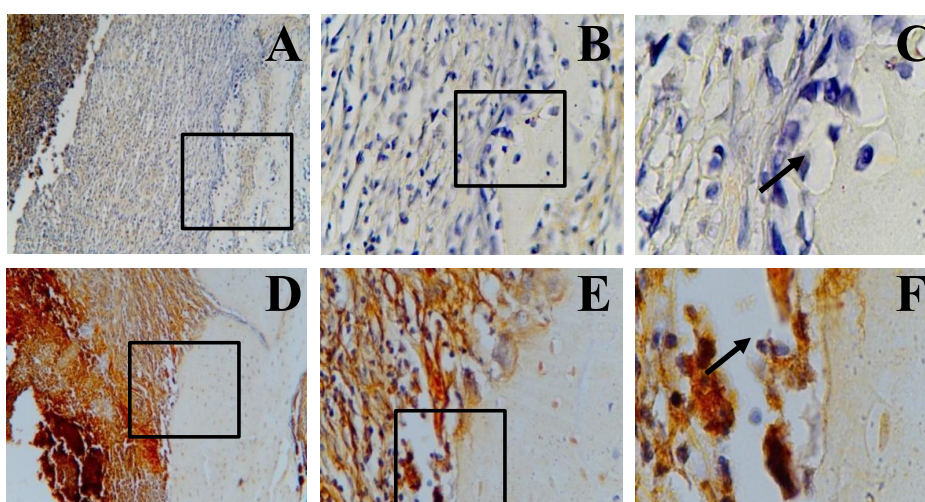


Figure 3. Expression of FGF2 in incisor socket preparations with monoclonal antibody FGF2 stained using immunohistochemical techniques. A–C show FGF2 expression in the control group after seven days at 40x, 200x, and 1000x magnification, respectively. D–F show FGF2 expression in the treatment group after seven days at 40x, 200x, and 1000x magnification, respectively.

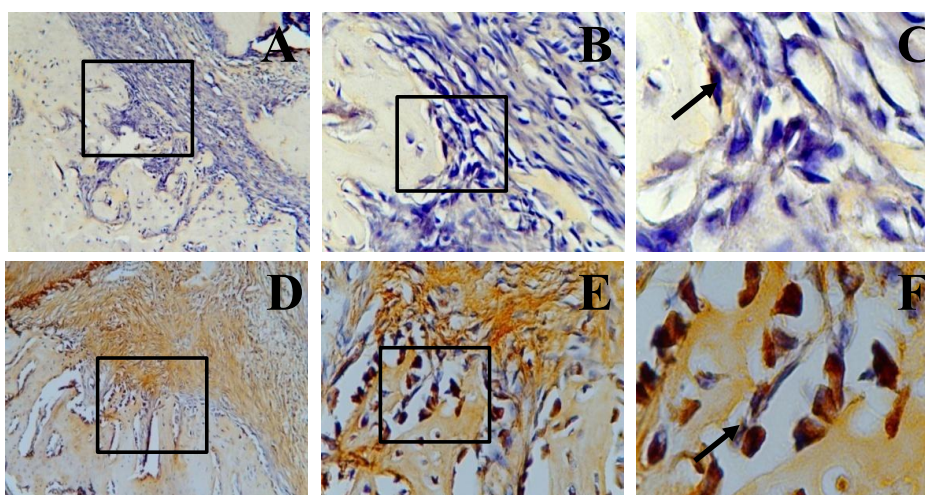


Figure 4. Expression of FGF2 in incisor socket preparations with monoclonal antibody FGF2 stained using immunohistochemical techniques. A–C show FGF2 expression in the control group after 14 days at 40x, 200x, and 1000x magnification, respectively. D–F show FGF2 expression in the treatment group after 14 days at 40x, 200x, and 1000x magnification, respectively.

showed homogeneous variations between the different groups. Then, the data analysis was continued using the one-way analysis of variance (one-way ANOVA) parametric test. This test was used to compare the levels of BMP4 and FGF2 expression in the control and treatment groups to see if there were any significant differences. The results showed that the treatment group’s levels differed significantly, with significance levels of BMP4 Sig. 0.000 and FGF2 Sig. 0.000 as shown in Figure 5 and 6.

A post hoc test was conducted using Tukey’s honestly significant difference test (Tukey’s HSD) after the results from the one-way ANOVA test had been obtained, and it showed significant differences. This test was completed to

determine the differences between the research groups, and they differed significantly. The significance levels using Tukey’s HSD for markers BMP4, Sig. 1.000 ($p > 0.05$), and FGF2, Sig. 1.000 ($p > 0.05$), indicated that there was a substantial difference between the research groups based on the post hoc test (Table 3).

DISCUSSION

The bone regeneration process necessitates three basic components, namely osteoprogenitor cells (stem cells, osteoblasts, cementoblasts, and fibroblasts), signaling

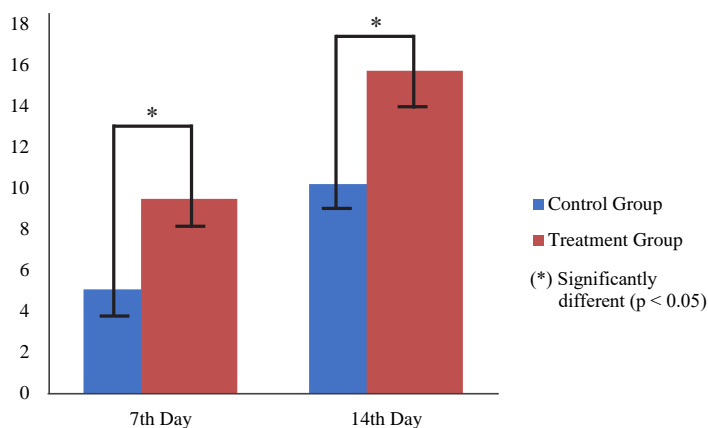


Figure 5. Expression of BMP4 in all groups.

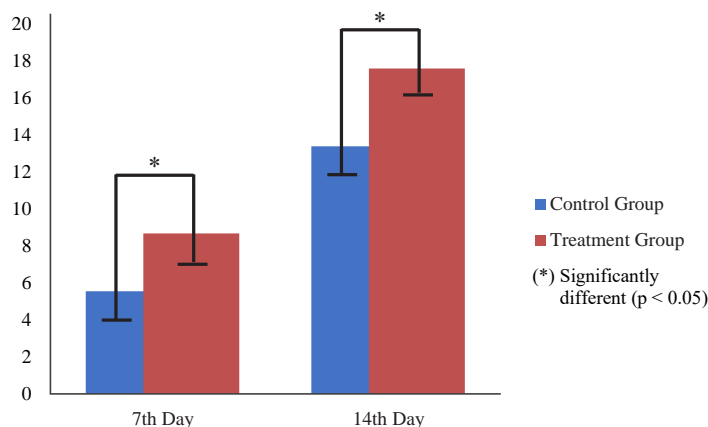


Figure 6. Expression of FGF2 in all groups.

Table 3. Result of BMP4 and FGF2 HSD testing

Groups	N	Subset for alpha = 0.05							
		BMP4			FGF2				
		1	2	3	1	2	3	4	
Control 7	8	5.09			5.56				
Treatment 7	8		9.50			8.69			
Control 14	8		10.22				13.41		
Treatment 14	8			15.75					17.63
Significance level		1.000	.932	1.000	1.000	1.000	1.000	1.000	1.000

molecules (BMP, FGF, and PRP), and scaffolds (collagen, fibrin, polyglycolide, polylactide polymer, and copolymer), to regulate the differentiation and function of osteoprogenitor cells in damaged periodontal tissues to form new bone, cementum, and periodontal ligament.¹⁸ There are two cells that regulate bone homeostasis: osteoblasts for bone formation and osteoclasts for bone resorption. Osteoblasts develop from mesenchymal stem cells (MSCs) and play a major part in bone mass maintenance and regeneration, bone quality determination, and skeletal system function.¹⁹

Collagen can be extracted from various sources; some of the most commonly used collagen sources for tissue engineering are bovine (skin, bone, and tendon), porcine (skin and bone), and marine animals (fish, prawn, octopus, squid, cuttlefish, starfish, jellyfish, sponges, sea urchin, and sea anemone). Fish collagen can be extracted from bones, skin, fins, and scales.²⁰ Fish collagen has several advantages, including a high level of security (no hand, foot, and mouth disease from pigs or *spongiform encephalopathy* from cows), a high absorption rate, a low cost, biocompatibility, and no religious restrictions.²¹

This study used fish scale collagen, which was applied to the tooth sockets of rats and then analyzed on days seven and 14, which revealed that the treatment group's mean expression of BMP4 and FGF2 was higher than that of the control group. The inflammatory process had stopped by day seven, and proinflammatory mediators had started to play a major part in the regeneration process. When specific MSCs are activated, they can proliferate and differentiate into osteogenic cells, allowing for bone regeneration. Bone formation can occur through intramembranous processes (direct) and endochondral processes (indirect). In both mechanisms, bone and cartilage induction occurs through epithelial–mesenchymal interactions initiated by specific cell differentiation. When mesenchymal progenitor cells are exposed to BMP, they can differentiate into osteoblasts and chondroblasts.²² This study shows that BMP can affect bone formation either directly or indirectly. In this study, day seven was selected not only because it was the end of the inflammatory process but also because the height of soft callus formation occurs in experimental rats on days seven to nine post-trauma. Day 14 marks the height of the formation of hard callus and the process of mineralization of bone tissue. During hard callus formation, woven bone replaces the calcified cartilage, making the callus denser and mechanically harder.

BMP4 is a key inducer of osteoblast differentiation and bone production.¹⁹ It also stimulates the ossification of soft bones during the period of bone development. Prior to the production of soft bone and new bone, BMP4 is expressed in considerable numbers within six hours of a bone fracture, reaching 10 times the baseline value and gradually decreasing to the baseline level within 72 hours. Collagen extract was added in this study, and day 14 saw a greater rise in BMP4 expression than day seven. On the seventh and 14th day of the experiment, there was less expression of BMP4 in the intervention group compared

to the control group. This suggests a beneficial impact on the tooth socket's bone-formation process. BMP4 was present in the soft bone cells, mesenchymal cells, bone marrow cavities, muscle cells in the vicinity of broken bones, and periosteum.¹¹ This demonstrates how crucial a function BMP4 plays in fracture repair. By suppressing osteoclastogenesis, BMP4 indirectly promotes bone growth.

The most popular FGF ligand for use in regenerative medicine, including bone regeneration, is FGF2.²³ FGF2 is a fundamental FGF that, through a variety of mechanisms, including vasoformative processes, is thought to encourage cell proliferation and differentiation. Angiogenesis, wound healing, and bone regeneration are all facilitated by FGF2. FGF2 acts as a trigger for mesenchymal stem cell differentiation and proliferation during bone repair. Additionally, FGF2 has potent angiogenic effects.²⁴ Rats lacking FGF2 saw a marked decline in bone mass and a reduction in bone formation.²³ This assertion backs up research findings showing that administering collagen extract boosts FGF2 expression.

Another study discovered that the treatment of FGF2 can promote fibroblast cell proliferation, angiogenesis, and bone production, which can boost periodontal regeneration.¹² Moreover, in a study using individuals with a diagnosis of aggressive periodontitis, in comparison with the control group, it was observed that vertical bone defects had more alveolar bone.²⁵ Collagen extract can speed up bone development and be employed as an alternative regenerative material for bone production, according to this study's findings of increased expression of BMP4 and FGF2. Whereas FGF2 participates in angiogenesis, which is crucial for periodontal regeneration, BMP4 works to induce osteoblast differentiation. According to the findings of the immunohistochemical experiment, the osteoblast cell culture clearly expressed BMP4 and FGF2 after receiving collagen obtained from gourami (*Osphronemus goramy*) fish scales. In conclusion, the use of gourami (*Osphronemus goramy*) fish scale collagen in osteoblast culture increases the expression of BMP4 and FGF2.

REFERENCES

1. Ramadhani NF, Nugraha AP, Gofur NRP, Permatasari RI, Ridwan RD. Increased levels of malondialdehyde and cathepsin C by aggregatibacter actinomycetemcomitans in Saliva as aggressive periodontitis biomarkers: A review. *Biochem Cell Arch.* 2020; 20: 2895–901.
2. Andriani I, Medawati A, Humanindito MI, Nurhasanah M. The effect of antimicrobial peptide gel RISE-AP12 on decreasing neutrophil and enhancing macrophage in nicotine-periodontitis Wistar rat model. *Dent J.* 2022; 55(2): 93–8.
3. Wulandari P, Widkaja D, Nasution AH, Syahputra A, Gabrina G. Association between age, gender and education level with the severity of periodontitis in pre-elderly and elderly patients. *Dent J.* 2022; 55(1): 16–20.
4. Ramadhani NF, Nugraha AP, Gofur NRP, Ridwan RD. Elevation of c-reactive protein in chronic periodontitis patient as cardiovascular disease risk factor. *Biochem Cell Arch.* 2020; 20: 2875–8.

5. Aprilianti NA, Rahmadhani D, Rizqianti Y, Ridwan RD, Ramadhani NF, Nugraha AP. Periodontal ligament stem cells, solcoseryl pasta incorporated nano-hydroxyapatite silica gel scaffold for bone defect regeneration in chronic periodontitis: A review. *Biochem Cell Arch*. 2020; 20: 3101–6.
6. Saskianti T, Nugraha AP, Prahasanti C, Ernawati DS, Suardita K, Riawan W. Immunohistochemical analysis of stem cells from human exfoliated deciduous teeth seeded in carbonate apatite scaffold for the alveolar bone defect in Wistar rats (*Rattus norvegicus*). *F1000Research*. 2020; 9: 1164.
7. Khan R, Khan M. Use of collagen as a biomaterial: an update. *J Indian Soc Periodontol*. 2013; 17(4): 539–42.
8. Kakarla P, Sai J, Avula S, Anche S, MJS P. Collagen as a biomaterial in dentistry. *Int J Innov Med Heal Sci*. 2016; 7: 1–4.
9. Prahasanti C, Wulandari DT, Ulfa N. Viability test of fish scale collagen (*Oshpronemus gouramy*) on baby hamster kidney fibroblasts-21 fibroblast cell culture. *Vet World*. 2018; 11(4): 506–10.
10. Kajioka D, Suzuki K, Nakada S, Matsushita S, Miyagawa S, Takeo T, Nakagata N, Yamada G. BMP-4 is an essential growth factor for the initiation of genital tubercle (GT) outgrowth. *Congenit Anom (Kyoto)*. 2020; 60(1): 15–21.
11. Yang J, Shi P, Tu M, Wang Y, Liu M, Fan F, Du M. Bone morphogenetic proteins: Relationship between molecular structure and their osteogenic activity. *Food Sci Hum Wellness*. 2014; 3(3–4): 127–35.
12. Nagayasu-Tanaka T, Anzai J, Takaki S, Shiraiishi N, Terashima A, Asano T, Nozaki T, Kitamura M, Murakami S. Action mechanism of fibroblast growth factor-2 (FGF-2) in the promotion of periodontal regeneration in beagle dogs. Matsumoto T, editor. *PLoS One*. 2015; 10(6): e0131870.
13. Ulfah N, Rehuel Santoso S, Bargowo L, Kurnia S, Prahasanti C. The viability of collagen peptide from *Osphronemus goramy* fish scale extract on human gingival fibroblast. *Res J Pharm Technol*. 2022; 15(8): 3497–501.
14. Krismariono A, Wiyono N, Prahasanti C. Viability test of fish scales collagen from *osphronemus gouramy* on osteoblast cell culture. *J Int Dent Med Res*. 2020; 13(2): 412.
15. Wijaksana IKE, Prahasanti C, Bargowo L, Sukarsono RM, Krismariono A. OPG and RANKL expression in osteoblast culture after application of *Osphronemus gourami* fish scale collagen peptide. *J Int Dent Med Res*. 2021; 14(2): 618–22.
16. Tionardus M, Dwija Putra IGNA, Ulfah N, Krismariono A, Setiawatie E, Prahasanti C. Expression of ALP and TGF- β in osteoblast cell cultures after administering collagen peptide derived from *gouramy* (*Osphronemus goramy*) fish scales. *Dent Hypotheses*. 2021; 12(2): 73.
17. Bargowo L, Wijaksana IKE, Hadyan FZ, Riawan W, Supandi SK, Prahasanti C. Vascular endothelial growth factor and bone morphogenetic protein expression after induced by *gurami* fish scale collagen in bone regeneration. *J Int Dent Med Res*. 2021; 14(1): 141–4.
18. Prahasanti C, Nugraha AP, Saskianti T, Suardita K, Riawan W, Ernawati DS. Exfoliated human deciduous tooth stem cells incorporating carbonate apatite scaffold enhance BMP-2, BMP-7 and attenuate MMP-8 expression during initial alveolar bone remodeling in Wistar rats (*Rattus norvegicus*). *Clin Cosmet Investig Dent*. 2020; 12: 79–85.
19. Chang Y, Cho B, Kim S, Kim J. Direct conversion of fibroblasts to osteoblasts as a novel strategy for bone regeneration in elderly individuals. *Exp Mol Med*. 2019; 51(5): 1–8.
20. Silvipriya K, Kumar K, Bhat A, Kumar B, John A, Lakshmanan P. Collagen: Animal sources and biomedical application. *J Appl Pharm Sci*. 2015; 5(3): 123–7.
21. Chinh NT, Manh VQ, Trung VQ, Lam TD, Huynh MD, Tung NQ, Trinh ND, Hoang T. Characterization of collagen derived from tropical freshwater carp fish scale wastes and its amino acid sequence. *Nat Prod Commun*. 2019; 14(7): 1934578X1986628.
22. Rao S, Ugale G, Warad S. Bone morphogenetic proteins: Periodontal regeneration. *N Am J Med Sci*. 2013; 5(3): 161–8.
23. Charoenlarp P, Rajendran AK, Iseki S. Role of fibroblast growth factors in bone regeneration. *Inflamm Regen*. 2017; 37(1): 10.
24. Kuroda Y, Kawai T, Goto K, Matsuda S. Clinical application of injectable growth factor for bone regeneration: a systematic review. *Inflamm Regen*. 2019; 39(1): 20.
25. Yoshinuma N, Koshi R, Kawamoto K, Idesawa M, Sugano N, Sato S. Periodontal regeneration with 0.3% basic fibroblast growth factor (FGF-2) for a patient with aggressive periodontitis: a case report. *J Oral Sci*. 2016; 58(1): 137–40.