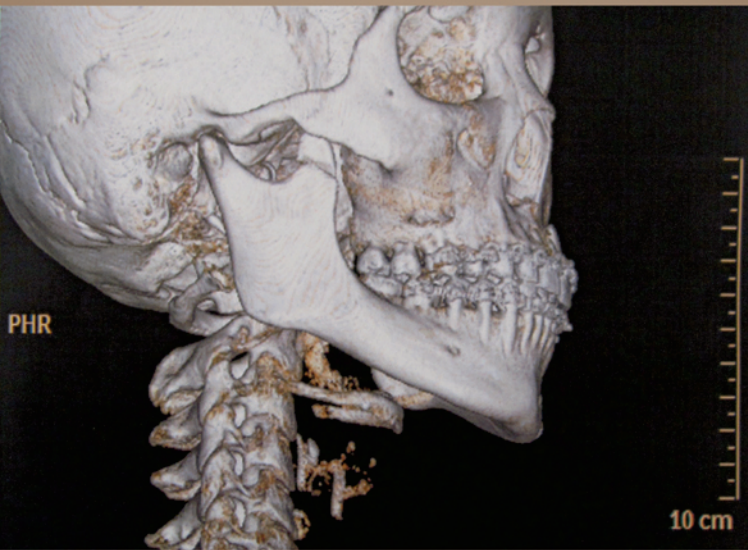


Dental Journal

Published quarterly per year

Majalah Kedokteran Gigi



• Ankylosis of the temporomandibular joint and mandibular growth disturbance caused by neglected condylar fracture in childhood • Enamel defect of deciduous teeth in small gestational age children • Integrated orofacial therapy in chronic rhinosinusitis management for children with sleep bruxism

Dental Journal

Majalah Kedokteran Gigi

CONTENTS

	<i>Page</i>
1. Erythema multiforme as the result of taking carbamazepine Maharani Laillyza Apriasari and M. Jusri	49–53
2. Tensile bond strength of hydroxyethyl methacrylate dentin bonding agent on dentin surface at various drying techniques Kun Ismiyatin	54–57
3. The efficacy of honey solution as plaque reducing agent Dewi Nurul M, Indria Rizki S, Indriani S, Masyitoh, and Auerkari EI	58–61
4. Optimum dose of 2-hydroxyethyl methacrylate based bonding material on pulp cells toxicity Widya Saraswati	62–66
5. Ankylosis of the temporomandibular joint and mandibular growth disturbance caused by neglected condylar fracture in childhood Endrajana	67–71
6. The effect of monofluorophosphate implant in white rat mothers towards the level of fluor in the incisors of the young babies (<i>Rattus-rattus</i>) Widjijono	72–75
7. Early removal of odontoma resulting in spontaneous eruption of the impacted teeth Achmad Harijadi	76–80
8. Dental modifications: a perspective of Indonesian chronology and the current applications Rusyad Adi Suriyanto and Toetik Koesbardiati	81–90
9. Enamel defect of deciduous teeth in small gestational age children Wilyanti S Syarif, Roosje R. Oewen, Sjarif H. Effendi and Bambang Sutrisna	91–96
10. Integrated orofacial therapy in chronic rhinosinusitis management for children with sleep bruxism Haryono Utomo	97–101
11. The apical leakage of mineral trioxide aggregate as the retrograde filling material with various mixing agents Ema Mulyawati	102–106

Daftar