

CASE REPORT

pISSN: 1907-3062 / eISSN: 2407-2230

Pulmonary embolism in a 51-year-old woman with chronic kidney disease

Triwedya Indra Dewi,^{1*} Melawati Hasan,¹ and Fathy Fathini²

ABSTRACT

BACKGROUND

Chronic kidney disease (CKD) is a worldwide public health problem both in terms of the number of patients and the cost of treatment. Chronic kidney disease seems to be the main driver of pulmonary embolism (PE) in dialysis patients. The diagnosis of PE is difficult due to its non-specific signs and symptoms, especially in many comorbidities with similar features. Chronic kidney disease plays a role in both the incidence of venous thromboembolism and the manifestations of pulmonary hypertension, resulting in an increased risk of morbidity and mortality. Advances in the management of patients with suspected PE have improved diagnostic accuracy. An approach using several diagnostic tools with different characteristics, such as D-dimer measurement, and imaging tests-predominantly computed tomography pulmonary angiography (CTPA) - can help evaluate the diagnosis.

CASE DESCRIPTION

Here we report the case of a 51-year-old woman with a history of chronic kidney disease, who presented with sudden worsening of dyspnea. Further examination showed signs of right heart failure with a high probability of pulmonary hypertension on echocardiography. Based on the general features it is difficult to distinguish between acute pulmonary embolism and chronic pulmonary hypertension, both of which can be caused by the underlying chronic kidney disease. Nevertheless, gold standard imaging using CTPA confirmed the diagnosis of pulmonary embolism, with underlying pulmonary hypertension from chronic kidney disease.

CONCLUSIONS

The diagnosis of pulmonary embolism with comorbidities is challenging. The availability of diagnostic modalities will confer different advantages and particular accuracy to meet the challenges in diagnosis.

Keywords: Pulmonary embolism, pulmonary hypertension, chronic kidney disease

¹Department of Cardiology and Vascular Medicine

Dr. Hasan Sadikin Hospital

²Resident at Department of Cardiology and Vascular Medicine, Faculty of Medicine, Padjadjaran University

***Correspondence:**

Triwedya Indra Dewi
Department of Cardiology and Vascular Medicine,
Dr. Hasan Sadikin Hospital, Pasteur,
Sukajadi, Bandung, 40161, Indonesia
Phone : +6281321770341
Email: t_indradewi@yahoo.co.id
ORCID ID: 0000-0002-5203-4726

Date of first submission, December 26, 2020

Date of final revised submission, May 13, 2021

Date of acceptance, May 24, 2021

This open access article is distributed under a Creative Commons Attribution-Non Commercial-Share Alike 4.0 International License

Cite this article as: Dewi TI, Hasan M, Fathini F. Pulmonary embolism in a 51-year-old woman with chronic kidney disease. *Univ Med* 2021;40:157-62. doi: 10.18051/UnivMed.2021.v40.160-165



INTRODUCTION

Chronic kidney disease (CKD) plays an important role in the manifestation of either pulmonary embolism or pulmonary hypertension, which present with non-specific signs and symptoms, making the diagnosis more difficult.⁽¹⁾ The availability of diagnostic tools with particular characteristics and accuracy can better meet the challenges in diagnosis.

Chronic kidney disease has some of the primary risk factors of pulmonary embolism (PE).⁽²⁾ Pulmonary embolism is an important problem, and the third most frequent acute cardiovascular disease worldwide, other than myocardial infarction and stroke.⁽³⁾ Recent studies have shown that PE has prevalence rates from 39-115 per 100,000 population and causes <300,000 deaths per year in the US, ranking high among the causes of cardiovascular mortality.⁽⁴⁾ Pulmonary embolism is frequent among cardiovascular disease, but the diagnosis remains ambiguous. Clinical suspicion is essential when seeing a patient with cardiopulmonary symptoms.⁽⁵⁾ Acute PE is the result of a complicated relationship between different organs; therefore, the clinical symptoms are diverse and non-specific. It is difficult to make an immediate diagnosis, especially in many comorbidities complicating the condition, as described in this case of a patient with pulmonary embolism with signs of pulmonary hypertension (PH) and underlying chronic kidney disease. Non-invasive imaging tests enable the clinician to suspect and initiate further workup for PE, with computed tomography pulmonary angiography (CTPA) being the principal tool.⁽⁶⁾ Unfortunately, the widespread use of multidetector CTPA without selection of patients has introduced new issues, such as overdiagnosis and exposure to radiation.⁽⁷⁾ An effort to implement the robust validated strategies in clinical practice could overcome some of these problems.

Here we report the case of a woman with acute pulmonary embolism who had pulmonary

hypertension and dialysis-dependent chronic kidney disease. The purpose of this case report is to highlight the roles of different modalities with different accuracy to help establish the diagnosis.

CASE REPORT

A 51-year-old woman came to our hospital with the chief complaint of sudden worsening of shortness of breath with symptoms of right heart failure. The patient had a history of immobilization, uncontrolled hypertension, and chronic kidney disease and was on hemodialysis. On physical examination stable hemodynamics and signs of right heart failure were found, while laboratory examination showed anemia (Hb 9.8 g/dL) and lowered kidney function (serum urea 52 mg/dL and creatinine 5.28 mg/dL). The ECG showed a normal sinus rhythm with no sign of a deep S wave in lead I, of a Q wave in lead III, of an inverted T wave in lead III; or right ventricular strain. Echocardiography revealed a normal left ventricular (LV) function, a dilated right ventricle (RV) with impaired function (tricuspid annular plane systolic excursion/TAPSE) of 16 mm, longitudinal strain -13.4%, pericardial effusion, and also signs suggesting a high probability of pulmonary hypertension (Figure 1). We found no signs of PE, such as McConnell's sign and the 60/60 sign. We decided to perform CT pulmonary angiography and found a hypodense lesion within the lateral wall of the main pulmonary artery, right main pulmonary artery, and the superior and inferior right trunk, with central filling defect (polo mint sign) due to thrombus, and dilatation of the main pulmonary artery (Figure. 2). After analyzing the resulting CTPA and echocardiography signs suggesting PH, we diagnosed this case as acute pulmonary embolism with stable hemodynamics in a patient with suspected pulmonary hypertension in chronic kidney disease. The patient was treated with parenteral anticoagulation for ten days, overlapping with an oral anticoagulant, and the patient was discharged in a stable condition and

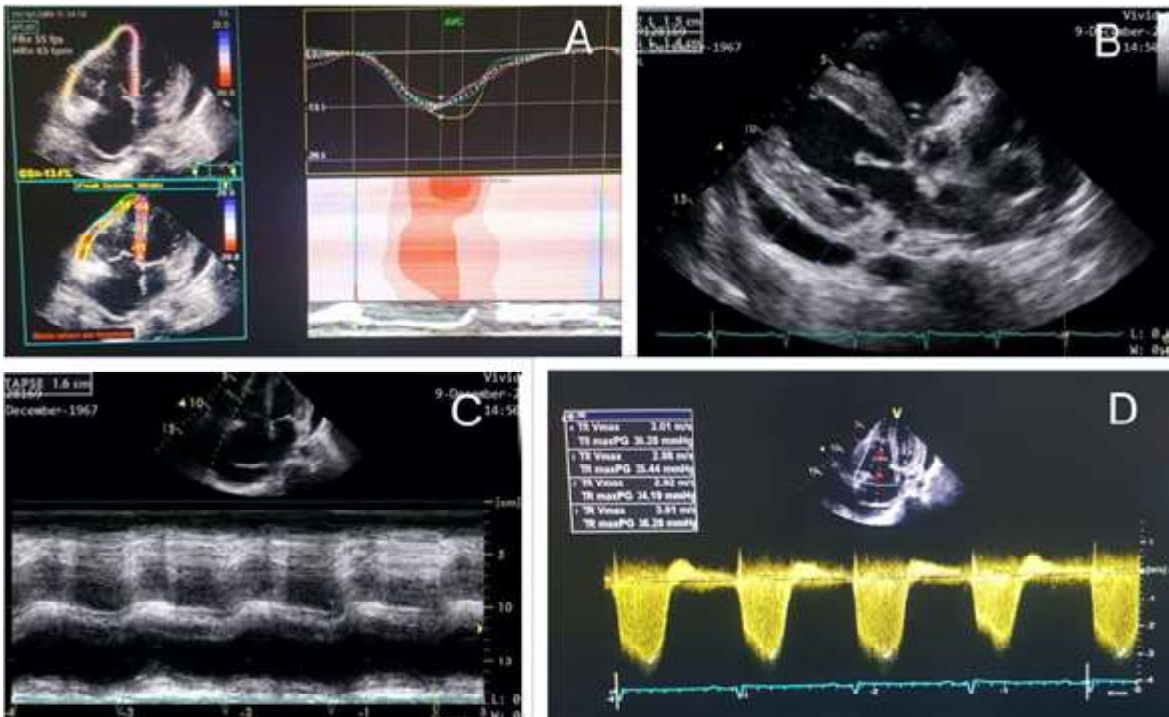


Figure 1. Echocardiography parameters

Echocardiography parameters indicate reduced RV function and the probability of PH. (A) Free-wall strain of -13.4%; (B) Moderate pericardial effusion; (C) Reduced TAPSE value of 16 mm; (D) Mean TR velocity of 2.98 m/s; without signs of pulmonary embolism. RV= right ventricle; PH= pulmonary hypertension; TAPSE= tricuspid annular plane systolic excursion; TR= tricuspid regurgitation

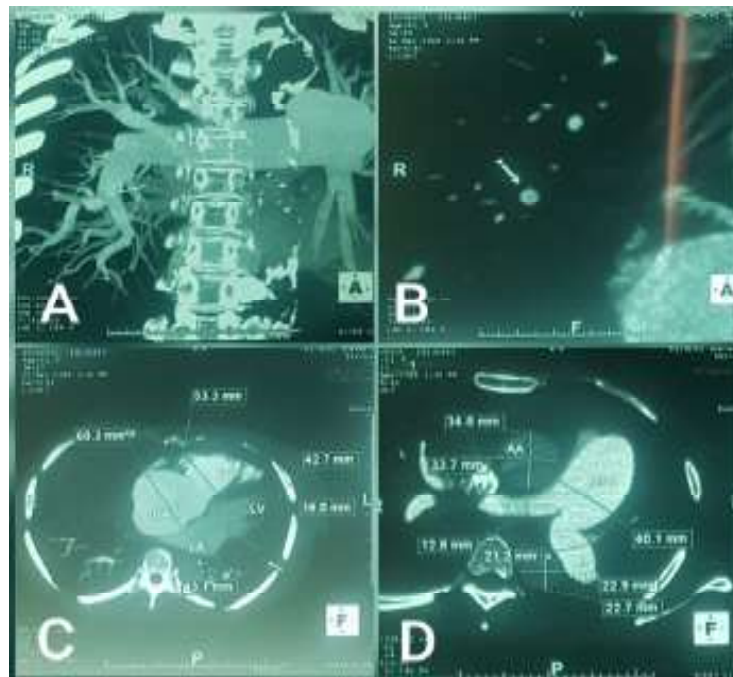


Figure 2. MSCT of pulmonary embolism.

MSCT images showing (A) Hypodense lesion in the lateral wall of MPA, RPA; (B) Central filling defect (Polo Mint Sign); (C) Dilatation of all cardiac chambers; (D) Dilatation of MPA and ratio of MPA to ascending aorta diameter is >1 . Abbreviations: MSCT= multi-slice computed tomography; MPA= main pulmonary artery; RPA= right pulmonary artery

showing improvement in symptoms. Further evaluation on pulmonary hypertension is mandatory to conclude the working diagnosis according to the diagnostic algorithm stated in the guidelines, but due to loss to follow-up there are no further data regarding the outcomes or further PH diagnosis. Written informed consent was obtained from the patient for publication of this case report.

DISCUSSION

Chronic kidney disease can increase the risk of thromboembolism by affecting both pro-coagulant and anticoagulant factors. Chronic kidney disease has significant changes in all important factors of coagulation, as determined by Virchow's triad. Abnormalities in the coagulation cascade and platelet function may lead to the tendency of thrombosis or bleeding, depending on the defect.⁽²⁾ One study showed that the occurrence of pulmonary embolism in patients with CKD is 7.6 times higher than in patients with normal kidney function, and also has a higher mortality.⁽⁸⁾

Acute pulmonary embolism is the most serious clinical presentation of venous thromboembolism (VTE). It is often clinically silent or mimics the diagnostic features of other conditions, resulting in under-diagnosis.⁽⁶⁾ Prediction rules using the Wells score help categorize patients with suspected PE into different categories of pre-test probabilities and decide if the diagnostic workup should be initiated. The probability of this patient was likely (intermediate) and needed further evaluation. D-dimer has a high negative predictive value (NPV), and low positive predictive value (PPV) and is not useful for confirmation of PE. In our case, we did not check the D-dimer due to the low PPV of an in-hospital patient. The ECG features in PE comprise a wide range of abnormalities; 10-25% of patients have a completely normal ECG, such as in our case. The S1Q3T3 pattern (McGinn-White sign) is a classic finding found PE cases with a high specificity of 95%, but a

low sensitivity of 5%.⁽⁹⁾ Multivariable analysis of ECG characteristics using the TwiST score describes right ventricular (RV) strain pattern due to increased pressure and wall tension in the right heart. Among these ECG characteristics, the most common finding associated with pulmonary embolism is an S wave in lead I, followed by a T wave inversion (TWI) in leads V1-V3, and a tachycardia of ≥ 100 bpm. The higher the TwiST score, the higher the specificity (97-100%), but the lower the sensitivity (1-7%), with PPV 40-100% and NPV 44-56%.⁽⁹⁾ Echocardiography in the diagnosis of acute PE is a favorable alternative, since it is non-invasive, is standardized almost in all cardiology centers, and can be performed at the bedside. Right ventricular dysfunction and pressure overload are a common feature in pulmonary embolism, and can be detected by echocardiography. In suspected acute PE, echocardiographic signs are inadequate to rule out PE and only an enlarged RV end-diastolic diameter is 80% sensitive for acute PE. There are also other highly specific signs, such as right heart thrombus with 99% specificity, followed by McConnell's sign (RV mid free wall akinesia and apical wall hypercontractility) with 97% specificity, and paradoxical septal movement with 95% specificity.⁽¹⁰⁾ These specificities remain high when performed by a non-cardiologist. However, in our case, we only found a high probability of PH but no specific echocardiographic signs suggesting PE. Although echocardiography produces potentially valuable findings, acute PE cannot be differentiated from other causes of RV failure. Echocardiographic findings of RV pressure overload are differentiated into acute and chronic. Tricuspid annular plane systolic excursion (TAPSE) is a widely recognized, obtainable, and validated parameter of global RV systolic function and also has prognostic value for PE.⁽⁴⁾ A right heart thrombus is found in 2-4% of acute PE patients and increases the risk of short-term mortality to 20% in acute PE.⁽¹⁰⁾

Computed tomography pulmonary angiography is the best modality for showing the

pulmonary vascularization in patients with suspected PE. The diagnosis of PE using CTPA has an outstanding accuracy, with a sensitivity of 83% and a specificity of 96%.⁽⁴⁾ Several studies showed that CTPA is a reliable imaging test for excluding PE. Findings for positive CT results include a partial filling defect or central filling defect within the vessel surrounded by contrast material known as the “polo mint sign” on images acquired perpendicular to the long axis and the “railway track sign” on the longitudinal axis of the vessel.⁽¹²⁾ Computed tomography pulmonary angiography also provides substantial information on vascularity, cardiac anatomy, and the anatomy or abnormality of adjacent structures. Furthermore, CTPA can provide clues to the etiology of PH and other diagnostic information. PH signs in CTPA include dilatation of the main pulmonary artery (MPA) (>33 mm), an MPA to ascending aorta diameter ratio of >1.1, RV enlargement or hypertrophy, an RV to LV diameter ratio of >1, and bending of the ventricular septum toward the LV. The CTPA when used in the diagnosis of chronic PH based on PA diameter has an average accuracy, with a sensitivity of 47-87% and specificity of 41-100%.⁽¹³⁾

Pulmonary hypertension with unclear and/or multifactorial mechanisms or group 5 PH, is a form of the disease with poorly understood mechanisms, the etiologies of which include pulmonary vasoconstriction, extrinsic compression, intrinsic occlusion, high-output cardiac failure, and left heart failure.⁽¹⁴⁾ One of the disorders that can cause group 5 PH is chronic renal failure. The mechanism of pulmonary hypertension in kidney disease is mostly venous in origin due to left ventricular dysfunction caused by chronic volume overload and pulmonary venous hypertension. Comorbid conditions in CKD may contribute to and/or exacerbate pulmonary hypertension. Hypertension and diabetes mellitus are two dominant causes of CKD that can increase pulmonary pressure, and trigger LV diastolic dysfunction. In one study, PH in CKD was found in 81% of hemodialysis

patients and in 71% of non-dialysis patients.⁽¹⁴⁾ The mechanism is multifactorial; such as anemia and arterio-venous fistula (AVF), both of which can cause a high output state. AVF has profound hemodynamic effects that lead to decreased systemic vascular resistance, increased venous return, and a significant increase in cardiac output. Because the pressure is directly related to flow and resistance, these adaptations eventually will lead to PH.⁽¹⁵⁾ Therefore, an increase in pulmonary flow may lead to increased pressure and eventually to pulmonary hypertension.⁽¹⁶⁾


CONCLUSIONS

The risk of either pulmonary embolism or pulmonary hypertension is increased in kidney disease, and several mechanisms certainly play an important role in either manifestation. In general, imaging modalities provide useful information, with varying sensitivity and specificity, which helps to identify the problem and either rule in or rule out the diagnosis. Therefore, the diagnosis of either condition is very challenging, and multiple team evaluation is necessary to provide the best management possible.

CONFLICT OF INTEREST

The authors declare that there are no conflicts of interest.

CONTRIBUTORS

TID contributed to conception or design of the work, and to writing, review, and editing. MH contributed to review and editing. FF contributed to revision of the manuscript. All authors have read and approved the final manuscript. 

REFERENCES

1. Hill NR, Fatoba ST, Oke JL, et al. Global prevalence of chronic kidney disease - a systematic review and meta-analysis. *PLoS One* 2016; 11: e0158765. doi: 10.1371/journal.pone.0158765.

2. Kumar G, Sakhuja A, Taneja A, et al. Pulmonary embolism in patients with CKD and ESRD. *Clin J Am Soc Nephrol* 2012;7:1584-90. DOI: <https://doi.org/10.2215/CJN.00250112>.
3. Nishiyama KH, Saboo SS, Tanabe Y, Jasinowodolinski D, Landay MJ, Kay FU. Chronic pulmonary embolism: diagnosis. *Cardiovasc Diagn Ther* 2018;8:253-71. doi: 10.21037/cdt.2018.01.09.
4. Konstantinides SV, Meyer G, Bueno H, et al. 2019 ESC Guidelines for the diagnosis and management of acute pulmonary embolism developed in collaboration with the European respiratory society (ERS). *Eur Heart J* 2020;41:543-603. doi: 10.1093/eurheartj/ehz405.
5. Howard L. Acute pulmonary embolism published correction appears in *Clin Med (Lond)* 2019;19:243-7. doi: 10.7861/clinmedicine.19-3-247.
6. Morrone D, Morrone V. Acute pulmonary embolism: focus on the clinical picture. *Korean Circ J* 2018;48:365-81. doi: 10.4070/kcj.2017.0314.
7. Konstantinides S V. Trends in incidence versus case fatality rates of pulmonary embolism: Good news or bad news? *Thromb Haemost* 2016;115:233-5. doi: 10.1160/th15-10-0832.
8. Kumar G, Sakhuja A, Taneja A, et al. Pulmonary embolism in patients with CKD and ESRD. *Clin J Am Soc Nephrol* 2012;7:1584-90. doi: 10.2215/CJN.00250112.
9. Hariharan P, Dudzinski DM, Okechukwu I, Takayesu JK, Chang Y, Kabrhel C. Association between electrocardiographic findings, right heart strain, and short-term adverse clinical events in patients with acute pulmonary embolism. *Clin Cardiol* 2015;38:236-42. doi:10.1002/clc.22383.
10. Dabbouseh NM, Patel JJ, Bergl PA. Role of echocardiography in managing acute pulmonary embolism. *Heart* 2019;105:1785-92. doi: 10.1136/heartjnl-2019-314776.
11. Ascha M, Renapurkar RD, Tonelli AR. A review of imaging modalities in pulmonary hypertension. *Ann Thorac Med* 2017;12:61-73. doi: 10.4103/1817-1737.203742.
12. Moore AJE, Wachsmann J, Chamrathy MR, Panjikanan L, Tanabe Y, Rajiah P. Imaging of acute pulmonary embolism: an update. *Cardiovasc Diagn Ther* 2018;8:225-43. doi:10.21037/cdt.2017.12.01.
13. Hur DJ, Sugeng L. Non-invasive multimodality cardiovascular imaging of the right heart and pulmonary circulation in pulmonary hypertension. *Front Cardiovasc Med* 2019;6:24. doi: 10.3389/fcvm.2019.00024.
14. Pabst S, Hammerstingl C, Hundt F, et al. Pulmonary hypertension in patients with chronic kidney disease on dialysis and without dialysis: results of the PEPPER-study. *PLoS One* 2012;7. doi: 10.1371/journal.pone.0035310.
15. Amerling R, Ronco C, Kuhlman M, Winchester JF. Arteriovenous fistula toxicity. *Blood Purif* 2011;31:113-20. DOI: 10.1159/000322695.
16. O'Leary JM, Assad TR, Xu M, et al. Pulmonary hypertension in patients with chronic kidney disease: invasive hemodynamic etiology and outcomes. *Pulm Circ* 2017;7:674-83. doi: 10.1177/2045893217716108.