

DENTITION AND AGE DETERMINATION OF THE WARTHOG *Phacochoerus aethiopicus* IN ZULULAND, SOUTH AFRICA

D.R. MASON*

*Mammal Research Institute
University of Pretoria
Pretoria
0002*

Abstract — Age-specific stages of tooth replacement, eruption and attrition are described for warthogs shot during population control in Zululand. Patterns of tooth replacement and eruption allowed reasonably accurate age determination up to 24 months, whereafter 2-3 year old warthogs could generally be distinguished from older individuals by the relative growth of their third molars. Although stages of wear and loss of the teeth, especially the three molars, were associated with broad age classes, age of adult warthogs may be determined more precisely by counting cementum annuli in sectioned incisor teeth. However, cementum annuli were insufficiently distinctive to permit age estimation in approximately 33% of sections, reflecting particularly variation in intensity and clarity of staining and splitting and merging of rest lines. The use of eye lens dry mass and tusk length: snout width ratios as indices of age was also evaluated. Eye lens dry mass became increasingly unreliable for predicting age beyond 24 months. Considering males and females separately, tusk length: snout width ratios for yearling, 2-3 year old and 3-4 year old warthogs were reasonably distinctive, but subsequent overlap was apparently unfavourable for reliable differentiation of year classes among older warthogs. Body size and tusk development criteria for distinguishing between three age classes of warthogs in the field are presented.

Introduction

Reliable estimation of age in warthogs (*Phacochoerus aethiopicus*) is important for interpreting their reproductive biology, growth and population

*New Address:

*Department of Research and Information
National Parks Board of Trustees
Private Bag X402
Skukuza
1350*

dynamics. Criteria commonly used for mammalian age determination include tooth eruption, replacement and attrition, patterns of dental cementum deposition, and various external morphological characteristics (Morris 1972). Aspects of the dentition and techniques for estimating age have been investigated in varying detail in previous studies of warthogs.

Middleton Shaw (1939), Guiraud (1948), Cooke & Wilkinson (1978) and Kingdon (1979) have described stages in the development and attrition of warthog teeth, especially the third molars, which reflect relative age. In West Africa, Bigourdan (1948) recorded dental formulae of male warthogs and estimated their chronological ages for various stages of attrition of their teeth.

Rough criteria for field age classification, based on body and tusk development, were described by Roth (1965). The pattern of tooth replacement and eruption reported in Zimbabwean warthogs (Child, Sowls & Mitchell 1965) was sufficiently distinctive to allow accurate age estimation up to two years, while the short, well defined breeding season facilitated clear distinctions in the field between three age classes (see also Cumming 1970, 1975) based on body and tusk size. Child, Sowls & Richardson (1965) have investigated mass of oven-dried eye lenses as an indicator of age. Changes in the development of warts and tusks as a guide to field age classification were illustrated by Cumming (1970), together with a description of distinctive physical characteristics over the annual cycle.

Because warthogs in Nairobi National Park, Kenya, have a distinct period of births, Bradley (1972) found that the ratios of tusk length to snout width, measured from a series of photographs, conveniently fell into four categories associated with age classes up to four years. Spinage & Jolly (1974) attempted to predict age beyond four years using an index of growth in the maxillary third molar teeth, but a lack of data from individuals of known age precluded their testing the validity of the relationship.

Besides the value of substantiating the results of studies in other geographic regions with comparative data, difficulties inherent in age estimation of warthogs from their dentition (Spinage & Jolly 1974) have emphasised the desirability of refining and possibly supplementing previously reported methods. In the present study, the availability of material from cropped specimens permitted the use of certain laboratory techniques to investigate age determination criteria; in addition, characteristics suitable for age classification in the field were examined.

Material and methods

Source of material

During cropping in the Hluhluwe-Corridor-Umfolozzi Game Reserve complex, Zululand, between June 1973 and June 1975, the skulls of 381 warthogs (183 males, 198 females) were collected to investigate dentition. Several skulls from old warthogs which died from natural causes were also collected and examined. Additional material (30 skulls from cropping plus one found skull of an infant) was collected in the Mkuzi Game Reserve, Zululand, where vegetation and physiographic conditions are analogous to a

large portion of the Hluhluwe-Umfolozi complex and the climatic regime is similar with a unimodal temperature, radiation and rainfall peak per annual cycle.

Dentition characteristics

Numbers of deciduous and permanent teeth present were recorded on check-sheets for all skulls examined, together with a description of approximate stages of eruption and attrition. The mesio-distal length of the crown (erupted portion above the gum line) was measured along the middle of the grinding surface for both upper and lower third molars on both sides.

Tusk length: snout-width ratios

Following Bradley (1968, 1972), the proportional relationship of tusk length and snout width with age was investigated for Zululand warthogs. Excluding young individuals where the upper tusks (canines) have not grown beyond the flanges of the lips, and those older individuals with portions of both tusks broken off, length of left and right maxillary canines was measured as the linear distance from the base of the tusk, where it protrudes from the lip, to the tip. Snout width between the tusks was measured as the maximum distance between the lip extremities.

Mean tusk-length was calculated as a percentage of snout-width, but wherever one tusk tip was broken off, the length of the undamaged tusk was used instead of the mean measurement. Tusk-length: snout-width ratios were calculated for 362 warthogs (187 males, 175 females) and plotted against the dates of collection to compare age-relative changes.

Tooth sections

Introduction

Since the early investigations of Laws (1952, 1953), the method of age estimation of mammals based on annulations or incremental lines in the cementum or dentine of sectioned teeth has been extensively applied and documented (*e.g.* Klevezal' & Kleinenberg 1969; Morris 1972; Spinage 1973; 1976a, b; Steenkamp 1975; Hall-Martin 1976; Hitchins 1978; Smuts, Anderson & Austin 1978; Attwell 1980; Jeffery & Hanks 1981; Penzhorn 1982). Among African mammals, age estimation from tooth sections has been used chiefly for herbivores. However, there appear to be no published accounts of the application of this technique to warthogs.

The warthog teeth selected for study were the mandibular first permanent incisor (I_1) and the maxillary third molar (M^3); however, choice may be limited to the latter tooth by the loss with age of most or all of the antecedent teeth, except the canines. Even before the incisors are worn to small remnants or shed completely, the phenomenon of root resorption (which commences at the root apex) could render these teeth unsuitable for age estimation of old warthogs. As Spinage (1973) has emphasised, resorption proceeds rapidly with senescence and "means that cementum line counts can only give the minimum age an old animal has reached, as an unknown number of lines are likely to have been resorbed."

Unless vestigial, I_1 was extracted from all skulls in addition to the large and complex M^3 , whose morphometry has been used as an indicator of age (Spinage & Jolly 1974). In practice, the scarcity of old warthogs from cropping meant that most tooth sectioning involved I_1 . Where M^3 was used, rectangular blocks of about 2 cm length and 1 cm thickness were cut from the mid-distal aspect of the tooth. Whole incisors or portions of third molars were then fixed in 10% neutral buffered formalin for at least four weeks.

Undecalcified sections

An experimental selection of formalin-fixed teeth was washed, dried and embedded in blocks of a clear polyester resin, using silicone rubber moulds. Teeth were sectioned using an Isomet low-speed saw with a diamond dusted disc blade of 0,1524 mm thickness, cooled in a water bath. Transverse and longitudinal sections 100 and 150 μ m thick were cut, both from the root portions of I_1 and the distal segments of M^3 , mounted in DPX, and examined with a projection microscope.

Decalcified sections

Initially, decalcification of warthog teeth was attempted using ethylene diamine tetracetic acid (disodium salt)(EDTA), which was found satisfactory for decalcifying giraffe teeth (Hall-Martin 1976). A solution of 18% EDTA at pH 7,4 was prepared by dissolving the EDTA in 0,1M phosphate buffer and adjusting the pH with sodium hydroxide. The tooth specimens were placed in EDTA at 60 °C, using a volume of the order of 20 times that of the tissue, and the decalcifying fluid was renewed every five days. In the absence of an X-ray apparatus to determine the end-point of decalcification, the palpation method as described by Disbrey & Rack (1970) was used. After 3-5 weeks in EDTA, the teeth became soft and pliable and decalcification was considered complete. The specimens were then dehydrated, cleared and embedded in paraffin wax, prior to sectioning on a sledge microtome.

Difficulties in cutting sections as a consequence of incomplete decalcification of the innermost tissue of some tooth specimens led to subsequent abandonment of EDTA in favour of a 1:1 v/v solution of 50% formic acid and 25% sodium citrate (recommended by Nell *pers. comm.**). Formalin-fixed incisors, placed in this formic acid-sodium citrate solution at ambient temperature, were completely decalcified after 2-3 weeks. The decalcifying fluid was renewed every 2-3 days. Incisor teeth were either treated whole or trimmed by removal of the crown. Decalcified specimens were washed for two hours in running tap water prior to dehydration and clearing using the following schedule (Nell *pers. comm.**):

1.	30% alcohol	2 h
2.	50% alcohol	2 h
3.	70% alcohol	2 h
4.	Butanol I	$\left\{ \begin{array}{l} 20 \text{ ml n-butyl alcohol} \\ 50 \text{ ml 95\% alcohol} \\ 30 \text{ ml distilled water} \end{array} \right\}$ 2 h

*Mr. J. Nell, Faculty of Dental Science, University of Pretoria, Pretoria 0002, S. Africa.

5.	Butanol II	{ 35 ml n-butyl alcohol 50 ml 95% alcohol 15 ml distilled water 55 ml n-butyl alcohol 45 ml 95% alcohol 75 ml n-butyl alcohol 25 ml 95% alcohol }	2 h
6.	Butanol III		2 h
7.	Butanol IV		2 h
8.	Butanol V	100% n-butyl alcohol	2 h
9.	Butanol VI	100% n-butyl alcohol	2 h
10.	Molten paraffin wax 52-53 ° C		2 h
11.	Molten paraffin wax 57-60 ° C		3 h

Specimens were then vacuum embedded in 57-60 ° C molten paraffin wax for 30 min. Several longitudinal sections of 6 and 10 μm thickness were cut through the sagittal plane of each tooth, using a sledge microtome. Longitudinal sections were chosen since "cementum growth is not uniform over the whole tooth root, and transverse sections may miss the zone of maximum increase in thickness" (Spinage 1976a). After mounting on labelled slides using Haupt's adhesive, sections were stained with Ehrlich's haematoxylin and aqueous eosin or Ehrlich's haematoxylin and chromotrope 2R, prior to mounting in DPX. Chromotrope 2R gave comparable results to eosin and was preferred due to the slightly shorter staining schedule, as given below:

1. Dewax in xylene 15 min
2. Sections to water
3. Ehrlich's haematoxylin 30 min
4. Blue in running tap water *ca* 8 min
5. Differentiate in acid alcohol 1-2 sec
6. Blue in running tap water *ca* 5 min
7. Rinse in distilled water 1 sec
8. Dehydrate
9. Chromotrope (saturated solution in absolute alcohol), 5 min
10. Rinse in absolute alcohol 1 sec
11. Xylene I, 5 min
12. Xylene II, 5 min

Counting of cementum annulations

Sections were first scanned under a binocular microscope at magnifications of $\times 63$ and $\times 160$ in order to find the best zones for reading of cementum annulations (usually the distal aspect above the root apex of incisors). Dark-staining rest lines that were clearly visible in one plane of a section were often not continuous along the length of the cementum; for example, it may be possible to count the earlier formed lines but not those of more recent origin in one region, while the remaining lines can only be discerned and counted further along the section.

Counts of the maximum number of dark-staining lines, excluding lamellae of very faint and discontinuous appearance, were routinely made under $\times 160$ magnification, but $\times 400$ magnification was sometimes used to check separ-

ation between very closely adjacent lines. The nature of the outermost layer, forking and merging of lines, and areas of discontinuity were noted.

Known-age material

Since warthogs in Zimbabwe have a definite and limited farrowing season, body development, tooth replacement and eruption, and tusk growth permit accurate age estimation up to 24 months, while growth of the third molars provides a reasonably reliable basis for further age estimation up to 36 months (Child, Sowls & Mitchell 1965). Farrowing in Zululand is virtually confined to the months of October, November and December (Mason 1982), so that the same criteria can be used to estimate age up to three years, thereby facilitating interpretation of the early patterns of formation of cementum lamellae.

In assigning age to older warthogs by counting rest lines in the cementum of permanent teeth, reference to known-age material is essential to determine the incremental rhythm of cementum deposition. Teeth from seven known-age warthogs up to eight years old (Table 1) were available from the Sengwa Wildlife Research Area, Zimbabwe, where although the seasonal climatic regime is similar, other conditions may differ from Zululand. In addition, the skull of a yearling aged 17,5-18,5 months was obtained from the Kruger National Park.

Table 1

Sources of known-age warthog teeth available for investigation of the chronological pattern of cementum layering

Age	Sex	Material	Locality	Material made available by:
17½-18½ months	?	Skull with dentition	Kruger National Park	B. Marshall, Natal Parks Board, S. Africa
23 months	♂	I ₁	Sengwa Wildlife Research Area	D.H.M. Cumming, Dept. of National Parks & Wildlife Management, Zimbabwe.
26 months	♀	I ₁		
6 years	♀	M ³		
6 years 6 months	♀	I ₁ + M ³		
6 years 6-8 months	♀	I ₁		
8 years 2 months	♀	I ₁ + M ³		
8 years 4-7 months	♂	I ₁ + M ³		

I₁ = mandibular first permanent incisor
M³ = maxillary third permanent molar

Eye lens mass

To assess the possible value of eye lens mass as an index of age, the eyes of 289 warthogs were removed intact soon after death and stored in 10% formalin, after first incising the sclera to facilitate fixation of the lenses. Undamaged lenses were later removed and dried at 80 °C in a forced-draught

oven for 12 weeks until a constant mass had been attained. Lenses were removed from the oven in batches of four to minimise post-drying mass increases, and measured to the nearest 0,1 mg.

Age estimation in the field

A technique for estimating age of free-ranging warthogs is essential for the assessment of population parameters. Since farrowing in Zululand is seasonal and largely concentrated within a period of about eight weeks (Mason 1982), the age difference between warthogs from any two consecutive year classes is usually within the range of 10-14 months. Warthogs in their first and second years of life can easily be distinguished on the basis of relative body size and development of the tusks and warts. Tusk length may be used to differentiate individuals at the beginning of the 2-3 year age interval *vis-à-vis* the 3-4 year class, but subsequently becomes increasingly unreliable, especially in females.

Piglets from sounders for which the month of birth was known and where the mother was individually identifiable were photographed at intervals to record body, tusk and wart development for both sexes up to two years of age (using the size of the adult female as standard). Since resightings of these free-ranging warthogs were unpredictable, the photographic series involved somewhat irregular intervals. Representative measurements for individuals photographed in any month were available from cropped specimens of the same or similar age, which could be estimated to within about two months by backdating to an approximate mean farrowing date (1 November).

The photographs depict those age classes easily recognisable in the field, with the emphasis on relative body size and tusk development, and in view of the seasonality of warthog reproduction in southern Africa, should also be applicable to other populations in this region.

Results

• Dentition

Based on a sample of 29 warthog skulls with deciduous dentition, the dental formula was:

$$2 \left(i \frac{1}{2 \text{ or } 3} c \frac{1}{1} pm \frac{3}{2} \right) = 20-22 \text{ deciduous teeth.}$$

Deciduous lower incisors most commonly numbered six (48,3% of sample), or four (37,9%), with five teeth recorded in only four specimens (13,8%).

The most common permanent tooth formula was:

$$2 \left(I \frac{1}{2 \text{ or } 3} C \frac{1}{1} PM \frac{2}{1} M \frac{3}{3} \right) = 28-30 \text{ permanent teeth.}$$

Occasionally there may be one or three permanent upper premolars in each side of the mouth (Table 2). In two out of 389 cropped specimens, an extra permanent lower premolar (PM₃) was present on one side of the mandible, and was a slender, peg-like tooth with a tapered crown. Total permanent

teeth recorded in Zululand warthogs ranged from a minimum of 26 to a maximum of 32. In addition to this variability, loss of incisors, premolars and first and second molars occurs with age.

Table 2
Variations in the numbers of permanent premolars of Zululand warthogs

n	% of total	Maxilla				Mandible			
		PM ¹	PM ²	PM ³	PM ⁴	PM ₁	PM ₂	PM ₃	PM ₄
8	2,1		x	x	x				x
3	0,8		½	x	x				x
360	92,5			x	x				x
2	0,5			x	x			½	x
3	0,8			½	x				x
13	3,3				x				x

389

x = teeth present on both sides

½ = teeth present on one side only

Tooth replacement, eruption and wear

Both upper and lower deciduous canines had erupted above the gumline in six piglets less than one month old. Examination of a found skull representing a probable age at death of between one and three months showed that the tips of the most anterior cones of the mandibular first molars (M₁) had just started to wear, but eruption of the maxillary first molars (M¹) was less advanced.

Replacement of deciduous teeth commences with the canines which are exchanged while M₁ is erupting. The youngest specimen in which eruption of the permanent canines had started was a juvenile female estimated to be 5-6 months of age and with over half of the full crown length of both M₁ and M¹ in wear. The deciduous canines are shed before the age of one year but may still be present alongside the permanent replacements until about 9-10 months of age. M₂ and M² commenced eruption and wear between nine and eleven months of age (n = 12).

In no instances were the deciduous incisors and premolars replaced during the first year, although the tips of the permanent incisors may start emerging beyond the alveolar margins from about 9-10 months of age. Eruption of I₁ is usually slightly in advance of the other permanent lower incisors, but one or both third deciduous incisors are sometimes never replaced. Of 275 warthogs aged two or more years, *i.e.* with no permanent teeth unerupted, 156 (56,7%) had six lower incisors, 68 (24,7%) four, and 51 (18,5%) five. In 29 of the latter the extra tooth was on the right side. However, some third deciduous incisors that are not replaced could possibly persist beyond two years of age and be mistaken as permanent teeth, so that the number of permanent lower incisors might have been slightly overestimated. Excluding

subadults (2-3 years) from the sample, 97 (55,1%) out of 176 warthogs aged three or more years had six lower incisors, 47 (26,7%) four, and 32 (18,2%) five.

All permanent incisors were fully erupted by about 16 to 20 months of age, with eruption commencing at an approximate average age of 12 months. Replacement of deciduous premolars in the lower jaw tends to slightly precede that in the upper jaw, but PM₁ is not normally replaced (Table 2). The observed age range at commencement of eruption of the permanent premolars was about 12 to 14 months, with PM₄ usually the last to complete eruption. The permanent premolars generally erupt under the deciduous teeth, fragmenting their already worn crowns and leaving chips which tend to persist in the gum, occasionally beyond 24 months of age. In the specimens examined, eruption of permanent premolars was complete by about 20-22 months.

The molars erupt in regular succession from first to third in both maxilla and mandible, with eruption of corresponding teeth tending to commence slightly earlier in the lower jaw. Between about 17 and 20 months of age the third mandibular molar (M₃) starts erupting beyond the alveolar margin, and increase in the length of erupted crown in wear continues into the 3-4 year age class (Fig. 1). The continuous attrition of the premolars and first two molars and the shallowing of their sockets results in a pattern of tooth shedding which, in respect of the molar teeth, resembles the sequence described by Laws(1966) in the African elephant, where "successive teeth grow forwards from the back of the jaw replacing earlier teeth as these wear, move forward, and drop out". However, the warthog has only three molar teeth in each side of each jaw, compared with six in the elephant.

Besides being the most characteristic of warthog teeth, the third and last molar is one of the most peculiar and complex teeth in the whole class of Mammalia (Middleton Shaw 1939). Compared with the other two molars, it is also a very large tooth since, as Spinage & Jolly (1974) point out, "it bears most of the work load from middle-age or earlier". In Zululand warthogs, the third molars may exceed 65 mm in mesio-distal length at the triturating surface, with a similar maximum vertical height, while the widest part of the crown may attain 16 mm. Where eruption and growth are complete, there is a tendency for the lower molars to slightly exceed the upper molars in mesio-distal crown length, but such difference seldom exceeds 5 mm.

The complex arrangement of dental tissues in warthog third molars is best seen on the triturating surface (Fig. 2, Plate 1a), which presents three rows of enamel-rimmed islands of dentine along most of its length. These islands are the abraded ends of long, slender columns of dentine, encased by thick enamel. The enamel in turn is covered by cementum which packs the multitude of columns together, fills the interspaces between them and invests the exterior of the entire tooth, extending above the gum line almost to the level of the occlusal surface. Being softer, the dentine and cementum wear away faster than the enamel, leaving ridges of enamel which render the occlusal surface rough and eminently suitable for shredding and grinding mineral-containing grasses and fibrous material.

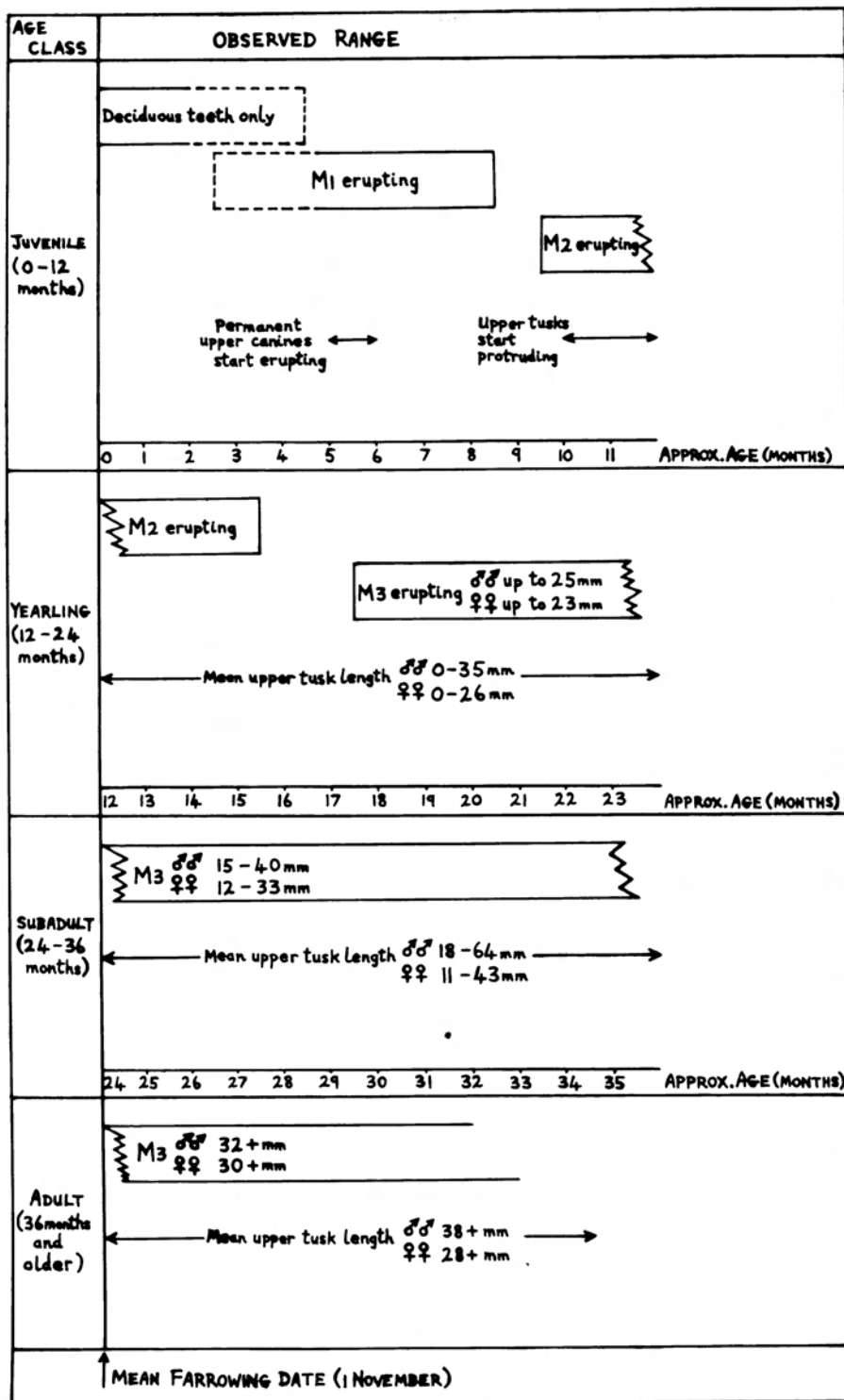


Fig.1. Age estimation criteria for Zululand warthogs based on replacement and eruption of the dentition and growth of the third molars and upper canines.

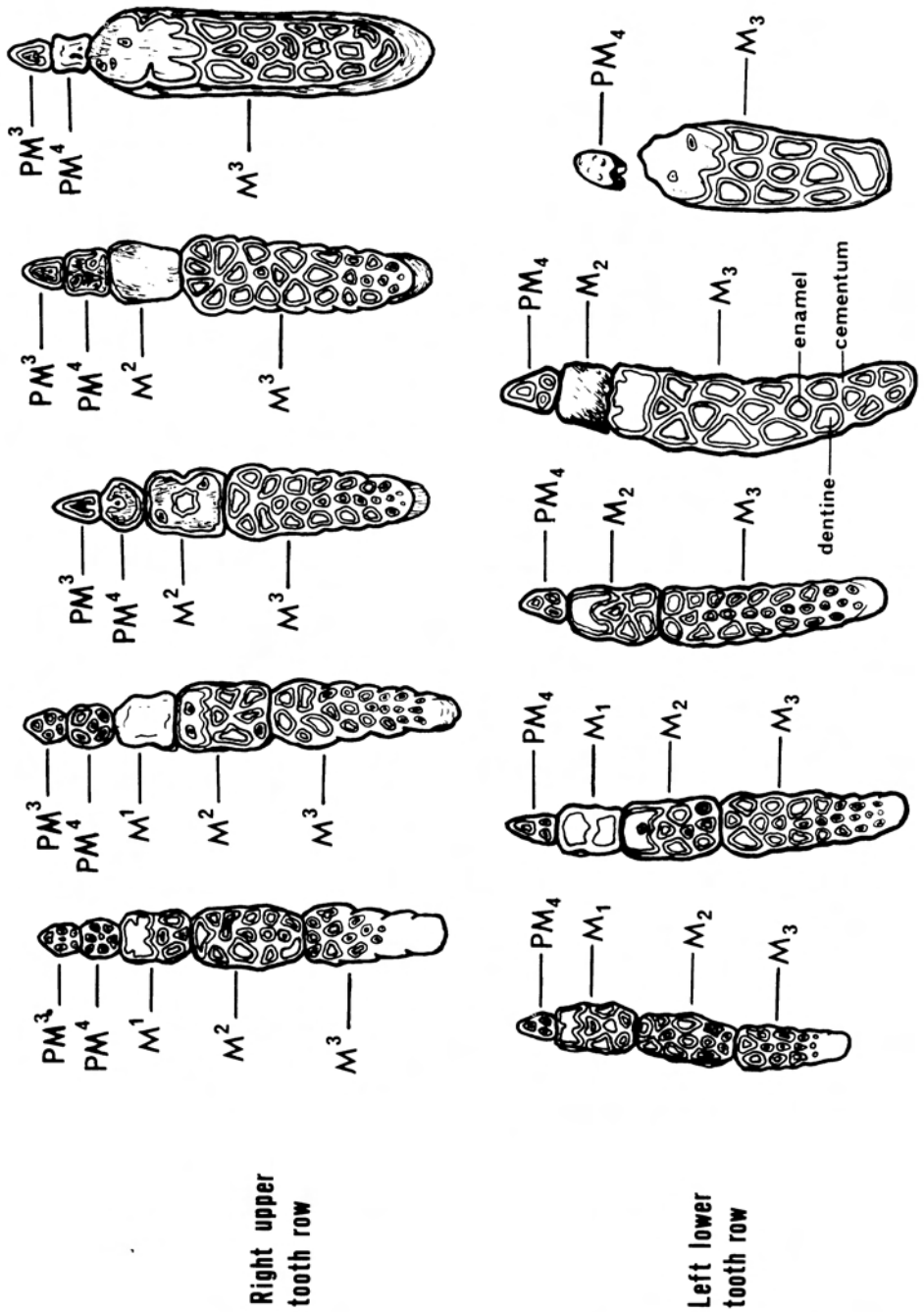


Fig. 2. Molariform teeth rows of the warthog showing the typical sequence of attrition (illustrated in five successive stages from left to right) (Adapted from Guiraud 1948).

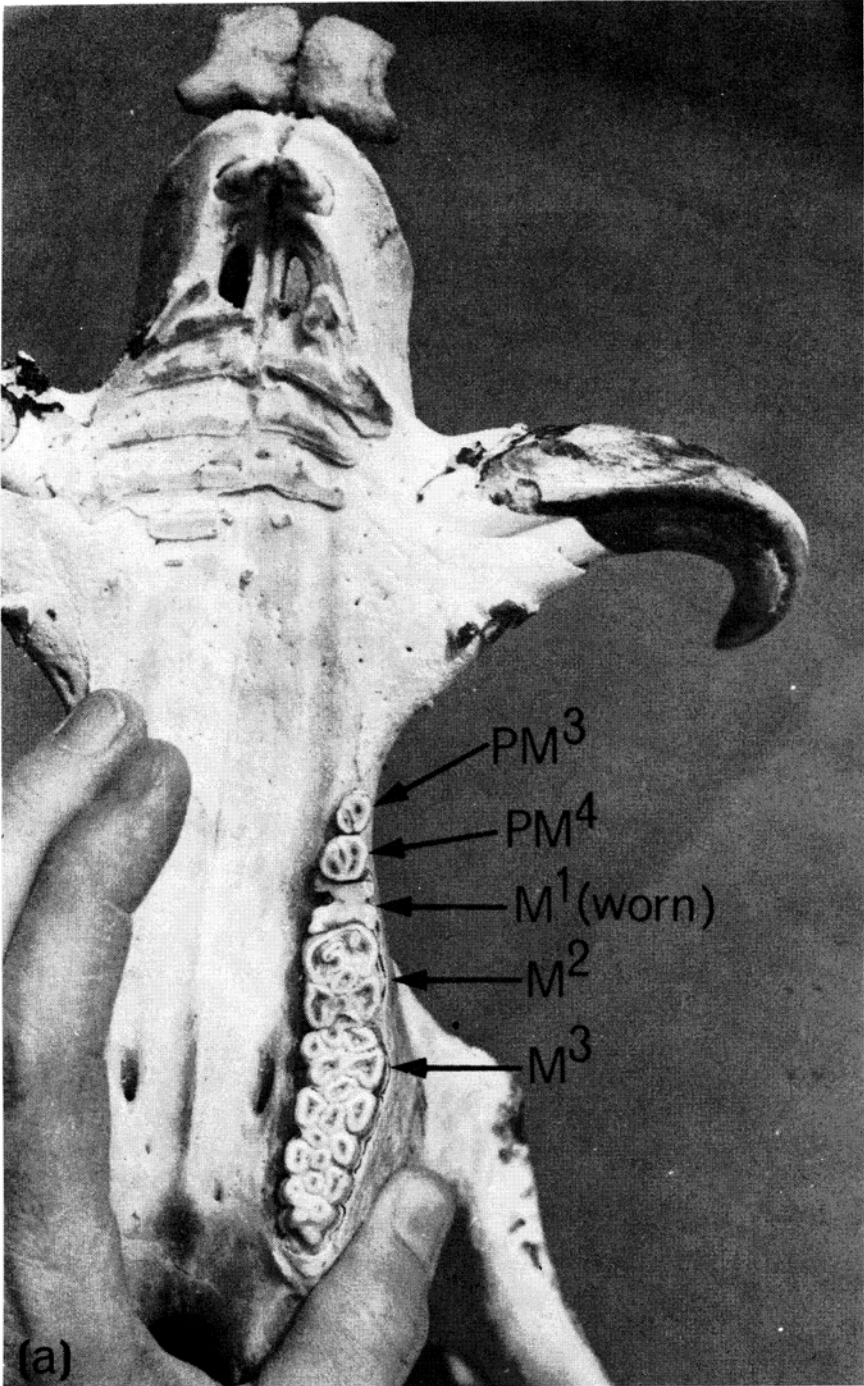


Plate 1

(a) Left upper tooth row of a 3-4 year old warthog sow from Zululand. The tips of the most posterior dentine-enamel columns of the third molar have just started to wear.

The dentine-enamel columns are originally open at their bases, where they grow from "semi-persistent" pulps (Middleton Shaw 1939), and in young juveniles with unerupted molars comprise separate cones, not yet fused together by cementum. With advancing age, additional layers of dentine (formed by the odontoblast cells of the pulpal surface) encroach on and progressively occlude the pulp cavity of each column, commencing at the anterior end of the tooth. Roots develop on the bases of the columns concurrently with the enclosure of their pulp cavities.

In third molars where all the columns have erupted and are represented by separate islands on the triturating surface, the number of columns averages 21 or 22, but tends to be variable, and up to 29 have been recorded in a single tooth. Moreover, the columns and their occlusal islands vary in size and shape in different teeth of corresponding age, in different parts of the same tooth, and particularly in teeth of different ages. Eruption progresses sequentially from the mesial towards the distal end of each molar, so that the tips of the most distal columns are last to reach the level of the masticatory surface. Thus the entire lateral profile of the tooth changes as eruption proceeds (Plate 1b), while the form of the occlusal surface varies concomitantly with the prolonged attrition to which it is subject.

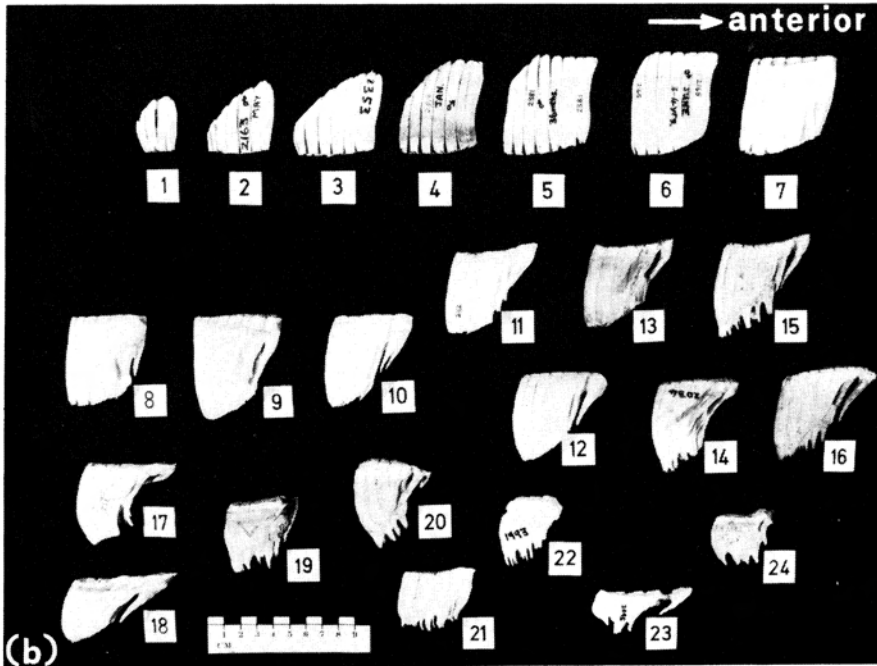


Plate 1

- (b) Lateral profiles of maxillary third molar teeth of Zululand warthogs showing typical sequence of changes in size and shape with growth, occlusion of the pulp cavities, and attrition. Age classes and approximate chronological ages for the series are (1) juvenile (M^3 unerupted); (2) yearling (M^3 erupting); (3) ca. 24 months (most anterior dentine-enamel columns of M^3 erupted to level of triturating surface); (4) subadult (2-3 years); (5) adult (ca. 36 months); (6) 3-4 years; (7) ca. 48 months; (8-10) ca. 5-7 years; (11-18) ca. 8-10 years; (19-24) ca. 10-15 years.

With increasing age, adjoining columns coalesce and lose their separate identities, resulting in a smaller number of columns in the tooth, but with more complex cross-section. Since cementum deposition by the cemento-blast cells of the surrounding periodontal membrane continues through most of life (Spinage 1973), the outer envelope of cementum progressively thickens, and the originally corrugated sides of the tooth become smooth and flat, obscuring the former existence of separate columns.

When attrition of the tips of the columns commences, the resultant dentine-enamel islands on the occlusal surface are small and round. As attrition proceeds and exposes wider portions of each column, the islands increase in size and many assume an oval, triangular or irregular form. Once the tooth has worn down to a level where fusion of adjoining columns is exposed, the occlusal islands display further complexity in form and further increase in size. The anterior group of columns is normally first to coalesce, resulting in one major occlusal island of complex shape, termed the "anterior complex" (Middleton Shaw 1939), which may extend mesio-distally up to half the length of the occlusal surface. Although their pattern alters, enamel rims persist on the occlusal islands even when the crown has worn down close to the roots of the tooth in very old warthogs.

Before eruption of the most posterior columns is completed on the occlusal surface, enclosure of the pulps and development of roots commence with the anterior columns, and with subsequent ageing progresses towards the distal end of the tooth. Forming roots first become apparent usually within a few months of an approximate average age of 36 months. The anterior columns develop a more oblique forwards orientation as root development proceeds, reflecting their earlier cessation of growth relative to continued growth at the back of the tooth, where the pulp cavities remain open longer. As the constricting sockets of the columns develop into roots, while wear of the occlusal surface continues, the height of the columns shrinks concomitantly, and this is most marked in the case of the anterior group of columns. Eventually all the pulps become enclosed, but the anterior roots are normally markedly longer than the remaining roots.

In old warthogs the anterior end of the tooth may be entirely worn away, thus reducing its mesio-distal length. The vertical height between crown and root bases at the anterior ends of the third molars becomes greatly reduced with age, and in some teeth a split was visible where the anterior complex island would shortly separate from the rest of the crown (Plate 1c & d). Examination of four known-age third molars from Zimbabwe (Plate 1 e) indicated that enclosure of all the sockets which lodged the complex pulp matrix was completed at about eight years of age. Judging by the same specimens, splitting off of the anterior complex could commence from about 9-10 years of age, unless wear is unusually heavy and assuming comparable rates of wear in Zimbabwe and Zululand. The tremendous variation in shape and size of warthog third molars with growth and attrition is illustrated in Plate 1b, where a series of teeth has been arranged in an approximate sequence of increasing age, starting with the unerupted tooth of a young individual.

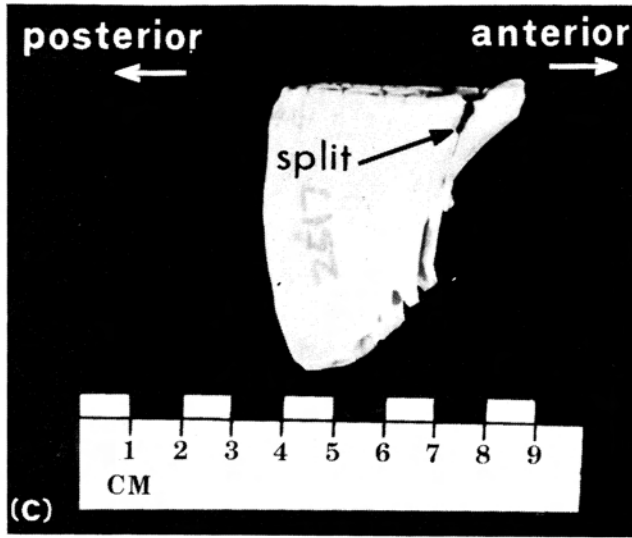


Plate 1

(c) Split at anterior end of the right mandibular third molar of a male warthog (estimated to be about 9-10 years of age) from Zululand.

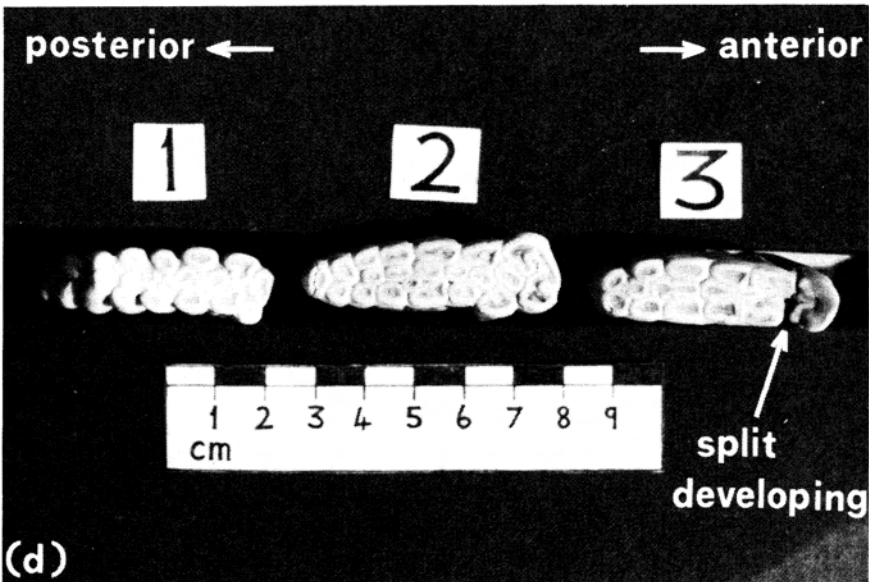


Plate 1

(d) Occlusal surfaces of warthog third molars from Zululand showing wear patterns in relation to age: (1) ca. 36 months; (2) ca. 6-7 years; (3) ca. 9-10 years and with loss of anterior end of tooth imminent.

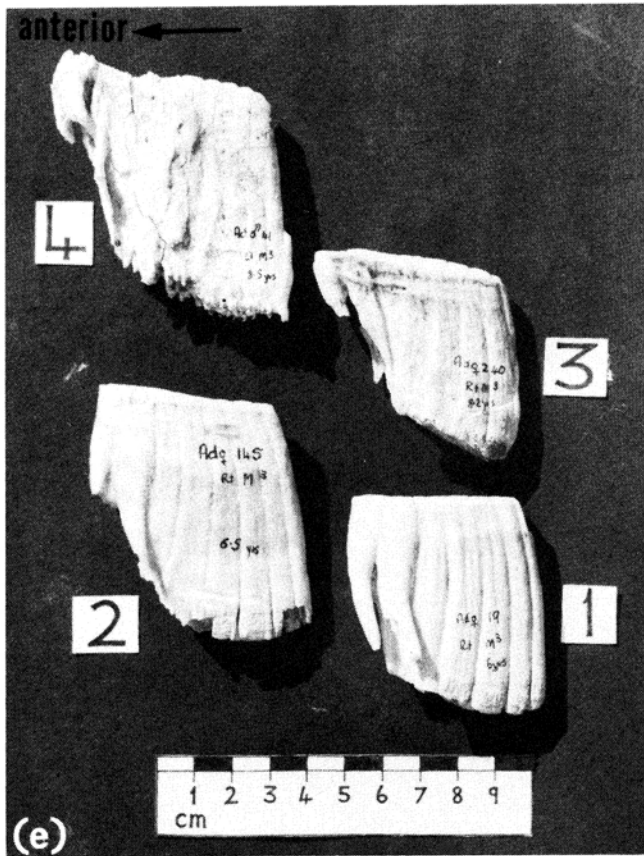


Plate 1

(e) Maxillary third molars of Zimbabwean warthogs of known age: (1) female aged 6,0 years; (2) female aged 6,5 years; (3) female aged 8,2 years; (4) male aged 8,5 years.

In both sexes, the third molars have virtually attained their asymptotic size by four years of age. Examination of sex-specific differences in size of these teeth was therefore restricted to warthogs estimated to be within the 4-5 years age class. For a sample of 21 right maxillary molars (M^3), the mean mesio-distal crown length for males ($\bar{x} = 46,0$ mm, $n = 11$) was significantly greater ($P < 0,001$) than for females ($\bar{x} = 41,9$ mm, $n = 10$) while the maximum labio-lingual crown width was on average 1,3 mm greater in males than in females ($\bar{x} = 14,6$ mm c.f. 13,3 mm) and this difference was significant ($P < 0,01$).

Successive stages of attrition in the upper and lower tooth rows of the warthog have been illustrated by Guiraud (1948) and were found eminently suitable for describing age-related changes observed in the masticatory teeth of Zululand warthogs (Fig. 2). As posterior columns erupt and lengthen the crowns of the third molars, the anterior ends of these teeth initially exert

pressure on the second molars via a restricted zone of contact approximately at the level of the gum line. The continuing forward traverse of the actively growing third molars then compresses both the second and first molars against the fixed premolars at the anterior ends of the tooth rows. Simultaneously, closure of the pulp sockets and wearing down of the crowns of the first and second molars proceeds, and the triturating surfaces are eventually reduced to smooth slabs of dentine and cementum without enamel rims. Sloughing of these worn slabs then ensues, often facilitated by their splitting and fragmentation.

Attrition and shedding of the first molars precedes that of the larger second molars, and is usually completed during the 3-4 years age interval, but shrinking remnant chips may persist into the next year class or even beyond. Judging by the degree of closure of the pulp cavities of the corresponding third molars and estimates of age from cementum lines in the mandibular first permanent incisors, the second molars were not shed before 6-7 years of age and most commonly endured until about 7-8 years, but there appears to be considerable variation in their maximum longevity. Since wear of the first and second molars is usually slightly more advanced in the mandible than in the maxilla, the loss of these teeth tends to occur slightly earlier in the mandible. Although subject to inaccuracies, counts of incisor cementum annulations suggested about nine to 10 years as the probable age up to which very worn upper second molars or fragments thereof may still be present.

The shedding of the worn first molars in particular is promoted by forward pressure from the third molars, the crowns of which usually still increase in length during the 3-4 years age interval. Following loss of the first molars, the forward traverse of the third molars may continue for a time, perhaps aided by their angular shape and oblique vertical orientation in the alveolar sockets, but the force that they exert on the second molars probably declines. Since mastication in the warthog is achieved by a sideways grinding action of the lower teeth against the upper, the greater amplitude for lateral movement at the front end of the mandible probably expedites attrition of the anterior portions of the tooth rows. Loss of the premolars may largely coincide with disappearance of the second molars or may occur slightly later, with PM^3 usually falling out before PM_1 and PM^4 . The upper fourth premolars tend to endure longest, but are usually shed or vestigial by an estimated age of approximately 10 years. The process continues with the wearing down of the anterior ends of M_3 and M^3 , which are the only grinding teeth remaining in aged warthogs. At the sites where the premolars and anterior two molars were rooted, the already shallow alveolar sockets close up and, apart from the third molars, the only functional teeth still present are the canines (growth of which continues throughout most of life) and the greatly reduced lower incisors.

The smaller upper incisors (2) are normally lost before the lower incisors (4-6), which may be vestigial or worn down practically to the gums by an estimated age of approximately 10-13 years. Loss of the incisors is not obviously detrimental to grass prehension, in which the warthog's resilient lips seem to play a major role. The oldest warthog in which the lower first incisors were still present and just large enough for longitudinal sectioning to

be practicable was a male estimated to be about 14 years old from a count of dark-staining rest lines in the cementum. Root resorption had evidently not decreased the total number of cementum annulations that could be counted. The anterior crown height of the right upper third molar of this individual, measured as the vertical distance between the triturating surface and the apices of the most anterior roots, was 14 mm. Although only 4 mm separated the crown from the posterior base of these roots, the anterior end of the tooth had not yet broken away, and the mesio-distal crown length was 55 mm. Judging by the vertical dimensions, this tooth and the other third molars seemed capable of enduring about two more years of wear, which would indicate a potential maximum lifespan of about 16-17 years for Zululand warthogs. However, age estimation from cementum annulations in incisor teeth is seldom possible in the oldest warthogs, since the incisors are shed or worn to tiny remnants probably before about 13 years in most specimens.

Tusk-length: snout-width ratios

Warthog canines grow from persistent pulps within their central cavities. With advancing age these pulp cavities become progressively occluded from the distal ends towards the bases of the tusks by continued formation of dentine upon the surface of the pulps. Following their eruption during the latter half of the first year after birth, the permanent upper canines then develop at more or less the same rate in both sexes up to about 19-20 months of age. Thereafter, differential growth rates and dimorphism in shape of the upper canines between males and females should be considered in age estimation based on continued tusk growth. The tusks grow longer and thicker and are more widely flared in males than in females.

At about 10 months of age the upper canines are usually still level with the flanges of the upper lips, but start protruding from about 12 months. Consequently, juveniles (less than one year old) do not appear in the age class calculations. Because warthogs in Zululand have a short farrowing season, their population age structure is characterised by discrete cohorts of individuals recruited at intervals of approximately one year. Regression formulae for tusk length: snout width ratios (y) in relation to age in months (x) were calculated separately for males and females in the 12-36 months and 36-60 months age groups. The regression lines and their corresponding 95% confidence intervals are shown in Fig. 3. The age estimates from tusk-length: snout-width ratios were calibrated by reference to tooth replacement, eruption and wear, incisor cementum annulations and physical and reproductive development.

Males exceeded females in their average tusk-length: snout-width ratios for the yearling, subadult and 3-4 year age classes. Ratios for these age classes comprised reasonably distinct groups, but overlap among older animals was apparently unfavourable to a satisfactory separation of year classes. Maximum ratios of 49% and 73% were recorded for males and females respectively.

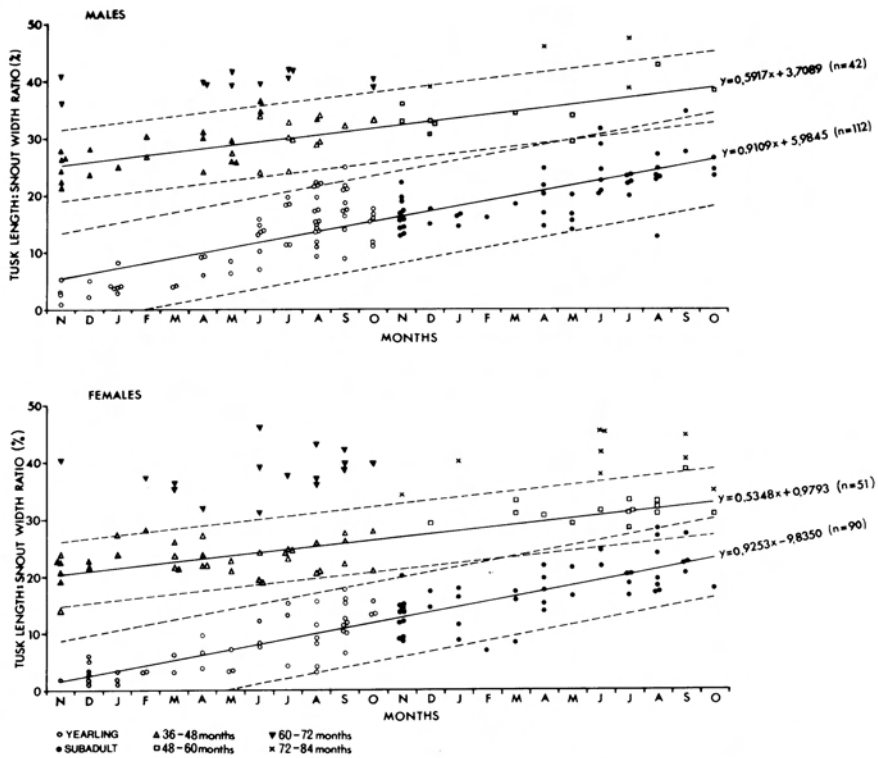


Fig. 3. Regression lines (solid) and their corresponding 95% confidence intervals (broken lines) for the relationship between tusk length: snout width ratios and age for four year-classes of warthogs from Zululand.

Tooth sections

Undecalcified sections

- Incremental layers were not visible in the cementum or dentine of sections from both I_1 and M^3 , even when viewed using anoptical phase contrast.

Decalcified sections

The use of segments of M^3 for sectioning proved unsuitable since the decalcifying fluid dissolved the enamel around each column of dentine, thereby separating the surrounding sheath of cementum which bonds the dentino-enamel columns together. In the decalcified state, this shell of cementum (resembling a honeycomb in cross-section) is rather fragile and tended to collapse or warp during histological processing.

Alternating broad lightly-staining and narrow darkly-staining annulations were found in the cementum covering the external dentine surface of the root portion of I_1 (Plate 2a). However, approximately 33% of stained sections from 181 mandibular first incisors were unsuitable for age estimation,


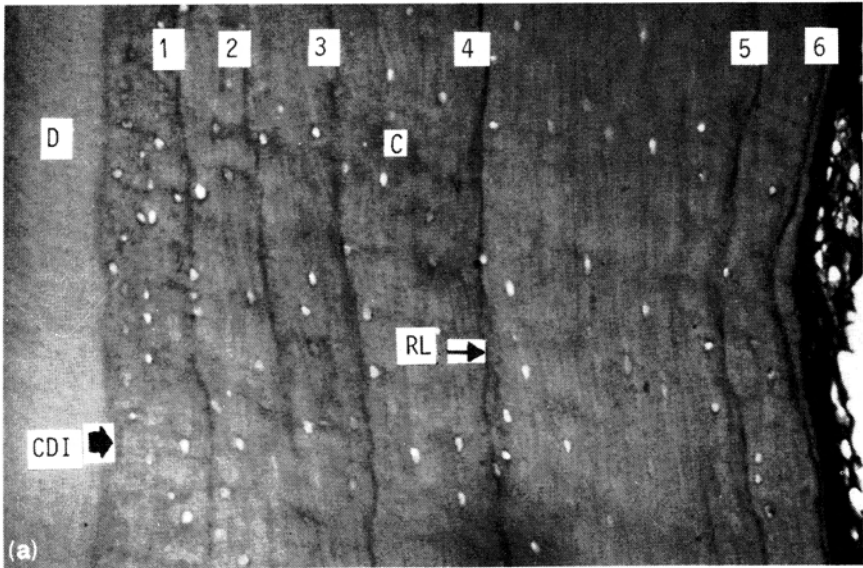


Plate 2

- (a) Decalcified longitudinal section from root of mandibular first permanent incisor of a 6,5-year old female warthog from Zimbabwe showing dentine (D), cemento-dentinal interface (CDI) and cementum (C) with six rest lines (RL) as expected for an annual deposition pattern. 10 μm , haematoxylin and eosin. $\times 160$.
- (b) Decalcified longitudinal section from root of mandibular first permanent incisor of an 8,2-year old female warthog from Zimbabwe showing poor definition of rest lines (RL) in the cementum. At least seven rest lines are nevertheless discernible. 10 μm , haematoxylin and eosin. $\times 160$.

mostly because of poor delineation of rest lines from the interlamellar bands (Plate 2b). The first cementum deposited adjacent to the dentine forms a lightly-staining band, and examination of tooth sections from yearlings indicated that it is laid down during the second summer and autumn of life, when I_1 is erupting. Although I_1 is established by April (corresponding to an estimated age of 17 months using 1 November as the mean farrowing date), the subsequent lamella, represented by a narrow darkly-staining rest line associated with the winter dry season, was apparently not formed on the outer edge of the cementum until about 19-21 months of age. Thereafter, in the incisors of warthogs up to 24 months old, this rest line was visible outside the first incremental band, close to the periodontal membrane.

In most tooth sections from warthogs within the 2-3 years age class, the basic pattern of a wider layer of pale cementum laid down during the wet season followed by a dark-staining rest line during the dry season was continued. Where differentiation of incremental lamellae in older, known-age specimens was satisfactory (Plate 2a), the number of layers was in close agreement with age, thus confirming the annual rhythm of cementum accretion.

The intensity of staining and delineation of rest lines from the background cementum varied greatly between teeth, between sections from the same tooth, and even within the same section. The spacing between successive rest lines is also variable, with lines often merging where the cementum is thinner. Separation of rest lines was usually best for counting on the distal aspect of the root, above the tip. In older warthogs a large terminal deposition of cementum commonly forms at the base of incisor roots, but rest lines here were obscure and unsuitable for counting. As suggested by Leader-Williams (1979) for reindeer (*Rangifer tarandus*), the narrow neck of the incisor root socket of warthogs probably acts as a fulcrum about which the base of the root moves as the tooth crown is subjected to the shearing forces of feeding, and this enlarges the lower part of the socket. Where the socket is thus widened, the deposition of layers of cementum much thicker than in areas of restricted socket width is to be expected.

Variation in the width of cementum layers covering different parts of one tooth between the neck of its socket and the base of the root implied that cementum accretion depends to some extent on the space available in the root socket. Areas of thin cementum are usually associated with discontinuity of certain rest lines, which merge with others and reform further along where the cementum is thicker. Ramifications of rest lines (Plate 3a & b) hindered the correct delineation of the boundaries of broad annual layers, which was further complicated by variable staining quality and artefacts of sectioning. Some rest lines became diffuse or faded completely so that a measure of subjective interpretation and counting was inevitable where lines appeared wavy and were in close proximity.

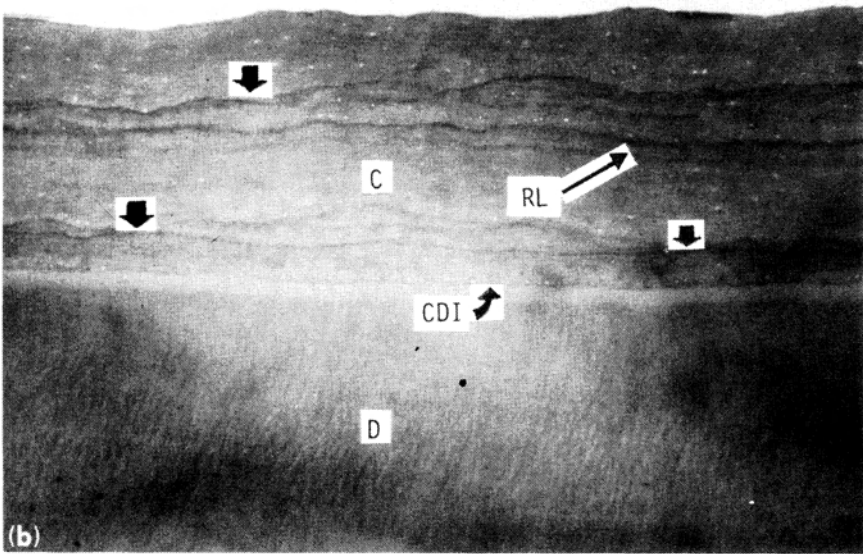
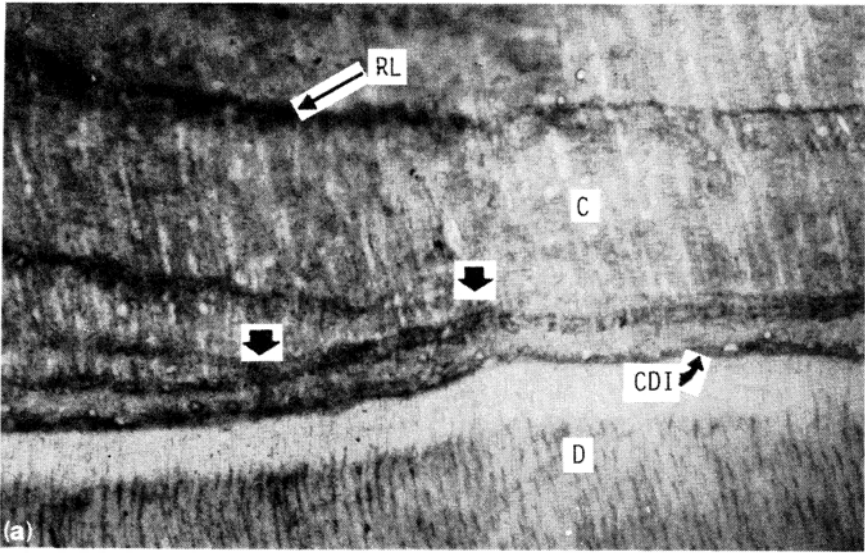


Plate 3.

- (a) Decalcified longitudinal section from root of mandibular first permanent incisor of an adult female warthog from Zululand showing convergence of rest lines (RL) in the cementum (C) at points indicated by vertical arrows. D = dentine, CDI = cemento-dentinal interface. $10\ \mu\text{m}$, Chromotrope 2R. $\times 160$.
- (b) Decalcified longitudinal section from root of mandibular first permanent incisor of a 6.5-year old female warthog from Zimbabwe showing ramifications or rest lines (RL) in the cementum (C). Merging of rest lines at points is indicated by vertical arrows. D = dentine, CDI = cemento-dentinal interface. $10\ \mu\text{m}$, haematoxylin and eosin. $\times 63$.

Dividing and merging rest lines were found in both sexes, and incremental layering seemed to become less distinct with increasing age. Occasionally, the cementum of a section showed a slight tear along a rest line, suggesting that these annulations may be weaker than the intervening bands associated with periods of active growth. Where differentiation of incremental layers in incisor teeth of unknown age was satisfactory for counting, the ages suggested by the numbers of rest lines were in broad agreement with the state of attrition of the dentition. No anomalies, such as young animals with few rest lines but very advanced attrition, were noted. However, in some sections, particularly from older individuals, poor separation of layers associated with merging of rest lines and low contrast staining, probably resulted in the underestimation of the age of a proportion of specimens by one or two years.

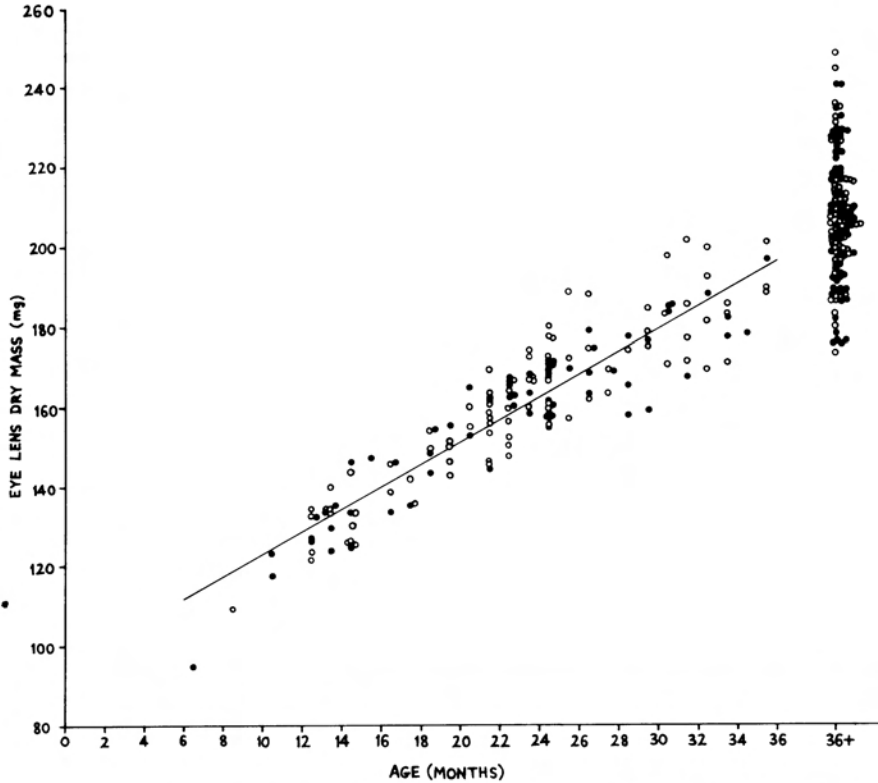


Fig. 4. Relationship of dry eye lens mass to age (as determined from dentition) in juvenile, yearling and subadult warthogs. Males (o), females (●).

Eye lens mass

Mean mass of paired, dried lenses was determined for each warthog, but single lens mass was used whenever one lens had been damaged. A t-test for the difference between paired samples showed no significant difference be-

tween dry mass of left and right lenses. Dry lens mass was plotted against age as determined from stage of tooth replacement and eruption for the first three years of life (Fig. 4). The range of lens mass for adult warthogs (at least 36 months old) is also shown.

Combining both sexes, the graph shows a good correlation between lens mass (y) and age (x) up to 36 months, so a linear regression line given by the equation $y = 94,7337 + 2,8264x$ ($r = 0,915$, $P < 0,001$) was fitted to the data. Between 24 and 36 months of age, ranges of lens mass overlapped increasingly with those of adults. The decline in the rate of increase in lens mass within the subadult age class indicates that this parameter is of little use for separating specimens beyond 36 months.

Age estimation in the field

Because warthogs in Zululand have a short breeding season, the age classification described is based on year classes (separated by at least 9-10 months) which are represented in the population throughout the year. Both sexes attain sexual maturity as yearlings, before physical development is complete, while sexual dimorphism in size is apparent by 24 months of age.

Four age classes were recognised (Plate 4):

1. Juveniles – up to 12 months old
2. Yearlings – 12 to 24 months old
3. Subadults – 24 to 36 months old
4. Adults – older than 36 months.

Piglets of the most recent farrowing season (juveniles) accompany their mother during their first year and are readily distinguished by their small size and generally not visible tusks (Plate 4a, b, &c). Neonates are able to stand under their mother's belly and have a linear shoulder height of only 18-20 cm. However, by 10-12 months of age their average shoulder height is above the halfway level between the elbow and shoulders of the standing adult female, but still approximately 9-14 cm below the apex of her shoulders.

Differences in body size between yearlings of both sexes and adult females are less marked and by June are virtually unnoticeable in the field. Indeed, many yearlings are nearly equal to adult females in body size by the end of March, *i.e.* when about 17 months old. Adult females usually slightly exceed yearlings aged 17-18 months in head plus body length and tend to be heavier in body build, although shoulder heights overlap (Plate 4c). Compared to subadult and adult males, yearling males can generally be distinguished throughout the year by their lighter body build and slightly smaller dimensions, particularly total length.

The limitations of body size for age estimation, especially of solitary individuals and groups of one age class, necessitate recourse to additional criteria. The appearance of the head and tusk size and shape are useful for both age and sex classification in the field. As noted by Ewer (1958), females tend to have less widely flared upper tusks than males. Paired infra-orbital warts situated on the zygomatic arches are present in both sexes, but only protrude 1,5 to 2,5 cm in adult females compared with 6 to 12 cm in adult males.


PLATE 4

Field sex and age classification of warthogs in Zululand.


- (a) Juveniles aged about six to seven weeks with their mother. Warthogs in southern Africa have a short and distinct annual period of parturition and the young born in the most recent season constitute a uniform and easily recognisable group within the population. Note piglet "greeting" mother by nose to nose sniffing.
- (b) Juveniles aged about 11 to 12 months with the matriarch of the sounder. The left tusk of the juvenile in the centre of the photograph is just visible at the lip margin, and the sex of this individual can be distinguished as male by the presence of supra-oral warts.
- (c) Matriarchal sounder comprising an adult sow with juvenile and yearling progeny (left to right: yearling, adult, juvenile, yearling). Young warthogs (especially females) often rejoin their mother after she has farrowed a new litter and may remain with the group at least until they have attained sexual maturity at about 18 months of age.
- (d) Two yearling males and a yearling female (probably littermates) forming a temporary heterosexual association after parting company from a matriarchal sounder. Estimated age about 22 months.
- (e) Yearling females estimated to be about 22 months of age and probably pregnant.
- (f) Primigravid sow aged about 24 months and close to full term of gestation.
- (g) Gravid subadult sow estimated to be about 35 to 36 months of age.
- (h) Yearling males aged about 18 to 19 months and sexually mature.
- (i) Yearling male aged about 19 to 20 months showing development of the tusks and warts.
- (j) Subadult male captured with drive nets and marked with ear tags.
-
- (k) Adult female.
- (l) Adult male.
- (m) Adult male consorting with an adult female during the mating season. Supra-oral warts are absent in the female warthog and the infra-orbital warts are much smaller than those of adult males. Note pre-orbital areas darkened by glandular secretion, particularly in the boar.
- (n) Skull of an old warthog showing long tusks and virtually complete loss of cheek teeth antecedent to the third molars. The left mandibular third molar appears to have shortened through attrition and breaking away of the anterior end. (Found skull from eastern Transvaal in possession of P.C. Viljoen, %Maun Office Services, P.O. Box 448, Maun, Botswana).




(b)



(d)



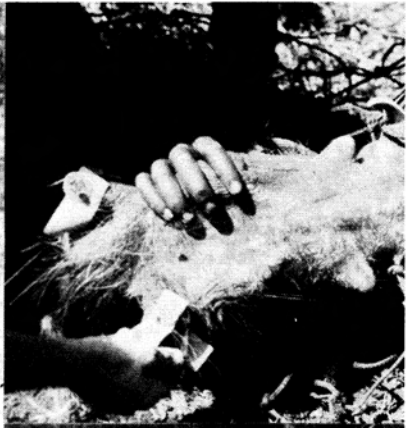(a)




(c)




(g)



(f)



(i)



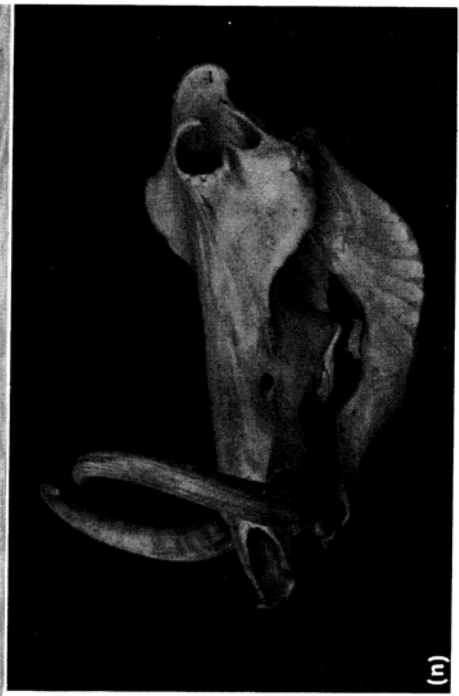
(e)



(h)



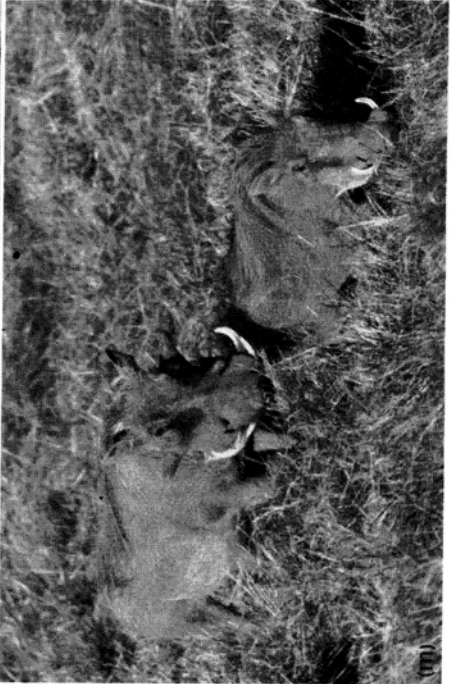(l)



(m)



(k)



(n)

(Photo : R.D.Carr)

Males are further distinguished by a pair of supra-oral warts, which protrude about 3,5 cm in adults (Plate 4k,l and m).

In juveniles and yearlings, the growth of long white hair tufts on the thickened dermal ridges along the ventro-lateral margins of the mandible is more conspicuous than in older warthogs. At the age of 12 months, the tips of the upper tusks have barely started emerging beyond the flanges of the lips, and average 1-3 mm in length for both sexes. By 24 months, tusks of males average about 2-3 cm in length compared with 1,5-2,3 cm in females (measuring tusk length across the arc from the base of the upper tusk, where it protrudes from the lip, to the tip). Yearlings may still be seen with their mother even six or more months after she has farrowed again, which then facilitates comparison of three age classes (juvenile, yearling and adult) alongside (Plate 4c).

Tusk length increases more markedly in males than in females after 24 months of age and by 36 months averages about 4,5 cm in males and 3,0 cm in females. Most 2-3 year old males are distinguishable from those older than 36 months by their tusk development and general physical appearance. Body size is not a valid criterion for recognising subadult from adult females, although the former can generally still be distinguished by their shorter tusks during and for two or three months after the farrowing season. Subsequently however, females in the 2-3 year age cohort become indistinguishable from older year classes due to overlap in their tusk lengths.

Because recognition of subadult females becomes increasingly unreliable after the farrowing season, only three age classes (juveniles, yearlings and animals older than 24 months) can effectively be distinguished in the field throughout the year.

Discussion and conclusions

Dentition

The deciduous dentition formula recorded for warthogs in Zululand corresponded with that reported for 80,6% of specimens examined by Child, Sowls & Mitchell (1965) in Zimbabwe, where some variation in the number of deciduous premolars probably reflects their much larger sample size. In both Zululand and Zimbabwe, full permanent dentition usually comprised 14 teeth in the maxilla and 14 or 16 in the mandible, depending on whether four or six lower incisors were present; however, an inherently variable number of premolars may occur, particularly in the upper jaw, in a minority of specimens.

Although Middleton-Shaw (1939) found that the number of lower incisors in the warthog is subject to variation, differences in the numbers of permanent incisors and premolars were not noted in other early descriptions. Bigourdan (1948) and Guiraud (1948) both recorded the full permanent dentition as comprising 14 maxillary and 16 mandibular teeth, *i.e.* four upper premolars and six lower incisors. Notwithstanding d'Huart's (1971) finding of six upper and four lower permanent premolars in a small collection of warthog skulls from the savanna south of Lake Amin in the Virunga National Park, Zaïre, possible inter-population variation in the average numbers of perma-

nent premolars and lower incisors for warthogs in different geographic regions remains to be demonstrated.

Compared with the bushpig (*Potamochoerus porcus*) and European wild pig (*Sus scrofa*), the warthog shows a marked reduction in the numbers of incisors and premolars and hence in the total number of permanent teeth. Similar reduction in the dental complement has occurred in the giant forest hog (*Hylochoerus meinertzhageni*), for which d'Huart (1978) gives the permanent dental formula as $2 \left(I \frac{1}{3} C \frac{1}{1} PM \frac{2}{1} M \frac{3}{3} \right) = 30$ teeth.

Matschke (1967) recorded the complete permanent dentition of the European wild pig as $2 \left(I \frac{3}{3} C \frac{1}{1} PM \frac{4}{4} M \frac{3}{3} \right) = 44$ teeth.

The permanent dentition of the bushpig has the formula:

$2 \left(I \frac{3}{3} C \frac{1}{1} PM \frac{3 \text{ or } 4}{3 \text{ or } 4} M \frac{3}{3} \right) = 40-44$ teeth; however, the lower first

premolars are commonly absent, so that most bushpigs have a total complement of 42 teeth (Sowls & Phelps 1968).

The elongated, multi-cusped, high-crowned (hypsodont) third molars of the warthog are indicative of adaptation to grinding coarse grass and tough rhizomes. Soil particles are inevitably ingested with rhizomes as these are unearthed by the warthog's snout (mainly during the dry season) and must render the diet rather abrasive. Evolutionary reduction in the number of premolars may well be associated with the gross enlargement of the third molars and contraction of the zone between the third molars and the roots of the canines.

Tooth replacement, eruption and wear

Several studies, notably by Middleton-Shaw (1939), Guiraud (1948) and Child, Sowls & Mitchell (1965), have contributed to describing the basic pattern of tooth replacement, eruption and attrition in the warthog. Child *et al.* (*op. cit.*) described eruption and replacement criteria permitting age determination up to 24 months, whereafter 2-3 year old warthogs could generally be distinguished from older warthogs by the relative growth of their third molars (considering males and females separately due to differential growth rates). Similarly in Zululand, the erupted crown lengths of the third molars were useful for differentiating between yearlings, subadults and warthogs older than 36 months, when their molar measurements were compared within any particular month. Notwithstanding some inherent variation in the number of permanent premolars, tooth replacement and eruption were fairly closely linked with chronological age.

Compared with the enlarged, very hypsodont third molars, the moderately hypsodont second molars, the first molars and the premolars have much lower crowns and are worn down and shed much earlier than the third molars, upon which the warthog then depends for mastication. Wear and loss of the third molars has not been adequately related to age however, and age estimation from incisor cementum annulations was subject to inaccuracies. In Zululand warthogs, loss of the first molars was usually completed

during the 3-4 years age interval, which agrees with the findings of Clough (from Spinage & Jolly 1974) in Uganda. However, the persistence of worn fragments of the first molars in some warthogs estimated to be within the 4-5 and even 5-6 year age cohorts indicates that their maximum durability is rather variable. Possible sex differential rates of attrition of the masticatory teeth were not noted in Zululand and are not mentioned in other studies.

Although the condition of the second molars may be used to indicate relative age (Middleton Shaw 1939), incisor cementum annulations suggested considerable variation in the age span over which they may persist, albeit as worn fragments of variable shape. The minimum age at which the upper and lower second molars were lost was estimated as about 6-7 years, but chips of the upper teeth probably persist up to about 9-10 years in some individuals. While such remnants hardly contribute to mastication, their variable durability renders attrition of the second molars somewhat imprecise as a criterion for estimating age. Examination of the skulls from four Zimbabwean warthogs ranging in age from six to eight years indicated that the second molars were still very much in use at six years of age and were still present in one warthog aged eight years (Cumming *pers. comm.* *).

According to criteria formulated by Clough (from Spinage & Jolly 1974) for Ugandan warthogs, M_2 may be a remnant and M^2 is very worn at an estimated age of 3-4 years, and in the 4-5 years category M^2 is either a small remnant or has been lost. Bigourdan (1948) gives dental formulae of male warthogs in West Africa with estimates of their ages at various stages of sloughing of the cheek teeth antecedent to the third molars, although he does not differentiate between the molars and the premolars. Thus at an estimated age of 10 years, Bigourdan describes the dental formula as $\frac{0-1-2}{2-1-2}$ (16 teeth), but it is uncertain whether the cheek teeth anterior to the third molars are premolars or second molars. Child, Sowls & Mitchell (1965) merely state that the second molars rapidly decrease in length after the third molars attain about 50 mm in crown length, and are subsequently lost, although fragments may persist for a considerable period.

The second molars, which attain 25 mm in crown length and 35 mm in height, are considerably larger than the first molars and so could be expected to endure longer. Complete shedding or advanced loss of the first and second molars at modal ages of about 3-4 years and 7-8 years respectively was indicated for Zululand warthogs. However, attrition may vary with dietary or even genetic factors so that age ranges corresponding to particular stages of wear in Zululand warthogs might differ in other populations. Moreover, the range in longevity of both the first and second molars requires verification from known-age warthogs, possibly by means of tooth impressions taken at intervals from live individuals. Periodic examination of the teeth of captive individuals of known age has been used to establish the tooth replacement pattern in the collared peccary (*Tayassu tajacu*) (Kirkpatrick & Sowls 1962).

In domestic pigs, McCance, Ford & Brown (1961) found that severe and prolonged undernutrition delayed the eruption and development of the per-

*Dr. D.H.M. Cumming, Dept. of National Parks and Wildlife Management, P.O. Box 8365, Causeway, Zimbabwe.

manent teeth, often produced malocclusion in which the mandibular teeth were too far forward for their maxillary opponents, and was associated with crowding, impaction and irregular and extensive wear within the tooth rows. Similar effects that could be attributed to undernutrition were not noted in warthogs during the study period, and malocclusion was only observed where the crowns of particular molar teeth had been fractured, and the opposing teeth were not worn down to the level of the rest of the tooth row. Attwell & Jeffery (1981) found that pronounced differential wear of molari-form teeth between mandible and maxilla was common in eland and wildebeest. Oboussier (1964) has described pronounced differential wear between opposing third molars in an old warthog from Angola. In the molari-form tooth rows of the warthogs examined during the present study, inequalities in wear of opposing teeth were usually minor, which may reflect the proximity of their eruption times in the mandible and maxilla.

With growth and wear, the third molars of warthogs in Zululand showed changes in their shape which corresponded to descriptions by Middleton Shaw (1939) and Guiraud (1948). Spinage & Jolly (1974) attempted to predict age using changes in the morphometry of the third molars. From criteria of tooth eruption and wear, they estimated age of warthogs up to five years and found a linear relationship between age and an index of erupted crown length divided by anterior crown height of the maxillary third molars. They assumed that growth in length and decrease in anterior crown height (wear) of the third molars are linearly related beyond age five, but suggested a curvilinear relationship after 10 years due to growth in crown length approaching its asymptote at this age, while wear continued. In Zululand however, asymptotic crown length of warthog third molars was attained by 4-5 years of age in both sexes, so Spinage & Jolly's prediction formula appears invalid. This is supported by Cumming (*pers. comm.*) who considers that Spinage & Jolly's criteria are not applicable to warthogs in the Sengwa area of Zimbabwe, where their prediction graph gave an estimated age of two years for a six year old individual.

Interpretation of age in terms of the morphometry of the third molars could also be impaired because anterior crown height is an inherently imprecise measurement in older warthogs where this dimension has been greatly reduced following occlusion of the pulp cavities, development of roots, and wear. Spinage & Jolly (1974) imply that anterior crown height is measured from the anterior tip of the occlusal surface to the base of the most anterior dentine column(s), but in older specimens it is not clear whether they used the apex of the most anterior roots or the junction of their bases. The anterior extremity of upper third molars is formed by two marginal columns so that two roots normally develop, more or less alongside, from their bases. Variations occur in the length, slant and relative positions of the most anterior roots, while the anterior ends of some teeth incline lingually, thus disturbing the normal relation of the columns. A further drawback is the difficulty of extracting the third molar teeth without damaging their anterior ends.

Rates of wear of the 4-6 mandibular permanent incisors seemed to be quite variable between individuals with the same stage of attrition of the grinding teeth, and might partly reflect variation in shape and size of the pair of upper

incisors. Although the arrangement of the incisors with their cutting surfaces concentrated towards the tip of the mouth would facilitate selective grass plucking, their loss with advancing age implies that they are not essential, and old warthogs observed in the field showed no apparent difficulty in grazing either short, finely tufted or tall, long leaved grasses.

Tusk-length: snout-width ratios

The regression lines for the Zululand data diverged from those computed by Bradley (1972) for Kenyan warthogs. For both the yearling and subadult age classes, the range in average tusk-length: snout-width ratios of Zululand warthogs was markedly lower than the comparable range computed by Bradley. Although average tusk growth in warthog populations from Kenya and Zululand could differ, Bradley's sample is based largely on females and his measurements of changes in tusk-length and snout-width with age are derived from a total of 69 recurrent photographs of 17 identifiable individuals (15 females, two males). In Zululand however, tusk-length and snout width were measured directly from shot warthogs, and the sexes were treated separately in the data analysis.

Snout-width is considerably less in adult females than in adult males, notwithstanding individual variation such that tusk-length: snout-width ratios of warthogs with the same tusk measurements may differ by over 8% in both sexes. Bradley (1972) recognises further sources of error inherent in his method of age estimation, viz. (i) from about three years of age, inward curving of warthog tusks increases (particularly in females) until the length, measured across the arc, is no longer an accurate measure of growth; (ii) with increase in age, wear at the tusk tips detracts from annual growth; (iii) if both tusk tips break off early in life, age may later be underestimated if the breaks are not easily discernible.

In view of these limitations and the differences between the Zululand and Kenyan data, the possibility of using volume of the tusk pulp as an index of age seems worth investigating.

Tooth sections

Problems of interpretation of the layer structure in dental tissues (e.g. Hall-Martin 1976; Gasaway, Harkness & Rausch 1978; Leader-Williams 1979) are a major source of error in mammalian age estimation using tooth sections. However, as Leader-Williams (*op. cit.*) points out, few accounts dwell at length on these problems or on the accuracy of the results obtained and "many authors may have given the impression of minimal difficulties, particularly when illustrating their papers with easily interpretable sections containing no problem areas." Indeed, dental layer patterns may even be unsuitable for age determination, as found by Catt (1979) using longitudinal and cross-sections through the cementum of molars, premolars and incisors of Bennett's wallaby, *Macropus rufogriseus fruticus*. Phillips, Steinberg & Kunz (1982) critically evaluated age determination in bats using counts of incremental lines in their teeth and concluded that the technique was of "questionable accuracy".

Geographical variation in the pattern of cementum deposition and in the correlation between the number of growth layers and true age may occur within a species, e.g. red deer (Mitchell 1967; Lowe 1967), caribou and reindeer (McEwan 1963; Reimers & Nordby 1968; Miller 1974; Leader-Williams 1979). Although inconsistencies in the pattern of layering in relation to age and season may be attributable to environmental factors, biologists ageing animals have paid little attention to the reasons for the formation of cementum of varying composition (Leader-Williams *op. cit.*).

Another major difficulty is associated with the staining properties of dental cementum, since clarity of rest lines and colour contrast between rest lines and background cementum are frequently poor. This led Thomas (1977) to investigate the relative merits of a variety of stains and consequently advocate the use of metachromatic stains, particularly toluidine blue, after cemental decalcification. There is also some evidence that certain decalcifying solutions may interfere with the staining properties of cementum. Thus for example, Turner (1977) advised against the use of nitric acid for decalcifying the incisors of North American sheep, since it obliterated otherwise distinct annuli.

In the warthog, the difficulty of identifying rest lines is a source of error in age estimation, and counting errors, even of one line, would be more important in younger than in older animals. Inconsistency in the clarity and number of cementum lines throughout the length of the root emphasised the value of longitudinal sections for maximum counts. While the early pattern of cementum deposition could be interpreted in those individuals aged by tooth replacement and eruption, known-age material proved invaluable in confirming that the same annual rhythm was continued in older warthogs. Although stages of tooth wear and loss are associated with broad age classes, cementum line counts, despite their limitations, permit more precise estimation of the age of adult warthogs, especially beyond about nine or 10 years. However, in applying the cementum technique to large samples, processing could probably be streamlined by sectioning decalcified teeth with a cryostat, thus eliminating wax embedding. Indeed, satisfactory sections were cut in this way from a small number of incisors at -30°C .

Low (1970) has described cemental annulations in permanent first incisors of collared peccaries in Texas. Unless poorly defined, counts of these annulations in transverse sections cut from decalcified teeth gave a quite accurate assessment of age, although accuracy probably decreased in individuals over 10 years old. However, in 34% of peccary teeth, interpretation and counting of annuli varied from difficult to almost impossible. The pattern of formation of annulations was essentially one broad band and one narrow, darker band each year, as for more northern ungulates.

No accounts of the use of tooth sections to determine the age of warthogs and bushpigs have apparently been published, but d'Huart (1980) was able to estimate age of giant forest hogs in equatorial Africa from incremental layering in their lower incisor teeth. Using a new technique involving micro-radiography, d'Huart found a biannual pattern of rest lines in the dentine of sectioned incisors. Other studies of African mammals living in equatorial regions where the annual rainfall distribution is bimodal have shown the

same incremental rhythm of two rest lines per year in the dental cementum (Spinage 1967, 1976b; Grimsdell 1973).

Changes in the structural composition of dental tissue that result in a regular annual pattern of incremental layering are generally attributed to nutritional effects, with possible subsidiary influences of an endocrinological nature, associated with reproduction and lactation. In view of evidence that rest lines in cementum or dentine represent zones of retarded growth and disturbance in the calcification rhythm (Klevezal' & Kleinenberg 1969; Steenkamp 1975), and in African herbivores are apparently formed during dry seasons (Spinage 1967; Simpson & Elder 1969; Rautenbach 1971; Grimsdell 1973; Spinage 1976a; Hall-Martin 1976), the occurrence of one or two rest lines per year may well be related to unimodal or bimodal nutritional depressions, reflecting the annual rainfall regime. In Zululand, the results of warthog cementum line counts showed one rest line per year, and judging by specimens where a new rest line had apparently just been formed, these lines are laid down during the dry season.

By contrast, studies of animals living in oceanic environments have shown that the formation of alternating layers of different types of cementum is rather irregular, causing inaccuracies in age estimation (Lowe 1967; Leader-Williams 1979). In an introduced herd of reindeer on a subantarctic island, Leader-Williams (*op. cit.*) found that rest line formation in incisor cementum was frequently aberrant with respect to season, and he suggested that variations in the space available for cementum accretion were responsible for further inconsistencies in the deposition of cementum according to the pattern expected with age and season; separation between rest lines was evidently related to cementum thickness and varied between parts of one tooth, so that there were areas of discontinuity (merging and reforming of certain rest lines) and areas of minimal or even nil-separation. Thus the variable cementum thickness and rest line separation apparent within particular warthog incisors may reflect variations in the dimensions of their alveolar sockets, which could be influenced by root movement due to chewing.

However, apart from Spinage (1976a), Leader-Williams (1979) and Phillips *et al.* (1982), the probably important influence of tooth movement and functional stress on variation in thickness of sequential layers laid down in any one tooth or between parts of one tooth has apparently not been generally recognised in age estimation studies based on the evaluation of tooth sections. In commenting on the differential spacing between rest lines in the molar cementum pad of a known-age black rhinoceros, *Diceros bicornis*, Spinage (*op. cit.*) suggested that alveolar and mesial shift of the tooth with increasing age may have been the causal factor initiating a change in the rate of accretion of interlamellar cementum, which did not correlate with a bi-phasic pattern in average annual rainfall during the animal's life. Phillips *et al.* (*op. cit.*) found that incremental lines in bat teeth were most obvious and numerous in localised areas of thickened cementum associated with dental drift.

Although physiological factors underlying the formation of cementum of varying composition remain inadequately explained (Leader-Williams 1979), most studies indicate that the relationship of cementum layering to

age is usually sound in herbivores subject to consistent seasonal differences in nutrition. Nevertheless, incremental layering in warthog and other mammalian teeth should be evaluated with caution, recognising that the deposition of successive layers is subject to irregularities, and allowing for a degree of subjectivity in the interpretation of lamellae. As applied to warthog teeth, the technique could probably be improved considerably by using stains superior to haematoxylin (see Thomas 1977) for delineation of rest lines.

Longevity

A tame female warthog at the Mliwane Wildlife Sanctuary, Swaziland, died at the age of 12 years (Reilly *pers. comm.*‡). Of three female warthogs captured when young in the Sudan and kept in the Giza Zoological Gardens, Egypt, two lived for 13,5 years and one for 16,5 years (Flower 1931). Crandall (1974) cites records for two warthogs received at American zoological gardens and surviving for 15,2 and 16,9 years respectively.

Based on age estimates from incremental layering in incisor cementum and the degree of wear of the last (third) molar teeth, the maximum lifespan of warthogs in Zululand is probably about 17 years. This corresponds with longevity records for warthogs in captivity, although it seems likely that maximum ages would be realised less frequently in the wild.

Eye lens mass

Although lens mass of Zululand warthogs permitted reasonable separation of the first two year classes and confirmed other age criteria, subsequent overlap in lens mass prevented reliable differentiation of age classes. Similar findings have been reported for warthogs in Zimbabwe, where specimens in the 2-3 year age interval already overlapped considerably with older individuals in their lens mass (Child, Sowls & Richardson 1965). The use of the lens technique to separate the first two year classes cannot be recommended however, since dental criteria provide an easier method. In collared peccaries, Low (1970) found that the regression relationship between eye lens mass and age was unreliable for age prediction beyond 24 months, even though lens mass continued to increase.

While regional differences in eye lens growth patterns of warthogs from Zululand and Zimbabwe were not apparent, it should nevertheless be recognised that lens mass/age relationships may be influenced by stress (Myers & Gilbert 1968) and nutrition (Friend & Severinghaus 1967; Morris 1972).

Age estimation in the field

Geigy (1955) gives photographs of two-year old male and female warthogs at a European zoo, regarding which Roth (1965) comments that "the tusks seem to be even less developed" than those of similar-aged warthogs in Zimbabwe, where they protruded about 3,0-4,5 cm from the lip at 20-21 months. Roth based his observation on two captive warthogs (male and female) for which the measurements apparently refer to tusk-length along

‡Mr. T.E. Reilly, Mliwane Wildlife Sanctuary, P.O. Box 33, Mbabane, Swaziland.

the outside curve. The known-age warthogs in Geigy's article were captured in Mali and Kenya and in the subsequent photographs their tusk-lengths indeed appear more typical of warthogs at an early stage of the yearling age class rather than two years old.

Cumming's (1970) illustrations of the first three year classes in a Zimbabwean warthog population, based particularly on tusk development, correspond with the age categories observed in Zululand, but this does not eliminate the possibility of some geographic variation in average tusk growth and wear. In using body size as an age criterion, the occurrence of runts within some litters should be recognised, and Roth (1965) and Cumming (1970) have noted that growth is sensitive to the plane of nutrition. Both authors found that young warthogs which as a consequence of rearing conditions were virtually as large as adults, could nevertheless still be distinguished by their smaller tusks. Although tusk size apparently remains typical for at least the yearling age class, Cumming (*op. cit.*) suggests that wart growth may be variable in males, since warts were much larger in tame individuals whose diet had been supplemented than in wild warthogs of comparable age.

Experience in Zululand supported Cumming's (1970, 1975) finding that subadult females cannot be reliably distinguished throughout the year, so that field classification must be based on three age classes of warthogs – juveniles, yearlings and animals older than 24 months. Very old warthogs, *i.e.* individuals using their last molars, are usually distinctive by virtue of their long upper tusks (Plate 4n), the tips of which may curve downwards towards the snout, particularly in females. Unless wear at the tusk tips exceeds annual growth, increase in tusk length probably continues for most of a warthog's potential lifespan, judging by old individuals in which occlusion of the pulp cavities was very advanced. Spinage & Jolly (1974) concluded that increase in length of the upper tusks, measured along the outer curve, appeared to approach an asymptote at an estimated age of about 10 years, although increase in mass continued until senescence. However, their analysis makes no allowance for sexual dimorphism in tusk growth and shape.

According to Rowland Ward's records of African game (Best & Best 1977), upper tusks of 38-43 cm in total length (measured along the outside curve as for elephant tusks) are not very uncommon; the world record warthog upper tusk (locality of collection unknown) measures 60,96 cm in total length along the outside curve, compared with 56,20 cm for the second longest recorded specimen (from Uganda). In 1965, Smithers (*pers. comm.**) measured an upper tusk of a warthog from Goromonzi in the Harare district, Zimbabwe, with a total length along the outside curve of 49,85 cm, of which 43,50 cm protruded beyond the gum line.

Acknowledgements

This paper was part of a doctoral study supervised by Prof. J.D. Skinner and Dr. D.R.M. Stewart during the course of which I was the recipient of bursaries from the Council for Scientific and Industrial Research, the Natal Parks

*Dr. R.H.N. Smithers, Transvaal Museum, P.O. Box 413, Pretoria 0001, S. Africa.

Board and the Charles Astley Maberly Scholarship of the Transvaal Branch of the Wildlife Society of southern Africa. My best thanks go to Mrs. G. McCullough for her assistance with sectioning and staining teeth. I thank Dr. J.C. Austin, Dr. P. Cleaton-Jones, Dr. K. Swanevelder and Mr. J. Nell for advice on laboratory technology. Dr. D.H.M. Cumming kindly contributed known-age warthog teeth from Zimbabwe. During fieldwork I greatly valued the friendship, hospitality, assistance and advice of numerous Natal Park Board officers and their wives. I am grateful to Dr. A.J. Hall-Martin, Dr. R.N. Owen-Smith, my parents and Carolyn for their encouragement.

REFERENCES

- ATTWELL, C.A.M. 1980. Age determination of the blue wildebeest *Connochaetes taurinus* in Zululand. *S. Afr. J. Zool.* 15: 121-130.
- ATTWELL, C.A.M. and R.C.V. JEFFERY. 1981. Aspects of molariform tooth attrition in eland and wildebeest. *S. Afr. J. Wildl. Res.* 11: 31-34.
- BEST, A.A. and T.G.W. BEST (Eds). 1977. *Rowland Ward's records of big game*. 17th edn. (Africa). Rowland Ward, Newbridge Mill, England.
- BIGOURDAN, J. 1948. Le phacochère et les suides dans l'ouest Africain. *Bul. Inst. Fr. Afr. Noir, Dakar.* 10: 285-360.
- BRADLEY, R.M. 1968. *Some aspects of the ecology of the warthog (Phacochoerus aethiopicus Pallas) in Nairobi National Park*. M.Sc. thesis, University of East Africa, Nairobi.
- BRADLEY, R. 1972. A photographic ageing technique used on warthog. *E. Afr. Wildl. J.* 10: 123-128.
- CATT, D.C. 1979. Age determination in Bennett's wallaby, *Macropus rufogriseus fruticus* (Marsupialia), in South Canterbury, New Zealand. *Aust. Wildl. Res.* 6: 13-18.
- COOKE, H.B.S. and A.F. WILKINSON. 1978. Suidae and Tayassuidae. In: MAGLIO, V.J. and H.B.S. COOKE (Eds). *Evolution of African Mammals*. Cambridge, Massachusetts: Harvard University Press.
- CHILD, G., L. SOWLS and B.L. MITCHELL. 1965. Variations in the dentition, ageing criteria and growth patterns in wart hog. *Arnoldia* 1 (38): 1-23.
- CHILD, G., L. SOWLS and G.L. RICHARDSON. 1965. Use and limitations of eye-lens weight for ageing wart hog. *Arnoldia* 1 (39): 1-2.
- CRANDALL, L.S. 1974. *The management of wild mammals in captivity*. Chicago: University of Chicago Press.
- CUMMING, D.H.M. 1970. *A contribution to the biology of warthog (Phacochoerus africanus, Gmelin) in the Sengwa region of Rhodesia*. D.Phil. thesis, Rhodes University, Grahamstown.
- CUMMING, D.H.M. 1975. A field study of the ecology and behaviour of warthog. *Mus. Mem.* No. 7, Nat. Museums Admin., Harare, Zimbabwe.
- D'HUART, J-P. 1971. Révision et nouvelles recherches sur la biologie du phacochère (*Phacochoerus aethiopicus* Pallas). *Mem. Lic. Sci. Zool.*, Univ. Catholique de Louvain.

- D'HUART, J-P. 1978. Écologie de l'hylochere (*Hylochoerus meinertzhageni* Thomas) au Parc National des Virunga. *Exploration du Parc National des Virunga, Deuxième série, Fascicule 25, Fondation pour Favoriser les Recherches scientifiques en Afrique*. Brussels.
- D'HUART, J-P. 1980. Détermination de l'âge par les anneaux de croissance des tissus dentaires: une nouvelle méthode de préparation sur *Hylochoerus* (Suidae). *Mammalia* 44: 129-136.
- DISBREY, B.D. and J.H. RACK. 1970. *Histological laboratory methods*. Edinburgh: E. & S. Livingstone.
- EWER, R.F. 1958. Adaptive features in the skulls of African Suidae. *Proc. zool. Soc., Lond.* 131: 135-155.
- FLOWER, S.S. 1931. Contributions to our knowledge of the duration of life in vertebrate animals – V. Mammals. *Proc. zool. Soc., Lond.* 101: 145-234.
- FRIEND, M. and C.W. SEVERINGHAUS. 1967. Influence of nutrition on eye-lens weight in deer. *N.Y. Fish Game J.* 14: 166-175.
- GASAWAY, W.C., D.B. HARKNESS and R.A. RAUSCH. 1978. Accuracy of moose age determinations from incisor cementum layers. *J. Wildl. Mgmt.* 42: 558-563.
- GEIGY, R. 1955. Observations sur le phacochère du Tanganyika. *Rev. Suisse de Zoologie* 62: 139-162.
- GRIMSDELL, J.J.R. 1973. Age determination of the African buffalo, *Syn- cerus caffer* Sparrman. *E. Afr. Wildl. J.* 11: 31-53.
- GUIRAUD, M. 1948. Contribution a l'étude du *Phacochoerus aethiopicus* (Pallas). *Mammalia* 12: 54-66.
- HALL-MARTIN, A.J. 1976. Dentition and age determination of the giraffe *Giraffa camelopardalis*. *J. Zool., Lond.* 180: 263-289.
- HITCHINS, P.M. 1978. Age determination of the black rhinoceros (*Diceros bicornis* Linn.) in Zululand. *S. Afr. J. Wildl. Res.* 8: 71-80.
- JEFFERY, R.C.V. and J. HANKS. 1981. Age determination of eland *Taurotragus oryx* (Pallas, 1766) in the Natal highveld. *S. Afr. J. Zool.* 16: 113-122.
- KINGDON, J. 1979. *East African mammals: an atlas of evolution in Africa*. Vol. III B (large mammals). London: Academic Press.
- KIRKPATRICK, R.D. and L.K. SOWLS. 1962. Age determination of the • collared peccary by the tooth-replacement pattern. *J. Wildl. Mgmt.* 26: 214-217.
- KLEVEZAL', G.A. and S.E. KLEINENBERG. 1969. *Age determination of mammals from annual layers in teeth and bones*. (Opredelenie vozrasta mlekopitayuschikh po sloistym strukturam zubov i kosti). Israel Program for Scientific Translations, Jerusalem.
- LAWS, R.M. 1952. A new method of age determination for mammals. *Nature, Lond.* 169: 972-973.
- LAWS, R.M. 1953. A new method of age determination in mammals with special reference to the elephant seal (*Mirounga leonina* L.). *Scient. Rep. Falkld. Isl. Depend. Surv.* 2: 1-11.
- LAWS, R.M. 1966. Age criteria for the African elephant, *Loxodonta a. africana*. *E. Afr. Wildl. J.* 4: 1-37.
- LEADER-WILLIAMS, N. 1979. Age determination of reindeer introduced into South Georgia. *J. Zool., Lond.* 188: 501-515.

- LOW, W.A. 1970. *The influence of aridity on reproduction of the collared peccary (Dicotyles tajacu (Linn.)) in Texas*. Ph.D. thesis, Univ. British Columbia.
- LOWE, V.P.W. 1967. Teeth as indicators of age with special reference to red deer (*Cervus elaphus*) of known age from Rhum. *J. Zool., Lond.* 152: 137-153.
- MASON, D.R. 1982. *Studies on the biology and ecology of the warthog Phacochoerus aethiopicus sundevalli Lönnberg, 1908 in Zululand*. D.Sc. thesis, Univ. Pretoria, Pretoria.
- MATSCHKE, G.E. 1967. Ageing European wild hogs by dentition. *J. Wildl. Mgmt.* 31: 109-113.
- McCANCE, R.A., E.H.R. FORD and W.A.B. BROWN. 1961. Severe undernutrition in growing and adult animals 7. Development of the skull, jaws and teeth in pigs. *Brit. J. Nutr.* 15: 213-223.
- McEWAN, E.H. 1963. Seasonal annuli in the cementum of the teeth of barren-ground caribou. *Can. J. Zool.* 41: 111-113.
- MIDDLETON-SHAW, J.C. 1939. Growth changes and variations in warthog third molars and their palaeontological importance. *Trans. R. Soc. S. Afr.* 27: 51-94.
- MILLER, F.L. 1974. Age determination of caribou by annulations in dental cementum. *J. Wildl. Mgmt.* 38: 47-53.
- MITCHELL, B. 1967. Growth layers in dental cement for determining the age of red deer (*Cervus elaphus* L.). *J. Anim. Ecol.* 36: 279-293.
- MORRIS, P. 1972. A review of mammalian age determination methods. *Mammal Rev.* 2: 69-104.
- MYERS, K. and N. GILBERT. 1968. Determination of age of wild rabbits in Australia. *J. Wildl. Mgmt.* 32: 841-849.
- OBOUSSIER, H. 1964. Ein ungewöhnliches Warzenschwein (*Phacochoerus aethiopicus shorridgei* St. Leger, 1932). *Säugetierk. Mitteil.* 12: 94-97.
- PENZHORN, B.L. 1982. Age determination in Cape mountain zebras *Equus zebra zebra* in the Mountain Zebra National Park. *Koedoe* 25: 89-102.
- PHILLIPS, C.J., B. STEINBERG and T.H. KUNZ. 1982. Dentin, cementum, and age determination in bats: a critical evaluation. *J. Mamm.* 63: 197-207.
- RAUTENBACH, I.L. 1971. Ageing criteria in the springbok *Antidorcas marsupialis* (Zimmermann, 1780) (Artiodactyla: Bovidae). *Ann. Transv. Mus.* 27: 83-133.
- REIMERS, E. and O. NORDBY. 1968. Relationship between age and tooth cementum layers in Norwegian reindeer. *J. Wildl. Mgmt.* 32: 957-961.
- ROTH, H.H. 1965. Observations on growth and ageing of warthog *Phacochoerus aethiopicus* (Pallas, 1766). *Z. Säugetierk.* 30: 367-380.
- SIMPSON, C.D. and W.H. ELDER. 1969. Tooth cementum as an index of age in greater kudu (*Tragelaphus strepsiceros*). *Arnoldia* 4(20): 1-10.
- SMUTS, G.L., J.L. ANDERSON and J.C. AUSTIN. 1978. Age determination of the African lion (*Panthera leo*). *J. Zool., Lond.* 185: 115-146.
- SOWLS, L.K. and R.J. PHELPS. 1968. Observations on the African bush-pig *Potamochoerus porcus* Linn. in Rhodesia. *Zoologica* 53: 75-84.

- SPINAGE, C.A. 1967. Ageing the Uganda defassa waterbuck *Kobus defassa ugandae* Neumann. *E. Afr. Wildl. J.* 5: 1-17.
- SPINAGE, C.A. 1973. A review of the age determination of mammals by means of teeth, with special reference to Africa. *E. Afr. Wildl. J.* 11: 165-187.
- SPINAGE, C.A. 1976a. Incremental cementum lines in the teeth of tropical African mammals. *J. Zool., Lond.* 178: 117-131.
- SPINAGE, C.A. 1976b. Age determination of the female Grant's gazelle. *E. Afr. Wildl. J.* 14: 121-134.
- SPINAGE, C.A. and G.M. JOLLY. 1974. Age estimation of warthog. *J. Wildl. Mgmt.* 38: 229-233.
- STEENKAMP, J.D.G. 1975. Guidelines to the use of dental histology in wildlife research. *J. S. Afr. Wildl. Mgmt. Ass.* 5: 89-93.
- THOMAS, D.C. 1977. Metachromatic staining of dental cementum for mammalian age determination. *J. Wildl. Mgmt.* 41: 207-210.
- TURNER, J.C. 1977. Cemental annulations as an age criterion in North American sheep. *J. Wildl. Mgmt.* 41: 211-217.