

Phytobezoar: A Rare Cause of Small Bowel Obstruction

Rajiv Nakarmi,^{a,d} Muza Shrestha,^{b,d} Sunder Maharjan^{c,d}

ABSTRACT:

Introduction: Small bowel obstruction is a common condition encountered in surgical practice. However, obstruction due to phytobezoars is a rarity. Until recently, phytobezoars were incidental findings during surgery. However, advances in imaging have eased the diagnosis by precisely identifying and locating the etiology. **Case report:** An 86-year-old lady presented to the emergency room with abdominal pain, distension, and inability to pass stool and flatus. Subsequent workup showed features of small bowel obstruction complicated with sepsis and worsening of preexisting respiratory co-morbidity. Exploration revealed a phytobezoar causing the bowel obstruction. **Conclusion:** Phytobezoar, though uncommon, should always be thought of while treating a case of intestinal obstruction in the elderly age group. Surgery is the mainstay of treatment. However, preexisting co-morbid condition plays a vital role in the outcome.

Keywords: Phytobezoar, Small bowel obstruction, Sepsis

INTRODUCTION:

Small bowel obstruction (SBO) is a commonly encountered surgical condition, frequently due to post-operative adhesions and inguinal hernia. However, SBO caused by bezoars is uncommon and approximately accounts for only 0.4–4%. [1] The term bezoar refers to an intraluminal mass in the gastrointestinal system caused by the accumulation of indigestible ingested materials, such as vegetables, fruits, and hair. It is called “panzehr” in Arabic and “padzhar” in Persian, which means antidote. [2,3] Bezoars are named according to the material they are made of: a trichobezoar consists of hair; a phytobezoar of vegetable and fruit residues; a lactobezoar is formed from dairy products; a pharmacobezoar is caused

by medications; a polybezoar is caused by ingested foreign bodies and biliary bezoars caused by bile stasis following hepatobiliary or gastric diversion surgery. [3,4,5]

CASE REPORT:

An 86-year-old lady presented to the Emergency Department (ED) with the chief complaints of abdominal pain for four days followed by generalized abdominal distension for three days. The pain was initially intermittent and relieved by over the counter painkiller, but it had gradually worsened to an unbearable state on the day of presentation for which she was rushed to the hospital. She also gave history of inability to pass stool and flatus for two days. She further complained of nausea but denied any episode of vomiting. She had no history of weight loss, fever, previously altered bowel habit. She was a known case of chronic obstructive pulmonary disease under medication with recurrent exacerbation. She had undergone cholecystectomy 35 years back.

Submitted: 31 May, 2020

Accepted: 28 December, 2020

Published: 31 December, 2020

a- Junior Consultant

b- Senior Consultant

c- Registrar

d- Department of General and Laparoscopic Surgery, Manmohan Memorial Medical College and Teaching Hospital.

Corresponding Author:

Rajiv Nakarmi

e-mail: rajivnakarmi31@gmail.com

ORCID: <https://orcid.org/0000-0003-2205-1784>

How to cite this article:

Nakarmi R, Shrestha M, Maharjan S. Phytobezoar: A Rare Cause of Small Bowel Obstruction. *Journal of Lumbini Medical College*. 2020;8(2):284-287. DOI: <https://doi.org/10.22502/jlmc.v8i2.364>. Epub: 2020 December 31.



Licensed under CC BY 4.0 International License which permits use, distribution and reproduction in any medium, provided the original work is properly cited.

On examination she looked anxious. Her blood pressure at the time of presentation was 70/50 mm of Hg, pulse rate was 98/min, respiratory rate was 30/min and temperature was 99°F. Laboratory test revealed leucocytosis of 14000/mm³. Per abdominally, she had central distension, generalized tenderness and rebound tenderness with increased bowel sound on auscultation.

The initial abdominal X-ray supine film showed distended central bowel loops (Fig.1) with multiple air fluid levels in erect film (Fig.2). A contrast-enhanced computed tomography (CECT) scan was done for confirmation which showed features of small bowel obstruction with transition point at terminal ileum. With the provisional diagnosis of acute small bowel obstruction with sepsis, emergency explorative laparotomy was performed after appropriate resuscitation.

Intraoperatively, a hard phytobezoar was found approximately 8cm proximal to the ileocecal junction with dilated proximal and collapsed distal ileum. No adhesions at the site of obstruction or stricture were seen. Around 300ml of reactive fluid was present in the peritoneal cavity. Enterotomy with removal of the bezoar was done followed by decompression and closure of enterotomy. Postoperatively, the patient was kept in elective ventilation. But on the fifth post-operative day, due to ongoing sepsis and exacerbation of co-morbid chest condition she developed type II respiratory failure.

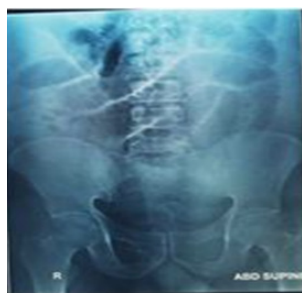

Fig. 1: Plain X-ray abdomen: Supine: Showing distended bowel loops.

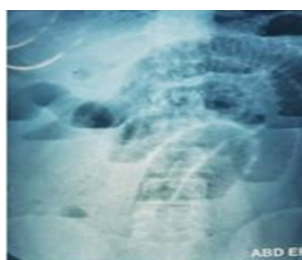


Fig. 2: Plain X-ray abdomen: Erect: Showing multiple air fluid level.

DISCUSSION:

The most common type of bezoar is phytobezoar, which consists of indigestible food residue, such as cellulose and hemicellulose. Bezoars are responsible for 0.4%-4% of cases of mechanical intestinal obstruction, although the true incidence is not known.[6, 7] There are several predisposing factors that can contribute to the formation of phytobezoars.

Gastric motility disorders and hypoacidity after gastric surgery are the basis of bezoar formation. Bezoars located in the stomach can pass through to the small intestines easily and cause symptoms of intestinal obstruction, especially in patients with pyloric dysfunction after a pyloroplasty or wide gastrojejunostomy, resulting in a wide gastric outlet.[3,8] In a study of 42 cases, Kement et al.[9] reported that previous gastric surgery was the most important factor predisposing to bezoar formation, with a rate of 48%. In their series, Krausz et al.[10] and Bowden et al.[11] reported rates of 20% to 93%. Bezoar-associated ileus is more common in cases undergoing surgery for ulcer treatment, although this has become rarer with the introduction of proton pump inhibitors.[11] In patients who have had surgery for ulcer treatment, a vagotomy accompanied by a partial gastrectomy is the most important factor predisposing to bezoar formation.[12]

A vagotomy and partial gastrectomy reduce gastric acidity, negatively affecting peptic activity. Furthermore, the antrum has an important role in the mechanical digestion of ingested food. The pylorus also prevents ingested food from passing through the small intestine as bolus, contributing to digestion. In this regard, the risk of bezoar formation was higher in patients who had a pyloroplasty and antrectomy. [9,10] The time taken for a bezoar to form after gastric surgery ranges from nine months to 30 years. [10] Bezoars can also form primarily in the small intestine when a mechanical factor alters the small intestinal passage, such as a diverticulum, stricture, or tumor.[9] Primary bezoars of the small intestine almost always cause intestinal obstruction. The most common location of obstruction is the terminal ileum.[13]

High-fiber foods such as celery, pumpkins, grape skins, prunes, and especially persimmons are a risk factor for bezoar formation.[9,10] Persimmons, which means the "God of fruits" in

Greek, are the fruit of plants in the genus *Diospyros*. Immature persimmons contain tannins, which form an adhesive-like substance when they encounter acids and hold other food residues, causing bezoar formation.[9] Krausz et al.[10]and Erzurumlu et al.[12]reported that 17% to 91% of bezoars in their series were caused by persimmons.

Other factors predisposing to bezoar formation include systemic diseases such as hypothyroidism causing impaired gastrointestinal motility, postoperative adhesions, diabetes mellitus, Guillain-Barré syndrome, and myotonic dystrophy. Personal factors such as swallowing a large amount of food without sufficient chewing due to dental problems, especially in the elderly, the use of medications slowing gastrointestinal motility, and renal failure are also predisposing factors.[4,12]This patient had chewing problem due to loss of most of the teeth. Erzurumlu et al. suggested that bezoar formation could occur without any predisposing factors.[12]

The most common symptom of bezoar-induced SBO is abdominal pain (96–100%) as seen in this patient. Other common symptoms include nausea and vomiting.[12] However, these symptoms were not evident in this patient. Primary small bowel phytobezoars almost always present as SBO. They usually are impacted in the narrowest part of the intestine especially in the terminal ileum and ileocecal valve as was found in our patient. The phytobezoar was impacted at the terminal ileum. It is interesting to note that more than half of reported cases with phytobezoars had a history of gastric surgery. The patient denied any previous gastrointestinal related surgery. Plain supine X-ray typically shows a classic obstructive pattern of SBO but rarely to detect bezoars. Occasionally, the outline of bezoar can be made out, which is difficult to differentiate from abscess or feces in the colon. The only evidence that we found in plain X-ray of our patient was small bowel loop dilatation (Fig.1). The cause of SBO can be diagnosed by CT in 73–95% of patients. CT shows intraluminal mass with mottled gas appearance associated with dilated small bowel proximal to the obstruction. The diagnostic accuracy of CT scan to diagnose bezoar-induced SBO is around 65–100%.[14] CT findings of our patient were also consistent with the bezoar-induced small bowel obstruction. The treatment of choice for SBO due to phytobezoar is surgery. The surgical management is easily performed by fragmenting the

bezoar and milking it down to the cecum without enterotomy. In a retrospective study fragmenting and milking bezoar was successful in 24 cases (53%). [15]

CONCLUSION:

Phytobezoar, though uncommon, should always be kept in mind while dealing with such cases especially in elderly people. The diagnosis is often challenging and often delayed leading to increase in morbidity and mortality. Surgery either open/laparoscopic is the treatment of choice. Prevention is the best form of treatment and intake of indigestible food residues should be avoided by the elderly people as they tend to have more digestion problems or cannot chew food properly.

Conflict of Interest: The authors declare that no competing interests exist.

Financial disclosure: No funds were available.

REFERENCES:

1. Teng H, Nawawi O, Ng K, Yik Y. Phytobezoar: an unusual cause of intestinal obstruction. *Biomed Imaging Interv J.* 2005;1(1):e4. PMID: 21625276. DOI: <https://doi.org/10.2349/biiij.1.1.e4>
2. Senol M, Ozdemir ZÜ, Sahiner IT, Ozdemir H. Intestinal Obstruction due to Colonic Lithobezoar: A Case Report and a Review of the Literature. *Case Rep Pediatr.* 2013; 2013:854975. PMID: 23424701. DOI: <https://doi.org/10.1155/2013/854975>
3. Williams RS. The fascinating history of bezoars. *Med J Aust.* 1986;145(11-12):613-4. PMID: 3540541.
4. Andrus CH, Ponsky JL. Bezoars: classification, pathophysiology, and treatment. *Am J Gastroenterol.* 1988;83(5):476-8. PMID: 3284334
5. Chintamani, Durkhure R, Singh JP, Singhal V. Cotton Bezoar--a rare cause of intestinal obstruction: case report. *BMC Surg.* 2003;3(0):5. PMID: 12956890. DOI: <https://doi.org/10.1186/1471-2482-3-5>
6. Altintoprak F. Gastric outlet syndrome associated with a recurrent trichobezoar: report of a case. *Turk J Gastroenterol.* 2010;21(4):471-2. PMID: 21332010. DOI: <https://doi.org/10.4318/tjg.2010.0143>
7. Ashfaq A, Madura JA 2nd, Chapital AB. An unusual case of biliary bezoar causing small bowel obstruction in a patient with ampullary diverticulum and stapled gastroplasty. *BMJ Case Rep.* 2014;2014:bcr2014207455. PMID: 25498113. DOI: <https://doi.org/10.1136/bcr-2014-207455>
8. Macari M, Megibow A. Imaging of suspected acute small bowel obstruction. *Semin Roentgenol.* 2001;36(2):108-17. PMID: 11329653. DOI: <https://doi.org/10.1053/sroe.2001.22827>
9. Kement M, Ozlem N, Colak E, Kesmer S, Gezen C, Vural S. Synergistic effect of multiple predisposing risk factors on the development of bezoars. *World J Gastroenterol.* 2012;18(9):960-4. PMID: 22408356. DOI: <https://doi.org/10.3748/wjg.v18.i9.960>
10. Krausz MM, Moriel EZ, Ayalon A, Pode D, Durst AL. Surgical aspects of gastrointestinal persimmon phytobezoar treatment. *Am J Surg.* 1986;152(5):526-30. PMID: 3777332. DOI: [https://doi.org/10.1016/0002-9610\(86\)90221-7](https://doi.org/10.1016/0002-9610(86)90221-7)
11. Bowden TA Jr, Hooks VH 3rd, Mansberger AR Jr. The stomach after surgery. An endoscopic perspective. *Ann Surg.* 1983;197(6):637-44. PMID: 6859976. DOI: <https://doi.org/10.1097/00000658-198306000-00001>
12. Erzurumlu K, Malazgirt Z, Bektas A, Dervisoglu A, Polat C, Senyurek G, et al. Gastrointestinal bezoars: a retrospective analysis of 34 cases. *World J Gastroenterol.* 2005;11(12):1813-7. PMID: 15793871. DOI: <https://doi.org/10.3748/wjg.v11.i12.1813>
13. Ezzat RF, Rashid SA, Rashid AT, Abdullah KM, Ahmed SM. Small intestinal obstruction due to phytobezoar: a case report. *J Med Case Rep.* 2009;3(0):9312. PMID: 20062741. DOI: <https://doi.org/10.1186/1752-1947-3-9312>
14. Oh SH, Namgung H, Park MH, Park DG. Bezoar-induced Small Bowel Obstruction. *J Korean Soc Coloproctol.* 2012;28(2):89-93. PMID: 22606648. DOI: <https://doi.org/10.3393/jksc.2012.28.2.89>
15. Bedioui H, Daghfous A, Ayadi M, Noomen R, Chebbi F, Rebai W, et al. A report of 15 cases of small bowel obstruction secondary to phytobezoars: predisposing factors and diagnostic difficulties. *Gastroenterol Clin Biol.* 2008;32(6-7):596-600. PMID: 18487032. DOI: <https://doi.org/10.1016/j.gcb.2008.01.045>