

# The Relationship of The Mandibular Canal to The Roots of Impacted Third Molars- The Root Factor: A Panoramic Radiographic Study.

Harleen Bali,<sup>a,g</sup> Deepak Yadav,<sup>b,h</sup> Khushbu Adhikari,<sup>c,i</sup> Swagat Kumar Mahanta,<sup>d,g</sup> Rupam Tripathi,<sup>e,h</sup> Binam Sapkota<sup>f,g</sup>

## ABSTRACT

**Introduction:** Third molar extractions are one of the most common reasons of injury to mandibular nerve and post-operative complications. Pre-operative assessment of pending doom is a must. In order to study the relations between change in Inferior Alveolar Canal (IAC) and Type, Class, and Level of impaction with radiographic root change of impacted third mandibular molar, we designed a study to assess the relationship of the mandibular canal to the roots of impacted third molar in reference to changes in roots and factors affecting it. **Methods:** This was a retrospective cross-sectional study where in the panoramic radiographic records of subjects with impacted third molar were assessed for change in root and its correlation with change in IAC, Type, Class and Level of impacted mandibular third molar. **Results:** Roots of impacted third molar when in contact with IAC presented most often in our study subjects with the Darkening of roots in both sides {right side (16.79%) and left side (11.29%)} and both genders {males (right-14.29%, left-8.75%) and females (right-19.39%, left-13.94%)}. They were statistically significantly associated with interruption of white line of IAC, vertically impacted third molars and Pell and Gregory Class II, Level A of impaction. **Conclusion:** There is a need to properly identify radiographic risk predictor signs to avoid any surprises at the time of extraction and post-operative complications following it.

**Keywords:** Impacted tooth, Mandibular nerve, Panoramic radiography

## INTRODUCTION:

Impacted teeth have been associated with pathologies such as cysts, tumors, infections, inflammations of jaws as well as displacement and resorption of adjacent teeth. The mandibular third molars are among the most frequent to be impacted.[1] Their

extraction can cause direct injury to Inferior Alveolar Nerve (IAN) or hematoma formation following extraction putting pressure over the nerve leading to neurosensory disturbances.[2,3]

Studies have reported that the prevalence of IAN paraesthesia following third molar surgery ranges approximately from 0.4% to 8.4%.[4] In order to avoid such untoward incidents pre-operative investigations are required to plan the protocol best suiting the scenario.

Among 2D imaging, surgeons prefer panoramic radiographs than intraoral periapical radiographs for planning third molar extraction. Though 3D imaging modalities promise clearer picture, their reduced accessibility and high cost have restricted their use

**Submitted:** 22 April, 2020

**Accepted:** 25 May, 2020

**Published:** 15 June, 2020

a- Lecturer, Department of Oral Medicine and Radiology,

b- Associate Professor, Department of Oral and Maxillofacial Surgery,

c- Assistant Professor, Department of Periodontology and Oral Implantology,

d- Lecturer, Department of Community Dentistry,

e- Lecturer, Department of Conservative Dentistry and Endodontics,

f- Associate Professor, Department of Prosthodontics,

g-Dhulikhel Hospital, KUSMS, Nepal

h-Universal College of Medical Sciences-College of Dental Surgery, Bhairhawa, Nepal.

i-B.P. Koirala Institute of Health Sciences, Dharan, Nepal.

## Corresponding Author:

Harleen Bali

e-mail: [harleenbali.hb@gmail.com](mailto:harleenbali.hb@gmail.com)

ORCID: <https://orcid.org/0000-0001-8647-9582>

## How to cite this article:

Bali H, Yadav D, Adhikari K, Mahanta SK, Tripathi R, Sapkota B. The Relationship of the Mandibular Canal to the Roots of Impacted Third Molars- The Root factor: A Panoramic Radiographic Study. Journal of Lumbini Medical College. 2020;8(1):8 pages DOI: <https://doi.org/10.22502/jlmc.v8i1.303> Epub: 2020 June 15.



Licensed under CC BY 4.0 International License which permits use, distribution and reproduction in any medium, provided the original work is properly cited.

in developing countries.

Studies are available on prevalence of root changes[5] seen in mandibular third molar when in contact with Inferior Alveolar Canal (IAC) but the relation of change in root with factors like change in IAC, type, level and class of impaction is less explored and none so in Nepal to the best of our knowledge.

Therefore, the aim of our study was to assess the root changes seen in mandibular third molar when in contact with IAC and factors affecting it.

## METHODS:

This descriptive cross-sectional study was conducted in Universal College of Medical Sciences- College of Dental Surgery, Bhairahawa. The radiographic records of patients with impacted third molar were selected in a retrospective manner. The records from January 2016 were selected as starting point and all preoperative orthopantomograms (OPGs) till February 2018 were selected for the present study. Ethical clearance was obtained from the Institutional Ethical Committee prior to conducting the study.

More than 2000 panoramic radiographs were scanned, of which 673 were included in this study. All radiographs had been taken using Vatech digital X-ray system, model: PCH-2500 (power input: AC 100-120/200-240 V, 50/60 Hz, 2.0 kVA Max. 170 VA Normal; output- 90 kV, 10 mA and Focal Spot 0.5x0.5 mm). All OPGs were shot at 73kVp, 10.0mA and scan time 13.5 seconds in standard mode.

The inclusion criterion was individuals' OPG presenting with bilateral impacted mandibular third molars with root completion and presence of mandibular second molars.

The exclusion criteria were individuals with:

- (1) trauma/surgery to the mandibular site of study,
- (2) developmental anomalies affecting the jaws, and
- (3) radiographic evidence of pathologies of the impacted mandibular third molar teeth of mandible which could obscure the visualization of the periapical region or IAC.

The radiographs were observed and read by an oral and maxillofacial surgeon, well trained and

experienced in reading radiographs.

The type of impaction of mandibular third molars was identified by the method adapted by Winter.[6] Subsequently, they were categorized as mesioangular, distoangular, vertical or horizontal impactions. The Pell–Gregory classification[7] in relation to ramus of the mandible (Class I, II and III) and Pell–Gregory classification[7] in relation to depth/level of mandibular third molar in relation to occlusal surface of second molar (A, B and C) was also identified and recorded.

Digital panoramic radiographs were then interpreted cautiously for the following:

The presence of each of the following sign in root of mandibular third molar and Inferior Alveolar Canal changes (Rood and Shehab).[5]

Changes in root:

- a. Darkening of the root: Loss of root density in a tooth that is impinged upon by the canal.
- b. Deflection of the root: An abrupt deviation of roots near the canal.
- c. Dark and bifid root apex: A loss of root density in a tooth that is impinged upon by the canal with bifid apex of the root.
- d. Narrowing of the root: Narrowing of the tooth roots where the canal crosses.

Changes in IAC:

- a. Interruption of the white line: Discontinuity of the superior radio-opaque line that constitutes the superior border of the inferior alveolar canal.
- b. Diversion of the canal: A change in the direction of the canal while crossing the mandibular third molar.
- c. Narrowing of the canal: An abrupt decrease in the width of the canal while it crosses the root apices.

Data was entered in MS Excel sheet and analyzed using Statistical Package for Social Sciences (SPSS™) software version 20.

Statistical analysis was done to evaluate the change in roots of impacted third molar caused by contact/superimposition of IAC

- a. with respect to right or left side of mandible
- b. with respect to gender
- c. Its relation to the Type of impaction, Pell–

**Gregory Class and Level of Impaction of mandibular third molar.**

Descriptive statistics and Chi-Square, post hoc test was done. P value <0.01 was considered significant.

**RESULTS:**

The tabulated results were analyzed. Of the selected 673 radiographs, 330 (49.03%) were of females and 343 (50.96%) were of males. The age group ranged from 21 to 65 years (Mean±SD=31.63±11.98). Radiographic risk predictor signs in roots of impacted mandibular third molar were seen in 176 (26.15%) subjects on the right side and 133(19.76%) on the left side (Figure 1).

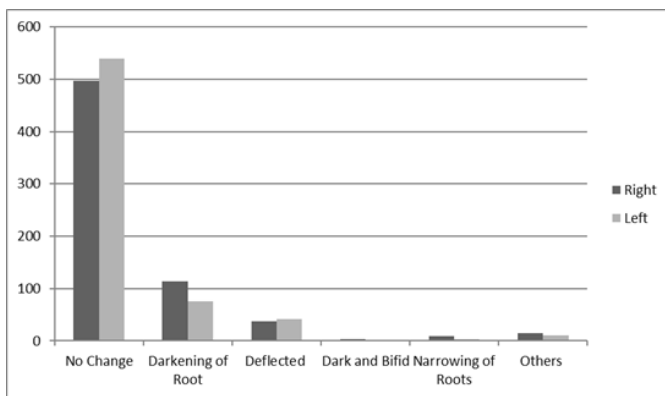


Fig. 1. Overall change in roots in our study.

Roots of impacted third molar when in contact with IAC presented most often in our study subjects with the darkening of roots in both sides {figure1-right side (16.79%) and left side (11.29%)} and both genders {table 1: Males (right-14.29%, left-8.75%) and Females (right-19.39%, left-13.94%)}. Darkening along with other changes was also seen and grouped under others. Change in roots of

impacted third molar when correlated with changes noticed in IAC, showed interruption of white line (table 2a: right side-55.90%, left side-56.98%) as the most common effect. The results were statistically highly significant (p<0.001). Post hoc test after chi square was done to know which group was statistically significant among them. It showed that interruption of white line (right and left side of mandible), while diversion of IAC on left side were statistically highly significant (see table 2b). An analysis of Winter's Classification of Type of impaction correlation with darkening of roots revealed vertical impaction (Table 3: right side-62.99%, left side-52.33%), followed by mesioangular impaction (right side-27.56%, left side-36.05%). The results were statistically significant (p<0.01) on right side and statistically highly significant (p<0.001) on left side. Pell and Gregory Category for depth/Level of mandibular third molar impaction when correlated with the change in roots i.e. Darkening of roots showed position A (Table 4: right side-58.27%, left side-47.67%) followed by position B (right side-26.77%, left side- 30.23%) as most related.

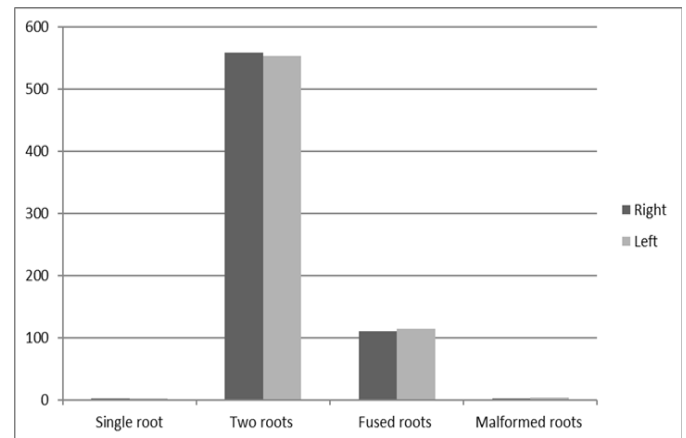


Fig. 2. No. of roots of mandibular third molar with respect to right and left side.

Pell and Gregory Class defining space

Table 1. Change in root of mandibular third molar as per gender.

Change in root	Male (Frequency, %)		Female (Frequency, %)	
	Right	Left	Right	Left
<b>No Change</b>	266 (77.55%)	288(83.97%)	231 (70.00%)	252 (76.36%)
<b>Darkening of Root</b>	49 (14.29%)	30 (8.75%)	64 (19.39%)	46 (13.94%)
<b>Deflected</b>	17 (4.96%)	19 (5.54%)	20 (6.06%)	23 (6.97%)
<b>Dark and Bifid</b>	1 (0.29%)	1 (0.29%)	2 (0.61%)	0 (0.0%)
<b>Narrowing of Roots</b>	2 (0.58%)	1 (0.29%)	7 (2.12%)	3 (0.91%)
<b>Others</b>	8 (2.33%)	4 (1.16%)	6 (1.82%)	6 (1.82%)
<b>Total</b>	343	343	330	330

Table 2a. Darkening of roots of mandibular third molar on right and left side of mandible with respect to change in IAC seen on the same side.

Change in IAC	Right		Left	
No Change	41 (32.28%)	$X^2(6,127)=165.116,$ p value < 0.001*	21 (24.42%)	$X^2(6,86)=134.185,$ p value < 0.001*
Interruption of white line	71 (55.90%)		49 (56.98%)	
Diversion of IAC	5 (3.94%)		6 (6.98%)	
Narrowing of IAC	5 (3.94%)		5 (5.81%)	
Others	5 (3.94%)		5 (5.81%)	
Total	127		86	

Table 2b. Darkening of roots of mandibular third molar on right and left side of mandible with respect to change in IAC seen on the same side.

Change in IAC	Right side		Left side		p-value	
	Right side	Left side	Right side	Left side	Right side	Left side
No Change	41	21	<0.001	<0.001		
Interruption of white line	71	49	<0.001	<0.001		
Diversion of IAC	5	6	.10358	.00065		
Narrowing of IAC	5	5	.2096	.5407		
Others	5	5	.011	<0.001		

Table 3: Darkening of roots in respect to Winter’s Classification of type of impaction of mandibular third molar.

Winter’s Classification	Right		Left	
Mesioangular	35 (27.56%)	$X^2(3,127)=13.490,$ p value < 0.01*	31 (36.05%)	$X^2(4,86)=24.347,$ p value < 0.001*
Distoangular	5 (3.94%)		5 (5.81%)	
Vertical	80 (62.99%)		45 (52.33%)	
Horizontal	7 (5.51%)		5 (5.81%)	
Total	127		86	

Table 4: Darkening of roots in respect to Pell and Gregory Depth/Level of Impaction of mandibular third molar.

Pell and Gregory Level of Impaction	Right		Left	
A	74 (58.27%)	$X^2(3,127)=27.426$ p value <0.001*	41 (47.67%)	$X^2(3,86)=46.638$ p value <0.001*
B	34 (26.77%)		26 (30.23%)	
C	19 (14.96%)		19 (22.1%)	
Total	127		86	

Table 5: Darkening of roots in respect to Pell and Gregory Class of Impaction of mandibular third molar.

Pell and Gregory Class of Impaction	Right		Left	
I	52 (40.94%)	$X^2(3,127)=33.175,$ p value <0.001*	27 (31.4%)	$X^2(3,86)=38.6$ p value <0.001*
II	61 (48.03%)		48 (55.81%)	
III	14 (11.02%)		11 (12.79%)	
Total	127		86	

\* denotes statistically significant.



available between the anterior border of the ascending ramus and the distal aspect of the second molar when correlated with the Darkening of roots showed class II (Table 5: right side-48.03%, left side-55.81%) followed by class I (right side-40.94%, left side- 31.4%) as most related. The results were statistically highly significant ( $p < 0.001$ ).

## DISCUSSION:

One of the complications of extraction of impacted mandibular third molars is dysaesthesia due to injury to the IAN either directly or following hematoma formation. Rood and Shebab[5] studied and recognized various radiographic risk predictor signs. With the coming of new and advanced 3 D imaging modalities, investigations for pre-operative decision making have become an indispensable tool. Still panoramic radiographs hold their own significance when coming to pre-operative investigation for impacted tooth extraction as they are easily accessible and more affordable for the patients in developing countries.

Males constituted more than females in our study sample in accordance with Gupta et al.,[8] and Deshpande.[1] In contrast, studies by Jerjes,[3] Knutsson et al.,[9] and Szalma et al.,[10] observed a female preponderance.

Previous studies on panoramic radiograph reported that the darkening of the third molar root was strongly suggestive of an intimate relationship between the root and nerve, or nerve injury following third molar extraction.[4,5,11,12,13,14,15,16,17,18]

Our study showed that darkening of roots was most common phenomenon (with respect to gender and right and left side; table 1 and graph 1) noted on panoramic radiograph under change in roots of mandibular third molars when in contact/ superimposed by IAC and that it was associated with interruption of white line of IAC in majority of cases (Table 2). This could be attributed to the researches reporting that darkening or dark band across the roots when in contact with the IAC is due to loss of dentine caused by grooving of the root by the canal[14,19,20] or that darkening of the root may indicate thinning of the cortical plate rather than grooving of the root as observed by Mahasantipiya et al.[21]

Our study findings were in accordance with Peker et al.,[22] who reported a significant correlation

between darkening of the roots and interruption of the white line on panoramic radiography and the presence of contact on Cone Beam Computed Tomography (CBCT) images. Study by Neves et al.,[23] also concluded that darkening of roots and interruption of white line observed on panoramic radiographs, both as isolated findings and in association, were effective in determining the risk relationship between the tooth roots and the IAC.

Our study reported that darkening of roots was most frequently associated with vertical impactions, followed by mesioangular impactions among our subjects (Table 3). This was in contrast with Miloro and DaBell[24] who reported that mesioangular impactions followed by vertical impactions were closer to the inferior alveolar canal. Deshpande et al.,[1] also reported mesioangular impactions to be associated with radiographic risk predictor signs followed by horizontal impactions, but stated it to be statistically insignificant similar to study concluded by Blaeser et al.[25]

Monaco G et al.,[12], Hashemipour MA et al.[26] and Obiechina AE et al.[27] reported that the level of impaction assessed based on the Pell and Gregory classification showed that Level A of impaction was the most common when considering both upper and lower third molars. In our study Level A of impaction for mandibular third molars was most associated with darkening of roots (Table 4).

Haung et al.,[28] in their study found that majority of impacted mandibular third molars were in Pell and Gregory Class II. Our results showed impaction was in Class II in majority cases in respect to darkening of roots (Table 5).

Our study was limited to the use of panoramic radiograph whereas more sophisticated imaging modalities such as CBCT are available today. Panoramic radiograph can be used as preliminary investigation to assess the relationship of IAC and mandibular third molars. If it shows proximity between the two structures further investigations using 3 D imaging, though expensive and not as accessible as panoramic, should be considered.

Though this was a panoramic study, meta-analysis by Atieh in 2010,[29] done to determine the diagnostic accuracy of panoramic radiographic markers in detecting the relationship between

impacted mandibular third molar roots and the inferior alveolar canal suggested a reasonable diagnostic accuracy for panoramic radiography for the same.

#### **CONCLUSION:**

Our study showed darkening of root as the most common radiographic risk predictor sign seen on panoramic radiographs when change in roots of mandibular third molar was studied. They were statistically significantly associated with interruption of white line of IAC, vertically impacted third molars and Pell and Gregory Class II, Level A of impaction.

We conclude that there is a need to properly identify radiographic risk predictor signs to avoid any surprises at the time of extraction and post operation complications following it.

**Conflict of interest:** The authors declare that no competing interests exist.

**Financial disclosure:** No funds were available for the study.

## REFERENCES:

1. Deshpande P, Guledgud MV, Patil K. Proximity of Impacted Mandibular Third Molars to the Inferior Alveolar Canal and Its Radiographic Predictors: A Panoramic Radiographic Study. *J Maxillofac Oral Surg.* 2013;12(2):145–51. PMID: 24431832. DOI: <https://doi.org/10.1007/s12663-012-0409-z>
2. Bouloux GF, Steed MB, Perciaccante VJ. Complications of third molar surgery. *Oral Maxillofac Surg Clin North Am.* 2007;19(1):117-28. PMID: 18088870. DOI: <https://doi.org/10.1016/j.coms.2006.11.013>
3. Jerjes W, Upile T, Shah P, Nhembe F, Gudka D, Kafas P, et al. Risk factors associated with injury to the inferior alveolar and lingual nerves following third molar surgery-revisited. *Oral Surg Oral Med Oral Pathol Oral Radiol Endod.* 2010;109(3):335–45. PMID: 20097103. DOI: <https://doi.org/10.1016/j.tripleo.2009.10.010>
4. Valmaseda-Castellón E, Berini-Aytes L, Gay-Escoda C. Inferior alveolar nerve damage after lower third molar surgical extraction: A prospective study of 1117 surgical extractions. *Oral Surg Oral Med Oral Pathol Oral Radiol Endod.* 2001;92(4):377-83. PMID: 11598570. DOI: <https://doi.org/10.1067/moe.2001.118284>
5. Rood JP, Shehab BA. The radiological predilection of inferior alveolar nerve injury during third molar surgery. *Br J Oral Maxillofac Surg.* 1990;28(1):20-5. PMID: 2322523. DOI: [https://doi.org/10.1016/0266-4356\(90\)90005-6](https://doi.org/10.1016/0266-4356(90)90005-6)
6. Winter GB. Principles of exodontia as applied to the impacted third molar; a complete treatise on the operative technic with clinical diagnoses and radiographic interpretations. St Louis: American Medical Book Company;1926. Available from: <https://openlibrary.org/books/OL6696325M/>
7. Pell GJ, Gregory GT. Impacted mandibular third molars: Classification and modified technique for removal. *Dent Dig.* 1933;39(0):330-8.
8. Gupta S, Bhowate RR, Nigam N, Saxena S. Evaluation of impacted mandibular third molars by panoramic radiography. *ISRN Dent.* 2011;2011(0):406714. PMID: 21991473. DOI: <https://doi.org/10.5402/2011/406714>
9. Knutsson K, Brehmer B, Lysell L, Rohlin M. Pathoses associated with mandibular third molars subjected to removal. *Oral Surg Oral Med Oral Pathol Oral Radiol Endod.* 1996;82(1):10-7. PMID: 8843448. DOI: [https://doi.org/10.1016/s1079-2104\(96\)80371-4](https://doi.org/10.1016/s1079-2104(96)80371-4)
10. Szalma J, Lempel E, Jeges S, Szabó G, Olasz L. The prognostic value of panoramic radiography of inferior alveolar nerve damage after mandibular third molar removal: Retrospective study of 400 cases. *Oral Surg Oral Med Oral Pathol Oral Radiol Endod.* 2010;109(2):294-302. PMID: 19846324. DOI: <https://doi.org/10.1016/j.tripleo.2009.09.023>
11. Kipp DP, Goldstein BH, Weiss Jr WW. Dysesthesia after mandibular third molar surgery: A retrospective study and analysis of 1,377 surgical procedures. *J Am Dent Assoc.* 1980;100(2):185-92. PMID: 69228147. DOI: <https://doi.org/10.14219/jada.archive.1980.0074>
12. Monaco G, Montevecchi M, Bonetti GA, Gatto MRA, Checchi L. Reliability of panoramic radiography in evaluating the topographic relationship between the mandibular canal and impacted third molars. *J Am Dent Assoc.* 2004;135(3):312-8. PMID: 15058618. DOI: <https://doi.org/10.14219/jada.archive.2004.0179>
13. Sedaghatfar M, August MA, Dodson TB. Panoramic radiographic findings as predictors of inferior alveolar nerve exposure following third molar extraction. *J Oral Maxillofac Surg.* 2005;63(1):3-7. PMID: 15635549. DOI: <https://doi.org/10.1016/j.joms.2004.05.217>
14. Howe GL, Poyton HG. Prevention of damage to the inferior dental nerve during the extraction of mandibular third molars. *British Dental Journal.* 1960;109(0):355-63.
15. Bell GW. Use of dental panoramic tomographs to predict the relation between mandibular third molar teeth and the inferior alveolar nerve. Radiological and surgical findings, and clinical outcome. *Br J Oral Maxillofac Surg.* 2004;42(1):21-7. PMID: 14706294. DOI: [https://doi.org/10.1016/s0266-4356\(03\)00186-4](https://doi.org/10.1016/s0266-4356(03)00186-4)
16. Rud J. Third molar surgery: Relationship of root to mandibular canal and injuries to inferior dental nerve. *Tandlaegebladet.* 1983;87(18):619–31. PMID: 6585010
17. de Melo Albert DG, Gomes AC, do Egito

- Vasconcelos BC, de Oliveira e Silva ED, Holanda GZ. Comparison of orthopantomographs and conventional tomography images for assessing the relationship between impacted lower third molars and the mandibular canal. *J Oral Maxillofac Surg.* 2006;64(7):1030-7. PMID: 16781335. DOI: <https://doi.org/10.1016/j.joms.2006.03.020>
18. Tantanapornkul W, Okochi K, Bhakdinaronk A, Ohbayashi N, Kurabayashi T. Correlation of darkening of impacted mandibular third molar root on digital panoramic images with cone beam computed tomography findings. *Dentomaxillofac Radiol.* 2009;38(1):11-6. PMID: 19114418. DOI: <https://doi.org/10.1259/dmfr/83819416>
19. Ohman A, Kivijärvi K, Blomäback U, Flygare L. Pre-operative radiographic evaluation of lower third molars with computed tomography. *Dentomaxillofac Radiol.* 2006;35(1):30-5. PMID: 16421261. DOI: <https://doi.org/10.1259/dmfr/58068337>
20. Seward GR. Radiology in general dental practice: VIII-Assessment of lower third molars. *British Dental Journal.* 1963;115(0):45-51.
21. Mahasantipiya PM, Savage NW, Monsour PA, Wilson RJ. Narrowing of the inferior dental canal in relation to the lower third molars. *Dentomaxillofac Radiol.* 2005;34(3): 154-63. PMID: 15897286. DOI: <https://doi.org/10.1259/dmfr/31872903>
22. Peker I, Sarikir C, Alkurt MT, Zor ZF. Panoramic radiography and cone-beam computed tomography findings in preoperative examination of impacted mandibular third molars. *BMC Oral Health.* 2014;14(0):71. PMID: 24928108. DOI: <https://doi.org/10.1186/1472-6831-14-71>
23. Neves FS, Souza TC, Almeida SM, Haiter-Neto F, Freitas DQ, Bóscolo FN. Correlation of panoramic radiography and cone beam CT findings in the assessment of the relationship between impacted mandibular third molars and the mandibular canal. *Dentomaxillofac Radiol.* 2012;41(7):553-7. PMID: 22282507. DOI: <https://dx.doi.org/10.1259%2Fdmfr%2F22263461>
24. Miloro M, DaBell J. Radiographic proximity of the mandibular third molar to the inferior alveolar canal. *Oral Surg Oral Med Oral Pathol Oral Radiol Endod.* 2005;100(5):545-9. PMID: 16243238. DOI <https://doi.org/10.1016/j.tripleo.2005.03.009>
25. Blaeser BF, August MA, Donoff RB, Kaban LB, Dodson TB. Panoramic radiographic risk factors for inferior alveolar nerve injury after third molar extraction. *J Oral Maxillofac Surg.* 2003;61(4):417-21. PMID: 12684956. DOI: <https://doi.org/10.1053/joms.2003.50088>
26. Hashemipour MA, Tahmasbi-Arashlow M, Fahimi-Hanzaei F. Incidence of impacted mandibular and maxillary third molars: a radiographic study in a Southeast Iran population. *Med Oral Patol Oral Cir Bucal.* 2013;18(1):e140-e145. PMID: 23229243. DOI: <https://dx.doi.org/10.4317%2Fmedoral.18028>
27. Obiechina AE, Arotiba JT, Fasola AO. Third molar impaction: Evaluation of the symptoms and pattern of impaction of mandibular third molar teeth in Nigerians. *Odontostomatol Trop.* 2001;24(93):22-5. PMID: 11484653.
28. Huang CK, Lui MT, Cheng DH. Use of panoramic radiography to predict postsurgical sensory impairment following extraction of impacted mandibular third molars. *J Chin Med Assoc.* 2015;78(10):617-22. PMID: 26041067. DOI: <https://doi.org/10.1016/j.jcma.2015.01.009>
29. Atieh MA. Diagnostic accuracy of panoramic radiography in determining relationship between inferior alveolar nerve and mandibular third molar. *J Oral Maxillofac Surg.* 2010;68(1):74-82. PMID: 20006158. DOI: <https://doi.org/10.1016/j.joms.2009.04.074>