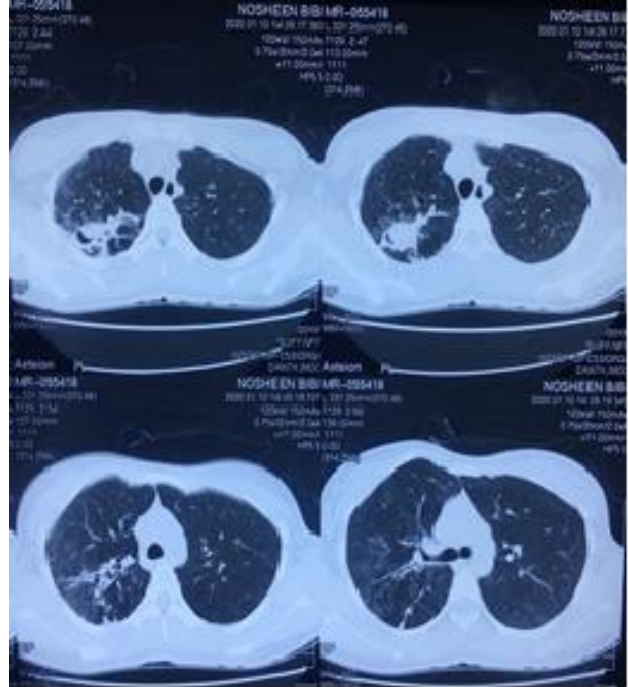
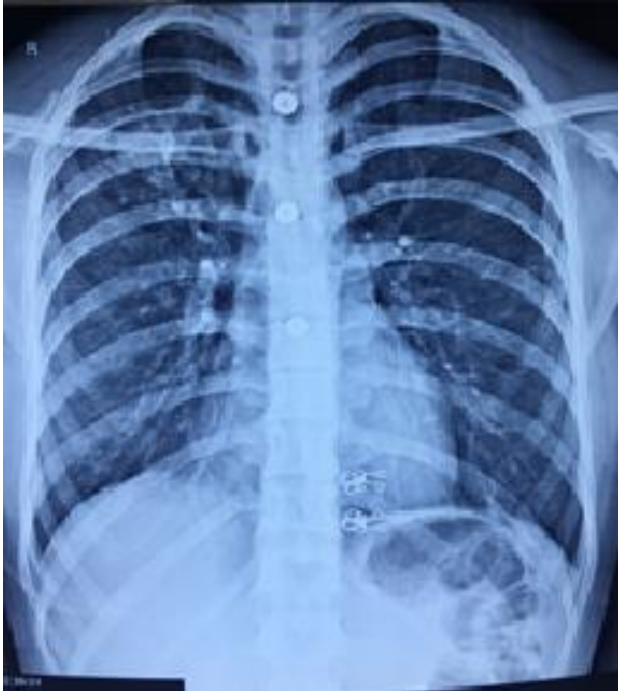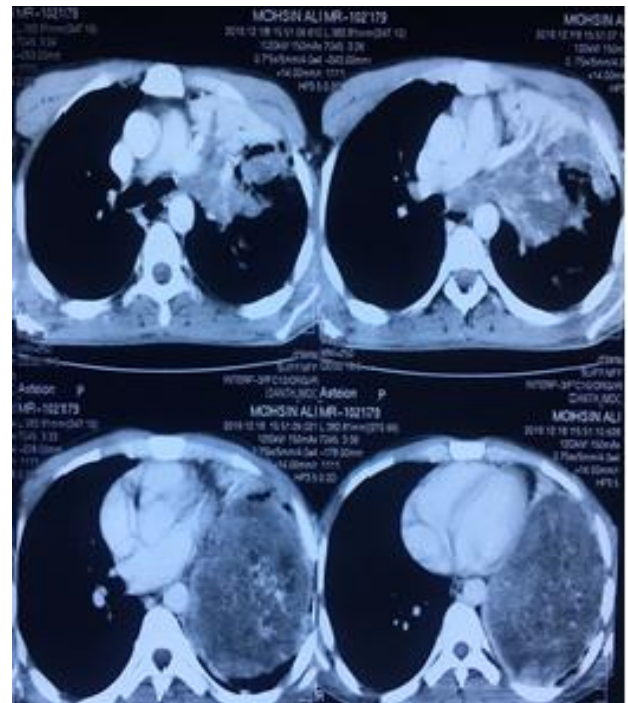

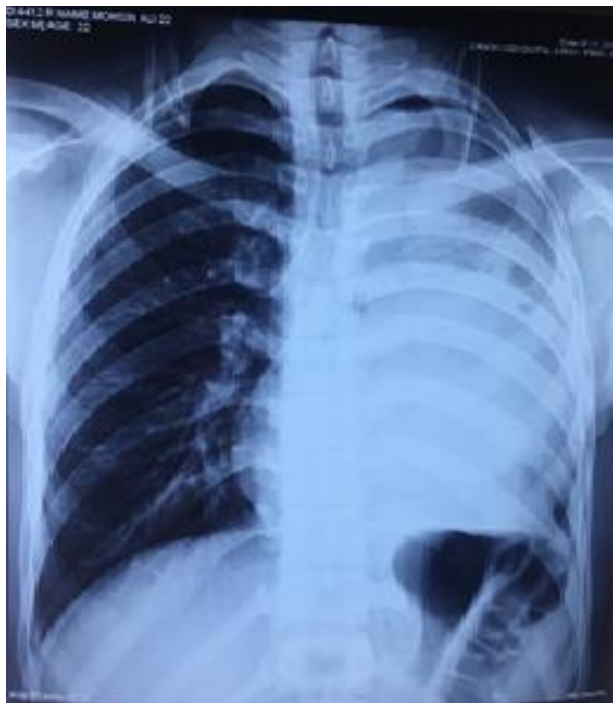
RADIOLOGICAL IMAGES

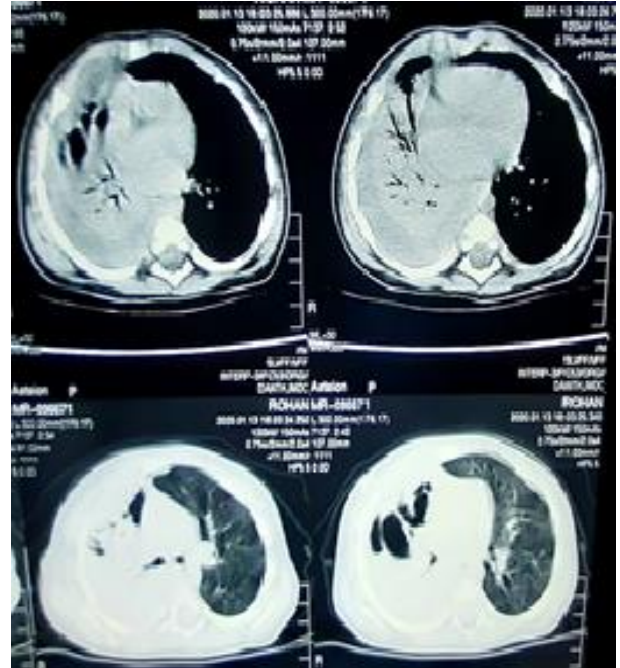
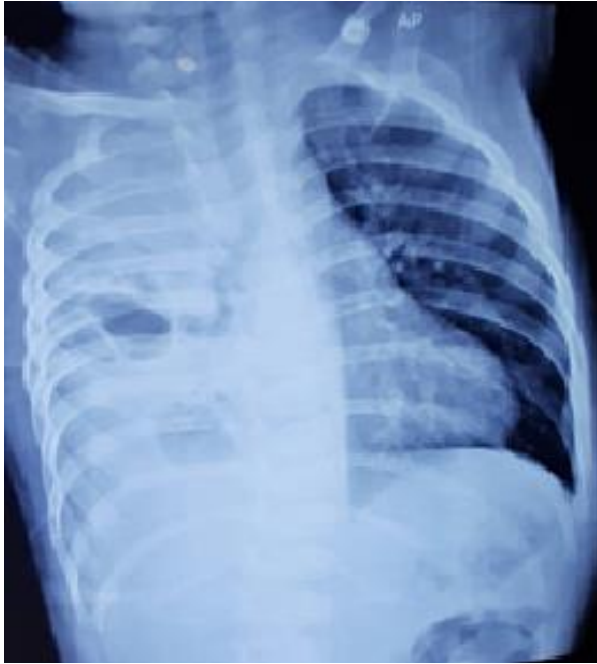Aspergilloma Formation in Chronic Tuberculous Cavity along with Reactivation of Tuberculosis



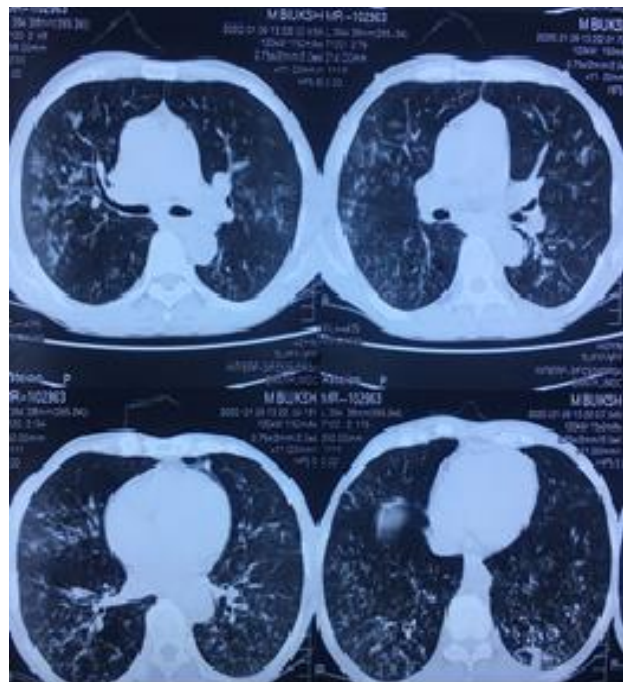
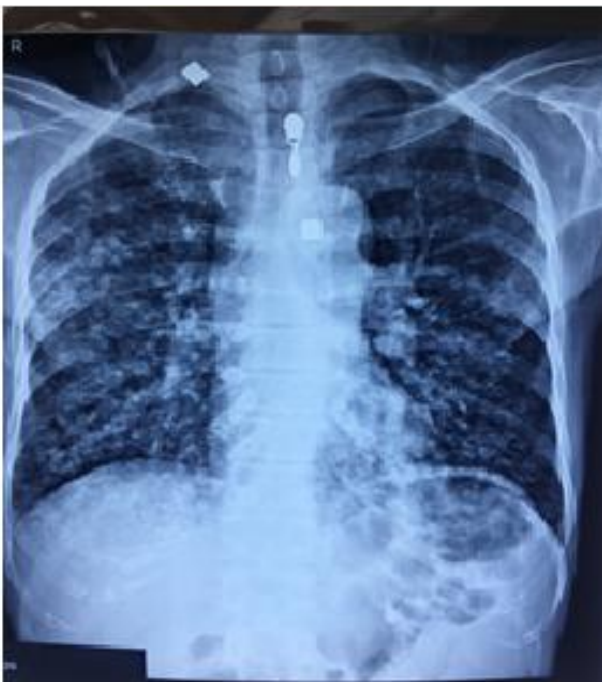Adenocarcinoma left lung



Cavitating Pneumonia in an Infant



CMV Pneumonia in AIDS Patient



CMV: Cytomegalovirus
AIDS: Acquired immunodeficiency syndrome

Contributed by:

Department of Radiology
Dr. Akbar Niazi Teaching Hospital, Islamabad