

Use of Gastrocnemius Muscle and Musculocutaneous Flaps for Coverage of Soft Tissue Defects in Leg

Muhammad Naveed Shahzad¹, Muhammad Ayub², Muhammad Afzal Sajid³

¹Senior registrar plastic surgery, Department of Plastic Surgery, Nishtar Hospital, Multan

²Senior registrar surgery, Department of general surgery, Nishtar Hospital, Multan

³Emergency surgeon, Department of general surgery, Nishtar Hospital, Multan

Abstract

Objective: To share our experience of proximally based gastrocnemius flap use, recipient-site variables, donor-site management, complications, and outcomes.

Patients and Methods: This retrospective study was conducted at Pak Italian Modern Burn Center Nishtar Hospital Multan from January 2009 to December 2014. The records of 139 patients were retrieved from the departmental medical record system and the required information regarding the demographic, diagnostic, and clinical data (like patients' particulars---age and sex, history of occupation, any previous surgery, causes of the defects, the extent and dimensions of the defects, time since injury, exposure of bone or tendons, presence of chronic osteomyelitis, any co-morbid conditions, postoperative course regarding wound-healing difficulties, flap loss, postoperative palsy of the peroneal nerve after elevation of lateral gastrocnemius and walking limitations) were noted. Pre and post-operative photographs and radiographs were also evaluated along with follow up of at least 6 weeks.

Results: Out of 139 our 134 flaps survived with only 1 flap having partial necrosis and 4 flaps with marginal necrosis. The complication rate is low

Conclusion: GC is a robust flap and is number one choice in proximal tibial defects as even in extensive trauma this flap can be elevated and used safely.

Key words: Proximal tibial defects. Gastrocnemius muscle, Musculocutaneous flap

Introduction

Long bone fractures are seen in 11.5 per 100,000 persons per year and are more common in males.^{1,2} The proximal tibia has been defined as the part of the tibia that extends from the knee joint distally for 1.5 times the medial to lateral joint width.³ In this area fractures are grossly heterogeneous and their prognosis depends on Intra-articular involvement, fracture comminution, condition of

the soft-tissue, osteoporosis, patient's age and comorbidities.⁴ Regardless of the pattern of a proximal tibia fracture, the soft tissues around the knee joint can be injured with variable severity. Over the period of years, standards for the management of open fractures have evolved because of collaborations between orthopaedic surgeons and plastic surgeons.⁵ The aim of plastic surgeon in the treatment of open fractures is to provide well vascularized soft-tissue coverage to the wound, so as to promote revascularization of injured bone and soft tissues, and to prevent late osteomyelitis and nonunion that may occur secondary to persistent bone ischemia.^{6,7,8} Defects surrounding the knee and proximal tibia result from trauma, tumor, or infection. Both lateral and medial gastrocnemius flaps are used as a muscle or myocutaneous flap to cover defects surrounding the knee, lower thigh, patellar region and upper third of tibia. Its consistent vascular anatomy and superficial location have made it a workhorse for coverage of defects in this area. Transposition of one head of the gastrocnemius results in little or no functional deficit, provided, the soleus and the other head of the gastrocnemius are left intact and functioning. If necessary, subsequent bony procedures can be carried out by elevating the healed flap with the assurance of a good vascular supply. In this study we share our experience of proximally based (medial or lateral) gastrocnemius muscle or myocutaneous flap use, recipient-site variables, donor-site management, complications, and outcomes.

Patients and Methods

A retrospective clinical audit was done on 139 consecutive cases of gastrocnemius flap, with at least a six weeks follow up at the Pak Italian Modern Burn Center Nishtar Hospital Multan from January 2009 to December 2014. Patients having small to medium sized defects surrounding the knee, lower thigh, patellar region and proximal tibia were included in the study. All these patients were referred to our department from orthopedic department after bony fixation. Patients with extensive tissue loss, deep severe scarring or wounds on the popliteal area or the pedicle site were excluded from the study.

Corresponding Author:

Muhammad Naveed Shahzad

E-mail: drmuhammaad@gmail.com

Received: June 24,2016; Accepted: Sept 29,2016

The records of patients were retrieved from the departmental medical record system and the required information regarding the demographic, diagnostic, and clinical data (like patient's age and sex, history of occupation, any previous surgery, causes of the defects, the extent and dimensions of the defects, time since injury, exposure of bone or tendons, presence of chronic osteomyelitis, any co-morbid conditions, postoperative course regarding wound-healing difficulties, flap loss, postoperative palsy of the peroneal nerve after elevation of lateral gastrocnemius and walking limitations) were noted. Pre and post-operative photographs and radiographs were also evaluated.

The preoperative management of open fractures involved stabilization of the patient, tetanus prophylaxis, and broad-spectrum antibiotics. Nonviable tissue required aggressive debridement. Serial debridement was needed if tissue viability was uncertain. When the wound bed was clean, flap coverage was done, within 72 to 96 hours following initial injury in our setup. However, in some cases we had to perform flap at later dates because of unstable patient or unfavorable wound. During preoperative physical examination our main focus is determining the function of the remaining muscles of the leg to predict loss of plantar flexor following gastrocnemius flap. During Vascular examination, we assessed for the patency of the popliteal artery and excluded the evidence of venous problems like DVT (deep venous thrombosis), though it was not an absolute contraindication in our series. In very few patients with a history of peripheral vascular disease or a history of popliteal arterial trauma, we requested for CT angiogram to confirm patency of the sural artery prior to surgery.

All the patients who were booked for flap surgery, underwent preoperative anesthesia assessment and accordingly received either general or spinal anesthesia. Patients were positioned in the prone position in almost all cases except in few cases we used supine position with the leg internally or externally rotated to facilitate exposure of the medial or lateral heads, respectively. Tourniquet was applied in all the patients. After sterile preparation, the entire extremity was draped and fully exposed. In almost all the cases we used Ipsilateral thigh for a skin graft donor site except in very rare cases where it was not available because of trauma. Appropriate preoperative antibiotics were given prior to incision.

The posterior dissection was generally done first through a posterior midline incision as the posterior anatomy was clear and very rarely damaged or obscured by the anterior trauma. Two key landmarks, the sural nerve and lesser saphenous vein seen superficial to the muscle bellies helped to locate the natural cleavage between the two muscle bellies. According to the requirement, the flap elevated and donor site grafted if required. A suction drain was placed at the donor site; this was a mandatory step in order to

obliterate the dead space created by the elevation of the flap. The drain was removed in couple of days however in one case we had to leave in place for 1 week. Above knee POP slab was applied for one week in every patient to avoid skin graft loss because of underlying muscle movements. Post operatively limb elevation 7 days to reduce pain and swelling. Flap monitoring done according to our unit protocol. Patients were discharged on 6th post-operative day. First follow up visit was one week after the discharge and then fortnightly. We encourage early mobilization of the ankle to avoid adhesions and stiffness along with gentle mobilization of the knee joint, after one week and full range of motion started within 4–6 weeks.

Results

Among 139 patients 105 (75.5%) were males and 34 (24.5%) females. Age range of the study population was between 18 years to 55 years with the mean age of 30.05 years. Size of the smallest wound was 3x3 cm and maximum was 20 x 9 cm. Regarding site of the presenting wound in this series most of the defects were on proximal tibia. The largest number of our flaps were either muscle or musculocutaneous medial GC flap. About 134 flaps survived. In 12% cases flap infection was found that was managed with antibiotics. We were able to cover almost 2/3rd of upper tibia with transposition of medial musculocutaneous flap. There was no significant functional donor-site morbidity during level and uphill gait after a gastrocnemius harvest. Few of our patients were dissatisfied of cosmetic outcome with a musculocutaneous flap that does not allow for primary closure of the donor site. Infection of either donor site, flap, recipient site was big complication in our study but it was easily encountered by antibiotics. In almost all cases staphylococcus aureus was the culprit organism. Early complication which may mimic venous thrombosis is a large hematoma in the posterior superficial compartment of the leg was absent in our series. One of our patient experienced persistence of a contraction of the flap at the recipient site, but it was not symptomatic and well managed by this patient. Clinical and demographic data analysis is given in table 1 & 2 and postoperative complications are given in table 3.

Gender	Male		Female
		105 (75.5 %)	
H/O any previous surgery	Yes		No
	12 (8.6%)		127(91.4%)
Age in years	Minimum Age	Maximum Age	Mean ±S.D
	18 Years	55 Years	30.05 ±10.325

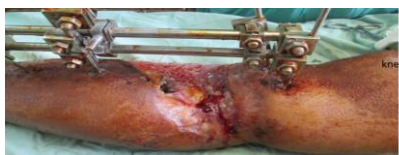

Figure 1a

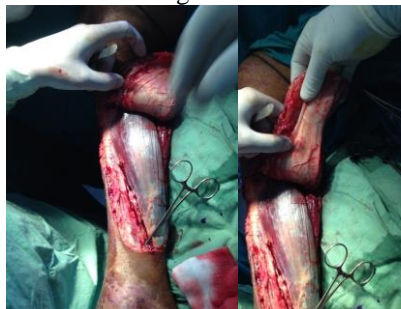


Figure 1b

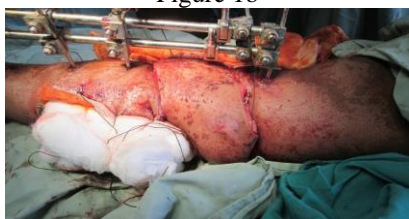

Figure 1c

Figure 1 (a, b, c): A 25-year-old man had wound involving upper third of tibia, medial musculocutaneous GC covered this huge area

Postoperative course	No (%)
No complication	117(84.2)
Flap Infection	11(7.91)
Hematoma	0(0)
Donor Site Infection	2(1.44)
Recipient Site Infection	6(4.32)
Venous congestion	0(0)
Wound dehiscence	1(0.7)
Superficial epidermolysis	2(1.4)

Discussion

Orthopedic surgeons seek help of Reconstructive surgeon to cover the exposed bones/joints, obliterate the dead space, help eradicate the infection of chronic osteomyelitis and prepare and vascularize the wound for subsequent bone grafting. Tibia on its anteromedial side is covered only by a thin layer of skin and subcutaneous tissue, making it vulnerable to high energy trauma that often results in open fractures and now a days its incidence is increasing in adults younger than 45 years of age.⁹⁻¹⁰ Open fractures mandate the need for coverage which enables the victims to ambulate early without bony complication. Prime goal of a plastic surgeon working in third world, where health care facilities are not very much up to standards, is to provide least complicated and highly reliable flap coverage to a person with open fractures. Microsurgical flaps although are ideal in most of that covers the defect successfully in a one-stage operation, however it requires a long operative time; experienced, skillful technique; and patent vascular status of the recipient site. Free flap transfer to the lower limb in chronic post-traumatic conditions is known to have a higher complication rate with flap loss in up to 10% of cases, mainly due to the recipient vessel. The dissection of these vessels often leads to refractory spasm, due to the so-called post-traumatic vessel disease (PTVD).¹¹⁻¹² Ger first described the use of gastrocnemius flap and after that the flap gained worldwide popularity.¹³⁻¹⁵ The gastrocnemius is the most superficial muscle of the posterior calf. The muscle has two heads arising from the medial and lateral condyles at the femur, and the adjacent capsule of the knee; these muscles then insert into the calcaneal tendon. Gastrocnemius muscle (medial and or lateral) is a Type I flap based on sural artery from the popliteal artery. The lateral head of the muscle, compared to the medial, is used more rarely in reconstructive surgery. The reasons for its restricted use are the size and the limited arc of rotation as well as the potential risk of peroneal nerve palsy of the muscle that might be caused by the surgical procedure itself.¹⁶ The medial head of the gastrocnemius muscle, which is the part mostly used, meets all the requirements needed for a successful wound coverage. Certainly there are

Causes of Defects	Road Traffic Accident	Fall	Sports & Recreational Activities	
	119(85.6%)	14(10.1%)	6(4.3%)	
Defect Extent & Dimensions	>10 x 5 cm	>15x7cm	>20 x 9.5cm	
	86(61.9%)	40(28.8%)	12(8.6)	
Time Of Flap coverage Since Injury	72-96	3-7days	7-21days	
	60(43.16%)	47(33.8%)	32(23%)	
Site of defect	Upper Tibia Isolation	Knee Isolation	Complex Wound involving more than one area	
	96(69.06%)	40(28.77%)	3(2.16%)	
Type of Flap	Medical GC Muscle	Medical GC Musculocutaneous	Lateral GC Muscle	Lateral GC Musculocutaneous
	64(46.04%)	51(36.69%)	12(8.6%)	12(8.6%)
Flap Survival	Complete Survival	Partial Necrosis	Marginal Necrosis	
	134(96.4%)	1(0.7%)	4(2.87%)	
Bone Exposure	Bone /Or Joint Exposed		No Bone Exposure	
	124(89.21%)		15(10.79%)	
POSTOPERATIVE PALSY OF THE PERONEAL NERVE (1 case in total of 24 lateral gastrocnemius flaps)				

cases, when the application of the lateral head is preferred and that happens in cases of wounds in the proximal part of the tibia and the lateral surface of the knee. However, there are disadvantages associated with the application of the gastrocnemius flap such as deformation of the donor area. This study shows proportion of gender close to the distribution of gender in other studies.¹⁶ However, unlike these studies we did not use the cross leg gastrocnemius muscle flap because of difficulties in postoperative immobilization and its attendant morbidity and in these cases where ipsilateral gastrocnemius muscle is not suitable for transfer, we used free flap coverage of the defect. We also provided excellent soft-tissue coverage of exposed or infected hard ware. GC muscle flap was the good local choice to cover them. Regarding indications for flap coverage, exposure of the underlying bone is a major reason as skin grafting are not fruitful and are contraindicated in these situations. Effectiveness of a flap is judged by various factors and survival of the flap is a major determinant of success of the procedure. In this study, complete survival rate of the flap was very high, partial necrosis and marginal necrosis in very few cases. Statistically these results are better when compared to other studies, and complications in their study were mainly technical error, inadequate debridement, use of diseased and traumatized muscle and unrealistic objectives.¹⁸⁻²¹ In our cases fewer complications were because of careful preoperative evaluation and surgical planning. We were able to cover up to upper 2/3rd of tibia by only musculocutaneous flap. We experienced that with simple transposition or rotation of musculocutaneous GC flap, a large number of defects (up to half of tibia) can be addressed. Except in one case where peroneal nerve damaged rest of flap, elevation and handling is easy to learn and execute. It is very interesting that despite of its superficial location we found that even in comminuted fractures this muscle was useable. In one case we experienced difficulty in elevation of medial head as almost half was fibrosed & this was speculated that compartment syndrome may be the reason in this case which was treated little later. In our study one case had partial necrosis in a musculocutaneous flap, we think that this was because of handling of flap and tight bandage.

Conclusion

Gastrocnemius flap is still one of the best available commodity to cover problem wounds in upper leg and knee wounds. Due to its technical ease, low complication rate, easy learning curve, and low donor area morbidity, it is one of the best choices. We suggest that indications of musculocutaneous flap should be revised as this can be used up to upper 2/3rd of tibia. Even in extensive complicated trauma it is useable. Its harvest does not involve sacrifice of major blood vessel and has no or little effect on gait.

Conflict of Interest

This study has no conflict of interest as declared by any author.

References

1. Court-Brown CM, Caesar B. Epidemiology of adult fractures: a review. *Inj.* 2006;37(8):691–7.
2. Lindvall E, Sanders R, DiPasquale T, Herscovici D, Haidukewych G, Sagi C. Intramedullary nailing versus percutaneous locked plating of extra-articular proximal tibial fractures: comparison of 56 cases. *J Orthop Trauma.* 2009;23(7):485–92.
3. Casanova, Olivier Hulard, Rémy Zalta, Jacques Bardot, Guy-Magalon D. Management of wounds of exposed or infected knee prostheses. *Scand J Plast Reconstr Surg Hand Surg.* 2001;35(1):71–7.
4. Charlson M, Szatrowski TP, Peterson J, Gold J. Validation of a combined comorbidity index. *J Clin Epidemiol.* 1994;47(11):1245–51.
5. Conway JD, Mont MA, Bezwada HP. Arthrodesis of the knee. *J Bone Joint Surg Am.* 2004; 86-A(4):835–48.
6. Corten K, Struelens B, Evans B, Graham E, Bourne RB, MacDonald SJ. Gastrocnemius flap reconstruction of soft-tissue defects following infected total knee replacement. *Bone Joint J.* 2013; =95-B(9):1217–21.
7. Galat DD, McGovern SC, Larson DR, Harrington JR, Hanssen AD, Clarke HD. Surgical treatment of early wound complications following primary total knee arthroplasty. *J Bone Joint Surg Am.* 2009;91(1):48–54.
8. Parrett BM, Matros E, Pribaz JJ, Orgill DP. Lower extremity trauma: trends in the management of soft-tissue reconstruction of open tibia-fibula fractures. *Plast Reconstr Surg.* 2006;117(4):1315–22.
9. Kumar AR. Standard wound coverage techniques for extremity war injury. *J Am Acad Orthop Surg.* 2006;14(10):S62–5.
10. Hallock GG. Getting the most from the soleus muscle. *Ann Plastic Surg.* 1996;36(2):139–46.
11. Parrett BM, Matros E, Pribaz JJ, Orgill DP. Lower extremity trauma: trends in the management of soft-tissue reconstruction of open tibia-fibula fractures. *Plast Reconstr Surg.* 2006;117(4):1315–22.
12. Godina M. Early microsurgical reconstruction of complex trauma of the extremities. *Orthop Trauma Direct.* 2006;4(05):29–35.
13. Hohmann E, Wansbrough G, Senewiratne S. Medial gastrocnemius flap for reconstruction of the extensor mechanism of the knee following high-energy trauma: a minimum 5 year follow-up. *Inj.* 2016;47(8):1750–5.
14. Mathes SJ, Nahai F. Clinical applications for muscle and musculocutaneous flaps. New York; CV Mosby Company Publishers. 1982.
15. Sanger JR, Kao DS, Hackbarth DA. Peroneal nerve compression by lateral gastrocnemius flap. *J Plast Reconstr Aesthet Surg.* 2009;62(8):280–2.
16. Smith DJ Jr, Loewenstein PW, Bennett JE. Surgical options in the repair of lower-extremity soft-tissue wounds. *J Trauma.* 2010;22(5):374–80.
17. Salibian AH, Meniak FJ. Bipedicule gastrocnemius musculocutaneous flap for defects of the distal one third of the leg. *Plast Reconstr Surg.* 1982;70(1):17–23.
18. Salibian AH, Rogers FR, Lamb RC. Microvascular gastrocnemius muscle transfer to the distal leg using

- saphenous vein grafts. *Plastic and reconstructive surgery.* 1984;73(2):302-7.
19. El-Sherbiny M. Pedicled gastrocnemius flap: clinical application in limb sparing surgical resection of sarcoma around the knee region and popliteal fossa. *J Egypt Natl Canc Inst.* 2008;20(2):196-207.
20. Busfield BT, Huffman GR, Nahai F, Hoffman W, Ries MD. Extended medial gastrocnemius rotational flap for treatment of chronic knee extensor mechanism deficiency in patients with and without total knee arthroplasty. *Clin Orthop Relat Res.* 2004;428:190-7.
21. Patnaik S, Nayak B, Mishra L, Sahoo AK. Complex primary total knee replacement (tkr) using prophylactic gastrocnemius flap and rotating-hinge knee in post-traumatic, infective arthritis of the knee: a case report. *J Orthop Case Rep.* 2015;5(4):40-3.

Authorship Contribution:

Author 1: Concept and Planning of research and final review of the article

Author 2: Interpretation, analysis and discussion

Author 3: Active participation in research