

Management of Esophageal Foreign Bodies, retrospective study.

Mohammed H. Nemat*
Abdulameer M.Hussein**
Uday H.Juma***

MBChB, FIBMS
MBChB, FICMS
MBChB, FIBMS

Summary:

Background: Foreign body impaction in the esophagus is a common problem. Our Objective is to draw conclusions from a retrospective over viewing a number of cases to assess current methods of management and to come out with recommendation from collected experience.

Patient and method: A retrospective study of (62) patients admitted to the Department of Thoracic and Cardiovascular Surgery at Medical City Teaching Hospital from January 2002 to December 2004 with history of foreign body swallowing and impaction. Six patients excluded from the (62) patients after having negative esophgoscopic findings. On presentation, history about type and time of ingestion, associated signs and symptoms were recorded, x- ray was taken. Rigid esophagoscopy or direct laryngoscopy and Magill forceps has been used. After the procedure completion, type and site of the foreign body and state of esophageal mucosa at the site of impaction were recorded. Chest X-ray done postoperatively in certain patients when we had peroperative findings of bleeding, suspicion of perforation. All patients except 2 were discharged within 24 hours after the procedure.

Results: The results showed that the commonest age group was among children between 1-10 years (27) patients, and 77% of the patients presented with dysphagia as the most common presenting symptom, site of impaction mostly in upper third of esophagus 68%, and 68% of the FB were radiopaque. Types of the FB were versatile but 50% of them were metallic objects.

Conclusion: Esophageal FB is a common problem especially among children; it requires urgent intervention because of its deleterious complications if left untreated. Suspicion is enough indication especially in children. Management requires good experience in using the appropriate tools like Magill forceps, which is safe and quick in good hands.

Keywords: Foreign body, esophagus

Fac Med
Baghdad

2011; Vol. 53, No1
Received Jan. 2010

Introduction:

Foreign body impaction in the esophagus is a common problem that faces the thoracic surgeons. In the pre-endoscopic era, foreign bodies were left to pass through the GIT and if they get impacted somewhere, then surgery was the solution. Now almost all of the foreign bodies can be removed endoscopically, mostly via rigid esophagoscope and forceps. Fortunately 80-90% of swallowed foreign bodies will pass spontaneously and in many instances may go unrecognized especially in children. About 10-20% of swallowed foreign bodies will have to be removed endoscopically, and less than 1% will need to be removed surgically. (1)

Patient and method:

A retrospective study of (62) patients admitted to the Department of Thoracic and Cardiovascular Surgery at Medical City Teaching Hospital from January 2002 to December 2004 with history of

foreign body swallowing and impaction. Six patients excluded from the (62) patients after having negative esophgoscopic findings. On presentation, history was taken about type and time of ingestion, associated signs and symptoms were recorded, x- ray was taken to all of them. Rigid esophagoscopy was done to 37 patients, direct laryngoscopy and Magill forceps to 19 patients, both done under general anesthesia. Other modalities of intervention (Flexible esophagoscopy, bougienage, Foley catheter and temporization) had not been used because we are not familiar with their safety and efficacy. All patients were fasting for not less than 4 hours from the time of the last meal. After the procedure completion, type and site of the foreign body and state of esophageal mucosa at the site of impaction were recorded. Chest X-ray was done postoperatively in certain patients when we had peroperative sinister findings of bleeding, suspicion of perforation or when the patients presented with fever and this was done in 14 patients. All patients except 2 were discharged within 24 hours after the procedure

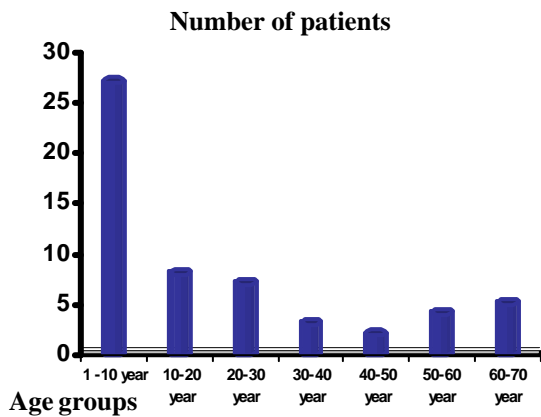
*Specialist cardiothoracic surgeon, Iraqi Center for Heart Diseases.

**Dept. of surgery, college of Medicine, University of Baghdad

***Specialist cardiothoracic surgeon, Iraqi Center for Heart Diseases.

Results:

The age of patients:



(Fig.1) Age distribution of patients with esophageal foreign body impaction

Site of impaction: Majority of the foreign bodies were impacted in the upper 1/3 of the esophagus (just below the cricopharyngeal muscle) 68% (39 patient), and the second most common site was the middle 1/3 (where the aortic arch crosses the esophagus) 20% (11 patient). While the least number recorded was in the distal 1/3 (lower esophageal sphincter) 12% (6patient).

Radiological findings

Radiopaque objects were detected in 68% of the patients (38 patient), while the CXR was negative in 32% (16 patient).

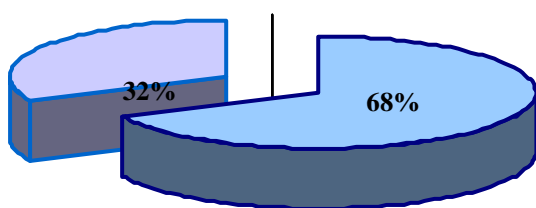


Fig4: Radiological findings

Table 1: Presenting symptoms:

symptoms	No. of Patients	percentage
Dysphagia	43 patient	77%
Vomiting and Gagging	25 patient	45%
Drooling	20 patient	36%
Dyspnoea	20 patient	36%
Chest pain and Cough	15 patient	27%

Table 2: Types of foreign body

	Types of foreign bodies	No. Of Patients	percentage
1-	Metallic objects (coins, pins, earrings,...)	28 patient	50%
2-	Bones	15 patient	27%
3-	Food bolus	7 patient	13%
4-	Dentures	2 patient	3%
5-	Others	4 patient	6%

Treatment and Complications: The (56 patient) have been subjected to intervention for the removal of their impacted esophageal foreign bodies. Thirty seven patient treated by rigid esophagoscopy and grasping forceps, (19) patients treated by Magill forceps and laryngoscope, all of them were done under general anesthesia, but those in whom Magill forceps and laryngoscope were used, mask inhalational anesthesia was used. Almost all of the cases had smooth uneventful intervention apart from two of the patients. One of them developed bleeding during extraction of a swollen razor (suicidal attempt), in which the patient kept on nothing by mouth, i.v fluid, systemic antibiotic and monitoring clinically and radiologically in which Barium swallow was done to him after two days and it was negative. The other patient had swallowed a denture and he had CVA. He presented to us, after few days from successful retrieval of his esophageal foreign body, with fever, and cervical X-ray showed a collection which was proved to be an abscess and it was due to missed perforation by the sharp wires of the dentures, and he was managed conservatively by keeping him on nothing by mouth and systemic antibiotic. One patient had two coins were impacted at the same site, while they were looking as one in the PA view of CXR. Another patient had food bolus were retrieved from two sites in the esophagus, and this was discovered during the checking of the esophagus after retrieving the first bolus which was impacted at the level of upper esophageal sphincter.

Discussion:

Foreign body ingestion is common in children between 3 months to 12 years, with median age of 38 month. The child's normal developmental milestones of using the hand to take an object and to grasp with a pinching motion are seen at six month and seven months of age respectively, with a male to female ratio of 3:2. This result is recorded in other studies and consistent with our present study (2, 3). The presence of symptoms is significantly associated with esophageal foreign bodies, but the absence of symptoms does not reliably exclude the possibility of an esophageal foreign body where a patient may have a foreign body lodged in the esophagus and be completely asymptomatic, for these reason radiological studies can be beneficial in the management of suspected foreign body ingestions (4), and a study have shown that 38% - 49% of patients with witnessed or subsequently documented foreign body ingestion showed no

symptoms at all (5). The problem of awareness to foreign body ingestion is seen mostly in non verbal patient (infants, patients with mental retardation) in whom the witness or care taker observations are important. This type of patients are whom usually who could present as a case of chronic esophageal foreign body impaction and complication (6). Common signs and symptom in patients with a foreign body that has been retained for less than 24hours tend to be gastrointestinal and include dysphagia, drooling, vomiting, gagging and anorexia. Significant respiratory symptoms such as coughing, chest pain, stridor, hemoptysis and chronic upper respiratory tract infection are more common weeks or months after ingestion (7). Most of our patients presented with gastrointestinal symptoms (77% Dysphagia, 45% Vomiting, 36% Drooling), because most of them presented within 24 hours of ingestion. Types of the foreign bodies ingested by the patient were versatile but the most common type was metallic objects 50% including (pins, coins, earrings, etc), also small plastic objects, this is because types of foreign bodies ingested have a big relation with the age of the patient, and since most of the victims are from the pediatric age group it is those types of foreign bodies which attract them. While the other types of foreign bodies which were found in older age groups were bones (27%), food bolus (13%) or dentures (3%). However, all types of foreign bodies could be found in any age group, but the frequency of the type is very much age related. (8) Along with similar studies (1,7,8,9) about esophageal foreign bodies have shown that coins were the most common reported foreign body, in our study still metallic objects counts for the majority of cases regardless whether they are coins or other metallic objects compared to a similar study conducted in our department but from 1999-2002 where the most common ingested foreign body was food bolus ,may be because at that era the coins were scarce in the country and were not available to the hand of children(2). Site of foreign body impaction in the esophagus was consistent with the results of other similar studies (1, 2, 7, 8, and 9) where the most common site was at the lower border of cricopharyngeal muscle (68%), and this is expected anatomically because the upper esophageal sphincter is the first narrowing which faces the ingested foreign body (10). Next common site is the middle esophagus (20%) while the lower third only holds (12%) of the ingested foreign body. The site of impaction also could be influenced by preexisting esophageal pathology (esophageal web, tumor, enlarged left atrium, achalasia, etc) (2). The benefits of obtaining x-ray on a patient with known or suspected foreign body ingestion are well described , where it not only shows the radiopaque objects and its site but also it could show the complication of the foreign body such as pneumothorax, subcutaneous emphysema, lung abscess, atelectasis, or free peritoneal air (4). An important role of x-ray especially in radiopaque objects is that it can help to determine if there is more than one foreign body

ingested. Also repeating x-rays can help to determine if the foreign body has been swollen down to the stomach if the patient was observed for a period of time rather than having the foreign body removed immediately. An important point to remember is that the patient still can have esophageal foreign body despite a normal x-ray and asymptomatic patient (5). In our study 68% of the patient had the positive x-ray findings and this can be explained by the type of the foreign body ingested in which 50% of them were metallic and 27% were bones. The method of intervention used in our study was either rigid esophagoscopy and forceps under general anesthesia with endotracheal intubation in (60%), or laryngoscope and Magill forceps under general anesthesia without using endotracheal intubation in (40%). Similar studies (2,7,8,9) showed using rigid esophagoscopy in (85.7 %) while flexible esophagoscopy used in (14%), whereas flexible esophagoscopy was not used in our study, this is because flexible esophagoscopy is not available in our department and the training program here doesn't involve using flexible esophagoscopy in esophageal foreign body retrieval. There are other methods of esophageal foreign body extraction (bougienage, Foley catheter, temporization) (11,12),but we did not use any of them because with the long accumulating experience in this department with the esophageal foreign body they found that rigid esophagoscopy safer, more reliable and fruitful technique for removal of all types of foreign bodies with very high success rate. Magill forceps and laryngoscope is a very successful method in extracting foreign bodies (13) when they are located at or just below upper esophageal sphincter and the foreign body is without sharp pointing edges so that it's extraction can be smooth and rapid remembering that the patient is not intubated, and it should be done in skilled hands with the endotracheal tube stand by (14). No one of our patients required surgery for the extraction of his foreign body compared to other studies where 1.66% and 2% required surgery (2, 6). May be this is because the more cases are collected the more difficult and rare cases will appear. Only one of our patient developed cervical abscess following extraction of denture which has been treated by systemic antibiotics, nothing by mouth and iv fluid.

Conclusion:

Children below ten years were the commonest age group affected by esophageal foreign body impaction.

Symptomatology is important in the presentation, however, absence of symptoms does not exclude impaction and positive history is enough indication to do esophagoscopic examination.

Upper third of esophagus was the commonest site of foreign body impaction, so using Magill forceps and laryngoscope is a justifiable safe and effective method in removing upper esophageal foreign bodies minimizing the need for muscle relaxant and endotracheal intubation in selected cases.

Radiopaque foreign bodies constitute majority of cases (68%) ,but almost one third were radiolucent, giving the justification for doing esophgoscopic examination based on history and Symptomatology. Rigid esophagoscopy was the method of choice for the removal of impacted foreign bodies.

Esophageal perforation is the most feared complication caused either primarily by the foreign body or iatrogenically during its removal.

Esophageal foreign body could present or turn to an emergency and it must be dealt with as such.

Esophageal foreign body impaction may be due to underlying esophageal pathology.

References:

1. Webb WA. Management of foreign bodies of the upper gastrointestinal tract. *Gastroenterology* 1988; 94: 204-16.
2. Hussien, W.M.,: Esophageal foreign bodies. *J Fac Med Baghdad*, 2009, Vol.51, No.3:232-235.
3. Chen MK, Beierle EA. Gastrointestinal foreign bodies. *Pediatr Ann* 2001; 30: 736-742
4. Hodge D, Tecklenburg F, Fleisher G. Coin ingestion: Does every child need a radiograph? *Ann of Emerg Med* 1985; 14:443-446.
5. Bailey P. Pediatric esophageal foreign body with minimal symptomatology. *Ann Emerg Med* 1983; 12: 452-454.
6. Humphries CT, Wagener JS, Morgan WJ. Fatal prolonged foreign body aspiration following an asymptomatic interval. *Am J Emerg Med* 1988;6:611-613.
7. Gaasch W, Barish R. Swallowed Foreign Bodies. In: Tintinalli JE, et al, eds. *Emergency Medicine – A Comprehensive Study Guide*. 3rd edition, New York: McGraw Hill;1992:310-312
8. Taylor RB. Esophageal foreign bodies. *Emerg Med Clin North Am* 1987;5:301-311
9. Henderson CT, Engel J, Schlesinger P. Foreign body ingestion; review and suggested guidelines for management. *Endoscopy* 1987; 19: 69-71.
10. Williams P. L., Warwick R. Anatomy of the esophagus. *Grays Anatomy*. 36th Edition, Churchill Livingstone 1980; 1316-1317.
11. Campbell JB, Quattromani FL, Foley LC. Foley catheter removal of blunt esophageal foreign bodies: Experience with 100 consecutive children. *Pediatr Radio*, 1983; 13:116-119.
12. Campbell JB, Condon VR. Catheter removal of blunt esophageal foreign bodies in children: Survey of the Society for Pediatric Radiology. *PediatrRadio*, 1989; 19:361-365.
13. Mahafza TM: Extracting coins from the upper end of the esophagus using a Magill forceps technique. *IntJ Pediatr Otorhinolaryngol*, 2002 Jan 11; 62(1): 37-9[Medline].
14. Karaman A, Cavusoglu YH, Karaman I, et al: Magill forceps technique for removal of upper esophagus: a preliminary report. *Int J Pediatr Otorhinolaryngol*, 2004 Sep; 68(9)[Medline].