

## Surgery in Varicose Veins

Hassanein A. Hussein\*  
Waleed M. Hussen\*\*

MBCbB, FIBMS (ThCVS)  
MRCS, FRCS, FACS, MS, FIBMS (ThCVS)

### Summary:

**Background:** Varicose veins are common in Iraq. Increasing incidence is associated with available jobs of bodyguards, barbers and computer workers.

**Objectives:** To highlight the frequency, presentation, methods of accurate diagnosis and surgical procedures which are commonly used by Vascular Surgeons in Medical City Teaching Complex, Al-Shaheed Ghazi Al-Hariri Subspecialties hospital and to compare this study with other international studies.

**Patients and methods:** This is a retrospective study of hundred patients with varicose veins, who were admitted and surgically treated at Al-Shaheed Ghazi Al-Hariri subspecialties hospital during one year period (1st of July 2010 to the 30th of June 2011). It illustrates the technique used and presents the surgical complications met with in these cases.

**Results:** Most of the patients were males (67%). Most of them were bodyguards or computer workers. In eight patients only surgical complications are met and dealt with.

**Conclusions:** We are in utmost need for newer methods of treating varicose veins such as Endovenous laser treatment or radiofrequency ablation, and also in need for a well trained personnel and the essential equipments to implicate this.

**Key Words:** Deep veins, venous valves, Stripping, Laser.

*Fac Med Baghdad*  
2013; Vol.55, No. 4  
Received: Sept., 2013  
Accepted Nov. 2013

### Introduction:

Varicose veins are veins that have become enlarged and tortuous. The term commonly refers to the veins on the leg, although varicose veins can occur elsewhere.[1] The word "varicose" is an old one. The origin of the word comes from the Greek "grapelike". It was probably first used as a medical description by Hippocrates in 460 BC.[1] Varicose veins were first described in the Ebers papyrus over 3500 years ago. This ancient Egyptian work described 'serpentine windings' which were not to be operated on because the patients would be 'head to the ground'[1]The Hippocratic Treatises, written in 460 BC, took treatment one step further, he prescribed compression following multiple punctures. [1]

Most famous physician and surgeon of the era was 'Abu al-Qasim Khalaf ibn al-Abbas Alzahrawi' known to the west as Albucasis (930 AD to 1013 AD).[1] His description of varicose veins stripping, even after ten centuries, is almost like modern surgery ".

The advent of anaesthesia and antiseptic surgery advanced the treatment of varicose veins with great pace. Friedrich Trendelenburg (1841-1891), perhaps one of the most well known venous surgeons, popularized mid-thigh ligation of the GSV.

Several new approaches to stripping the greater saphenous vein were introduced in the first few years of the 20th century. The Mayo stripper is an extra luminal ring that cuts the tributaries as it passes along the vein. The Babcock device is an intraluminal stripper with an acorn-shaped head that pleats

up the vein as it pulls the vessel loose from its attachments. A number of techniques including Endovenous obliteration with radiofrequency(2,3) cry stripping [4]; endovenous laser obliteration (5) , angioscopic techniques[6], transposition of a competent tributary vein [7] and echosclerotherapy using a sclerosant foam [8 ,9], have been proposed to minimize the trauma of surgical treatment or to spare the LSV for possible future artery bypass grafting.

Female sex, pregnancy, geographical site and race are risk factors for varicose veins.[10] Other factors such as high body mass index, poor health status, haemorrhoids and some professional categories may be also important factors in their presentation.[11] Less commonly, but not exceptionally, varicose veins can be due to other causes, as post phlebotic obstruction and/or incontinence, venous and arteriovenous malformations.[12]

Varicose veins (VVs) classically result from venous hypertension owing to incompetence of the major communications between the superficial and deep veins of the lower extremity. In a significant number of patients, there is no demonstrable saphenous reflux and varicosities are the result of isolated perforating and non-saphenous vein incompetence. [13].

### Patients & methods

This is a retrospective study of hundred patients with varicose veins, who were admitted and surgically treated at Al-Shaheed Ghazi Al-Hariri subspecialties hospital during one year period from 1st of July 2010 to the 30th of June 2011. The data were collected from the patients'

\* Dept. of Thoracic and Vascular Surgery, Medical city teaching Hospital.

\*\* Dept of Surgery, College of Medicine, University of Baghdad.

case sheets and theatre records. Analysis of the data was made by further taking information depending on history, physical examination and different investigations (duplex scanning, abdominal US, etc...). All patients, after a full preoperative preparation underwent surgery under general, spinal or epidural anaesthesia, during which the incompetent veins were stripped from their junction with the deep veins down in a retrograde fashion. Perforator veins were avulsed. Haemostasis secured. The affected limb then wrapped in compression bandage for 24-48 hours. Postoperatively these patients were transferred to the surgical ward and stayed there for three to five days. Antibiotic cover is used as a single dose of cephalosporin 1gm i.v at induction as it is regarded as a clean operation and this cover maintained during his/her stay in the hospital and to be changed to single oral antibiotic on discharge from the hospital until stitches were removed on 7th – 8th postoperative days. These patients were followed up in our consultation clinic, on outpatient basis.

#### Special formula

A special formula was used to divide the patients as regard their sex, age, presenting clinical features, affected side (limb), preoperative investigations, type of anesthesia, details of surgery and per and postoperative complications.

#### Results:

Hundred patients with varicose veins, operated upon during one year period from 1st of July 2010 to the 30th of June 2011. Of them, sixty seven were male (67%) and thirty three were female (33%).

The youngest patient was seventeen years old male and the oldest patient was sixty five years old male. The majority of patients were in the 4th decade of life (30 – 39) years. The distribution of our patient as regard their age is shown on figure (1).

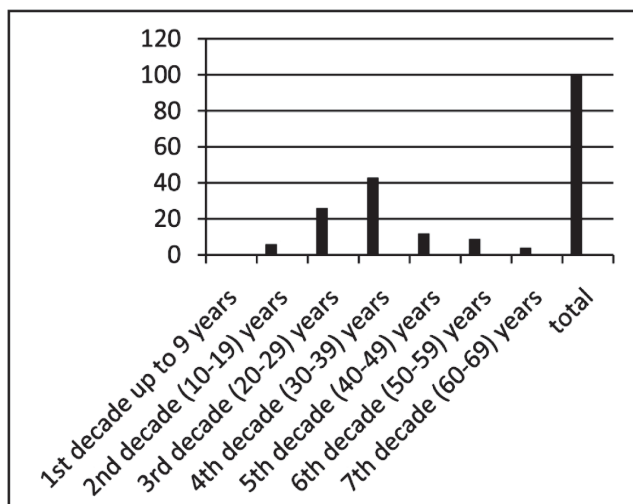


Figure 1: Age distribution of study patients

Seventy two of our patients presented with painful visible veins, but twenty four patients presented with painless visible

veins, while twelve patients complaining from itching. Sixteen patients complaining from swelling and only five patients were presented with ulceration and discoloration, twenty nine patients presented with more than one sign and symptom. The distribution of patients as regard their presenting signs and symptoms is shown in table (1).

Table 1: Clinical presentations of the study patients

The signs and symptoms	No. of cases	%
Painful visible veins	72	72 %
Visible veins	24	24%
Itching	12	12 %
Swelling	16	16 %
Ulceration & discoloration	5	5 %

Left lower limb is affected in forty nine patients (49%), while the right lower limb is affected in forty two patients (42%). Only nine of our patients presented with bilateral varicose veins. The distribution of limb affection is shown in figure 2.

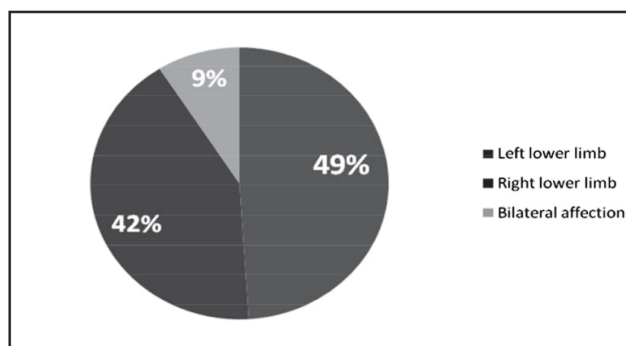


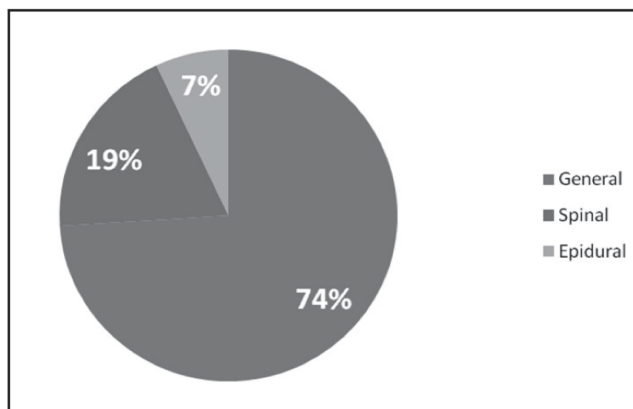
Figure 2: Distribution of the study group by limb affection

Doppler study was done for all the patients. It showed that sixty-four patients (64%) have incompetent saphenofemoral junction, while in ten patients (10%) an incompetent saphenopopliteal junction was demonstrated. In the rest of our patients (26patients) no incompetent saphenofemoral and saphenopopliteal junctions were demonstrated but multiple perforators above and below the knee were evident. In all patients the deep veins were patent. The distribution of patients as regard Doppler findings is shown in table 2.

Table 2: Doppler findings in the study patients

Doppler findings	No. of patients	%
Incompetent saphenofemoral junction	64	64%
Incompetent saphenopopliteal junction	10	10%
Competent saphenofemoral and saphenopopliteal junctions (multiple perforators above and below knee)	26	26%
Total	100	100%

Surgery was conducted under general anaesthesia in 74 patients. Spinal anaesthesia was used in 19 patients. In the remaining 7 patients with varicose veins the surgery was conducted under epidural anaesthesia, and the distribution of patients as regard type of anaesthesia used is shown in figure 3.



**Figure 3: Type of anaesthesia used**

Stripping and multiple ligation was the surgery of choice in seventy four patients (74%), Of them, sixty four patients stripping was done at saphenofemoral junction, while in the remaining ten patients stripping was done at saphenopopliteal junction. Multiple ligations were done for twenty six patients (26%). The distribution of patients as regard the type of surgery is shown in table 3.

**Table 3: Type of surgery conducted on the study patients**

Type of surgery	No. of patients	%
Stripping at saphenofemoral junction & multiple ligation	64	64%
Stripping at saphenopopliteal junction & multiple ligation	10	10%
Multiple ligation only	26	26%
<b>Total</b>	<b>100</b>	<b>100%</b>

Per operative course was smooth and uneventful and all of our patients recovered smoothly. Postoperatively eight of our patients develop some complications like parasthesia which occur in four patients (4%) which was transient and recovered after one week. Bleeding occur in three patients (3%) which controlled by compression and not necessitated surgical intervention, wound infection occur in only one patient (1%) which responded to change of antibiotics and daily dressing. Deep vein thrombosis and pulmonary embolism did not occur in our patients. No single mortality. The distribution of the complications is shown in table 4.

**Table 4: Postoperative complications among the study patients**

The complication	No. of patients	%
Parasthesia	4	4%
Bleeding	3	3%
Wound infection	1	1%
Deep vein thrombosis	0	0%
Pulmonary embolism	0	0%
<b>Total</b>	<b>8</b>	<b>8%</b>

#### Discussion:

Varicose veins are common in our country. It is commonly stated to be responsible for a wide range of lower limb symptoms such as heaviness, swelling, aching, restless legs, cramps and itching. [14, 15]

Most of our patients were male (67%). The most common predisposing factor is prolonged standing and that was common in our male patient working as policemen or bodyguard whom their work entailed prolonged standing which lead to stagnation of blood in the lower limb, increasing venous pressure and venous engorgement and reflux of blood into superficial veins leading to varicosities, and these results are in agree with Edinburgh vein study in a cohort of 1566 patients, males were more than females, but it is disagree with another study done by Brand FN et al, were the most affected patients were females. [16]. Recent surveys have suggested that the occurrence in men may be comparable to that in women. [17]

San Valentino Vascular Screening Project stated that varicose veins are more common with increasing age. The increase with age is linear, there was no important difference between males and females. [18]

The youngest patient was seventeen years old male and the oldest patient was sixty five years old male. The majority of our patients fall in the fourth decade of life. Most of our patients were spending eight to twelve hours in an average day in sedentary activities (sitting or standing) like bodyguards or policeman or people working in offices spending their time working on computers, and this is agree with a study done by Brand FN. [19]

Cesarone M. R. et al stressed upon varicose veins incidence increase with age rather than distributing patients according to their age, and one of the studies conducted in Finland stated that the incidence of varicose veins was significantly higher at the age 50 – 55 years. [20]

Seventy two of our patients presented with painful visible veins, while twenty four patients presented with only visible veins, and this is in agree with Labropoulos et al study who found that 70% of patients with long saphenous vein reflux, complained of aching legs [21], while French patients with venous disorders of the legs are presented more with sensations of heaviness, swelling, or restlessness in the legs, abnormally felt in usual daily living. [22]

Left lower limb is affected in forty nine patients (49%), while right lower limb is affected to a lesser extent (i.e.) in forty two patients (42%), Bilateral affections seen only in

nine patients. This is in agreement with a study done in France by Patrick H. Carpenier in which the left lower limb is affected more than the right lower limb [22], but disagrees with other study done by Mark H. Meissner et al in which there is no difference in the affection between the right and left lower limbs. [23].

Duplex scanning for the varicose veins, it consists of three methods of investigations, B – mode ultrasound, pulsed duplex and color duplex scanning. It showed that the majority of our patients (64%) have incompetent saphenofemoral junction and in only ten patients (10%) the Doppler findings were incompetent saphenopopliteal junction. In the remaining twenty six patients (26%), no incompetent junctions but multiple perforators above and below the knee were demonstrated. All patients have no DVT and all superficial and deep veins were patent. Duplex scanning has become the “gold standard” for diagnosis of varicose veins. It is the main diagnostic tool in the preoperative diagnosis of varicose veins, confirming the clinical diagnosis in our cases and this is in agreement with other studies. [24,25].

In most of our patients (74%) surgery was conducted under general anaesthesia. In the remaining patients (26%) the surgery was conducted under either spinal or epidural anaesthesia. Most of the centres used general anaesthesia. However a comparative study of local versus general anaesthesia for varicose veins surgery conducted by M L Wall, et al [26] conducted varicose vein surgery using general anaesthesia in 26 patients and local anaesthesia in 72 patients over three years (April 2004 – March 2006) concluded that surgical treatment of varicose veins under local anaesthesia can be performed safely with comparable results to general anaesthesia in self – selected patients.

Epidural block provide a good alternative to general anaesthesia. [27] However severe complications associated with epidural and spinal anaesthesia were reported in Finland like cardiac arrest, paraplegia and neurological deficit. [28] Surgery was done in symptomatic patients. Conservative treatments were given only during the waiting period until the day of surgery, in the form of elevating the legs to provide temporary symptomatic relief, advice about regular exercise or wearing of compression stockings. The use of Diosmin or other flavonoid has resulted in decreasing oedema due to decrease transudation of fluid into the extracellular space, often gives symptomatic relief.

Stripping and multiple ligation was done for seventy four patients (74%), in sixty four patients stripping was done at saphenofemoral junction, while in ten patients stripping was done at saphenopopliteal junction. Only multiple ligation or avulsion was done for twenty six patients (26%). This is agreed with other study which showed that stripping of the incompetent saphenous trunks is widely considered to be the most appropriate management of varicose veins and chronic venous diseases. [29].

The newer methods for treating varicose veins such as endovenous Thermal ablation (Endovenous laser treatment or

radiofrequency ablation) and foam sclerotherapy [30,31] are not in use in our hospitals as all the equipments and trained personnel are not available. However all treatments were efficacious. The technical failure rate was highest after foam sclerotherapy, but both radiofrequency ablation and foam were associated with a faster recovery and less postoperative pain than endovenous laser ablation and stripping. [32]

Postoperative course was smooth and uneventful and all of our patients recovered smoothly with no operative complications. However Critchley G et al reported a major vascular injury, the common femoral vein being damaged in a patient undergo surgery, vein patch repair was performed and patency was maintained. [33].

Postoperative complications like parasthesia which occurred in four patients (4%), was transient and recovered after one week, bleeding occur in three patients (3%) which controlled by compression and not necessitated surgical intervention. Wound infection occurred in only one patient (1%) which responded to frequent change of dressing and changing of the antibiotics (all regarded as minor complications), which also was reported in other studies. [34,35]. Postoperative DVT which is reported by A. M Van Rij et al is not seen in our patients. [34].

Pulmonary embolism following varicose vein surgery which is reported by Critchley G et al. [33], Kazuhiro Nagasaki et al. [36] is not encountered in our study.

Mortality which is reported as a sequence of pulmonary embolism was not reported in our patients. The mortality rate following vein ligation and stripping has been reported to be 1 in 30000 in encyclopedia of surgery. [36]

Recurrence rate which is reported to be 15% to 30% in the literature done by Darke SG is not seen in our cases during this short follow up period. [37].

#### Conclusions:

Varicose veins are still common in Iraq. Most of our patients were males, engaged in duties requiring long hours standing or sitting. Affected females are mostly multiparous, obese women. - Duplex scanning became the gold standard test for the diagnosis replacing traditional clinical tests (Trendelenberg's or perthes's manoeuvre). Classical surgeries of treating varicose veins like stripping, avulsion or multiple ligation, are still the most common surgical modality in use in our country. Majority of our patients ran smooth post operative course and no mortality being reported.

#### Recommendations:

It is the time to introduce the newer method of treating varicose veins as Endo venous laser treatment or radiofrequency ablation and foam sclerotherapy to our hospital. This requires availability of necessary equipments and training of the specialists.

#### Authors' contribution:-

Study conception and design: Waleed M. Hussein

Acquisition of data : Hassanein Ali , Hussein  
 Drafting of manuscript : Waleed M.Hussen, Hassanein Ali , Hussein  
 Critical revision : Waleed M.Hussen

### References:

1. Varicose veins.. Mount Sinai Hospital, New York. 2010-7-6 <http://www.webcitation.org/5r1PRrJul>
2. Chandler JG, Pichot O, Sessa C, Schuller-Petrovic S, Kabnick LS & Bergan JJ. Treatment of primary venous insufficiency by endovenous saphenous vein obliteration. *VascSurg* 2009; 34(3): 201-204
3. Manfrini S, Gasbarro V, Danielsson G, Norgren L, Chandler JG, Lennox AF, Zarka ZA & Nicolaides AN. Endovenous management of saphenous vein reflux. Endovenous Reflux Management Study Group. *J VascSurg* (2000); 32(2): 330-342
4. Etienne G, Constatin JM & Hevia M. Cryo-stripping: an alternative to perforate-invaginate stripping. *Ann VascSurg* (1997); 11(3): 325-328.
5. Navarro L, Min R & Bone C. Endovenous laser: a new minimally invasive method of treatment for varicose veins – preliminary observation using an 810 nm diode laser. *DermatolSurg* (2001) 27(2): 117-122.
6. Hoshino S, Satokawa H, Takase S & Midorikawa H. External valvuloplasty for primary valvular incompetence of the lower limbs using angioplasty. *Int J Angiol* (1997); 6: 137-141.
7. Yamaki T, Nozaki M & Sasaki K. Preliminary report of a new approach to sparing the greater saphenous vein for grafting: valvuloplasty combined with axial transposition of a competent tributary vein. *J EndovascTher* (2001); 8(2): 188-196.
8. Cabrera J, Cabrera Jr. J. 7 Carcia-Olmedo AM. Treatment of varicose long saphenous vein with sclerosant in microfoam form: Long term outcomes. *Phlebology* (2000); 15: 19-23.
9. Tessari L, Cavezzi A & Frullini A. Preliminary experience with a new sclerosing foam in the treatment of varicose veins. *Dermatol Surg*. 2001; 27(1): 58-60. [[www.IVSL.org](http://www.IVSL.org)].
10. Mr. M.J. Callan. Epidemiology of varicose veins. *BJS* 1994 vol. 81 p. 167 – 173.
11. Ahumada M, Vioque J. Prevalence and risk factors of varicose veins in adults. *Med.clin (Barc)* 2004. 13; 123 (17); 647 – 51. [[pubmed](http://pubmed)]
12. Claude Franceschi. Physiopathologic Hemodynamique de l'Insuffisance veineuse in *Chirurgie des veines des membres Inferieurs*, page 49, 1996, AERCV editions 23 rue Royale 75008 Paris France.
13. Joseph J. Naoum and Glenn C. Hunter. Pathogenesis of varicose veins and implications for clinical management 2007 vol. 15 no. 5 page 242 – 249.
14. Forrest APM, Carter DC, Macleod IB. Principles and practice of surgery, Edinburgh: Churchill living stone; 1995 p 289 – 291.
15. Royle JP. Treatment of primary varicosities London: WB saunders; 1992 p 1239 – 1260.
16. Brand FN, Dannenberg AL, Abbott RD, Kannel WB. The epidemiology of varicose veins *Am J Prev Med*. 1988; 4(2): 96
17. F. G.R. Fowkes, C.J. Erans., A.J. Lee. Prevalence and Risk factors of chronic venous insufficiency. *Angiology journal* August 2001 vol 52. No. (1) published on line
18. Cesarone MR, Belcaro G, Nicolaides AN et al. Real epidemiology of varicose veins and chronic venous disease: the San Valentino vascular Screening Project. *Angiology*. 2002; 53 (2): 119.
19. Brand FN, Dannenberg AL, Abbott RD, et al. The epidemiology of varicose veins: The Framingham study; *AMJ Preven Med*. 1988, 4(2): 96 – 101.
20. Makivaara LA, Jukkoola TM, Sisto T, Luukkaala T, Hakama M, Laurikka JO. Incidence of varicose veins in Finland. *Vasa*. 2004 Aug; 33(3): 159 – 63.
21. Labropoulos N, Tassiopoulos AK, Bhatti AF, Leon L. Development of reflux in the perforator veins in limbs with primary venous disease. *J VascSurg* 2006; 43: 558 – 62.
22. Patrick H. Carpentier, Hildigard R. Maricq, Christin Biro. Prevalence, risk factors and clinical patterns of chronic venous disorders of lower limbs: A population based study in France. *J VascSurg* Vol. 40, Issue 4, 2004 p 650 – 659
23. Mark H. Meissner et al. Primary chronic venous disorders. *J VascSurg* Vol. 46, Issue 6, 2007 p s54 – s67
24. W. B. Campbell, A. S. Halim, A. Aertssen et al. The place of duplex scanning for varicose veins and common venous problems. *Ann R CollSurg Engl*. 1996; 78(6): 490 – 493
25. A. Cavezzi, N. Labropoulos, H. Partch et al. Duplex ultrasound investigation of the lower limbs *Eur J VascEndovascSurg* 2006, (31), 288 – 299
26. ML Wall, C. Dealy, RSM Davies and MH Simms. Local versus General anesthesia for varicose vein surgery: a prospective non-randomized controlled trial. *Phlebology* 2009 Vol. (24). No. (2) p (61 – 66).
27. Aromaa U. Anesthesia for short stay varicose vein surgery *Acta anesthesiol Scand (Scansnarica)* 1977; 21(5): 368 – 73.
28. U Aromaa, M Lahdensuu, D.A. Cozanitis. "Severe complications associated with epidural and spinal anesthesia in Finland 1987 – 1993 A study based on patient insurance claims. *Acta Anesthesiologica Scandinarica*, 1997 Vol. (41), Issue (4): p (445 – 452)

29-Michaels JA, Campbell WB, Brazier JE, Macintyre JB et al. Randomized clinical trial, observational study and assessment of cost effectiveness of varicose veins (REACTIV trial). *Health Technol Assess* 2006; 10: 1- 169. .

30-R Jia. X, Mowatt, G: Burr JM; CassarKetel “Systematic review of foam sclerotherapy for varicose veins” *The British Journal of surgery* (2007) 94 (8): 925 – 936. [www.IVSL.org

31-Perala JM, Wiik HT, Juvonen TS, Hauki “Endovascular Obliteration with radiofrequency-resistive heating for greater saphenous vein insufficiency; a feasibility study *J VascIntervRadiol* 2002; Vol. 13, Issue 6, p 569 – 575.

32-Rasmussen LH, Lawaetz M, Bjoem L, Vennits B, Blemings A, Eklof B. Randomized clinical trial comparing endovenous laser ablation, foam sclerotherapy, radiofrequency ablation and surgical stripping for great saphenous varicose *Br J Surg* 2011 Aug; 98(8): 1079 – 87. .[www.IVSL.org]

33-Critchley G, Handa A, Maw A, et al Complications of varicose vein surgery *Ann R CollSurgEng* 1997, 97(2) 105 – 110.

34-A. M. Van Rij, J Chai, GB Itill, R. A. Christie Incidence of deep vein thrombosis after varicose vein surgery. *BJS* 2004 Vol. (91), Issue (12) p(1582 – 1585). [www.IVSL.org].

35-Kazuhito Nagasaki, Kenji Matsumoto, MunehisaKaneda et al Pulmonary Embolism after stripping of varicose veins. *International Journal of Angiology* 2002; 11: (245 - 247).

36-Ramelet, A. A. Phlebectomy “Technique, Indications and Complications” *International Angiology* 2002; (21): 46 – 51.

37-Darke SG: The morphology of recurrent varicose veins. *Eur J VascSurg*; 1992; (6):512.