

Fine Needle Aspiration Cytology of Lung Masses, benefits, precautions and complications.

Mohammed J. Jameel*

FIBMS, ThCVS

Abstract:

Background: Pulmonary masses represent a great challenge for diagnosis. Fine Needle Aspiration Cytology (FNAC) is one of the diagnostic methods which was used since long time.

Objectives: To concern on Fine Needle Aspiration Cytology of pulmonary masses regarding benefits, precautions and patient's preparation to avoid possible complications.

Patients and Methods: A prospective study is carried out from December 2008 to July 2015 on 45 patients presented with pulmonary masses to the Department of the thoracic and vascular surgery at Al-Yarmook teaching hospital and from the private sector. A Fine Needle Aspiration Cytology was done for them under local anesthesia as an outpatient procedure.

Results: 40 patients (88.9%) got accurate results of diagnosis as different types of malignancies. Five patients (11.1%) got inconclusive results. No mortality reported. Complications like Pneumothorax was occurred in three patients (6.7 %), Haemoptysis in 14 patients (31%) and mild chest pain in 13 patients (29%).

Conclusion: FNAC is relatively safe and valuable method to diagnose pulmonary mass lesions and to categorize them for better subsequent management either surgical or by chemotherapy but the patients must be prepared well and the doctor who intend to do FNAC either being trained to deal with possible complications or backed up with a thoracic unit.

Keywords: Pulmonary masses, Fine Needle Aspiration Cytology, Accurate diagnosis, Pneumothorax.

*Fac Med Baghdad
2016; Vol.58, No.1
Received: Dec,2015
Accepted: Jan.,2016*

Introduction:

Pulmonary masses represent a great challenge for diagnosis especially when they are asymptomatic or when the symptoms are not related to respiratory system like peripheral masses which invade nearby structures (1) e.g. chest wall or intercostals nerves, here the difficulty is to understand the patients that they have a major chest problem and to make them to accept to do an investigation like needle aspiration (2). Fine Needle Aspiration Cytology (FNAC) of pulmonary masses is one of the diagnostic methods which had been used since long time (1,2) and it is considered to be relatively safe and valuable method since it can diagnose tumors which do not require surgical intervention and can be treated by chemo-radiotherapy like Lymphoma and small cell carcinoma (1-3).

The aim of this study is to concern on (FNAC) of pulmonary masses regarding benefits, precautions and patient's preparation to avoid possible complications.

Patients and Methods:

A prospective study is carried out from December 2008 to July 2015 on 45 patients presented with pulmonary masses; the study group was collected from the Department of the thoracic and vascular surgery at Al-Yarmook teaching hospital and from the private sector. All selected patients have either lung masses in close contact with chest wall (Sub pleural) or masses which are away from central airways that make them not approachable by Bronchoscope. 12 patients of the study

sample underwent investigations previously but with negative results (seven patients underwent flexible bronchoscope by other doctors, three patients underwent Fine Needle aspiration cytology (FNAC) and Sputum cytology was done for two patients).

The FNAC was done as an outpatient procedure under local anesthesia, after history taking and clinical examination Bleeding and Clotting times were checked and any abnormality of coagulopathy was corrected, chest film was studied to decide which mass is in close contact with chest wall (Sub pleural) to be approached directly i.e. not under CT scan guide depending on determination of surface anatomy landmarks of the mass relation to the outer chest wall obtained from chest film and CT scan film which was done for patients to indicate the exact site and size of the mass, this method is less time consuming for the CT scan department and decreases Radiation exposure of the author during sampling, while those masses which lie deep in lung were approached under CT scan guide.

All the aspirations (except one done by respiratory Physician) were done by the author using spinal needle gauge 18 to obtain good sample and 20 ml syringe to exert negative pressure. Before doing the aspiration an I.V cannula was inserted to get an access to vascular system to be used if any complication occurs. For elderly patients and/or in cases with deep pulmonary masses a slow I.V infusion of one Ampoule Cyclokapron 250mg was given 30 minutes prior to aspiration as a prophylaxis against pulmonary bleeding and haemoptysis. For those patients with masses in close contact with chest wall three samples of FNAC were taken from three different points

*Dept. of Surgery, College of Medicine, Al-Mustansiriyah University.
E-mail: drmod2012@yahoo.com.

depending on surface anatomy land marks to increase positivity giving 5 minutes rest to the patient after each aspiration during which the patient was monitored looking for the development of any complication, while in CT scan guided cases only one aspiration was taken, the aspiration was done with careful in and out movement of needle with slight rotation to get good sample of cells which were directly smeared on slides and fixed by 95% alcohol and examined by two pathologist. If any patient developed haemoptysis during or after aspiration we also took sample of the coughed-up blood and fix it on separate slides and send it for examination looking for accompanied malignant cells which may be shed from the mass secondary to pricking it by the needle and this will help to increase positivity rate. After FNAC all patient were kept under observation for two hours looking for development of any complication and after that they were discharged to home when they were in good condition depending on clinical chest examination and pulse oximetry reading of oxygen saturation and they were also checked again on next visit two days later when the results of cytology was obtained, chest film was done for four patients when the development of Pneumothorax was suspected but they were all negative.

Results:

The criteria of patients involved in this study and the obtained results were summarized in Table-1 below:-

Table-1: Patient criteria and obtained results from the study.

		Frequency	Percentage
Gender	Male	28	62%
	Female	17	38%
Age distribution/ y	50-59	15	33%
	60-69	18	40%
	70-79	12	27%
FNAC outcome	Positive/Primary Lung cancer/ Lobectomy	3	6.7%
	Positive/Primary Lung cancer/ChemoRx.	31	68.9%
	Positive/ Metastatic Lung Tu. /ChemoRx.	2	4.4%
	Positive/Malignant Thymoma/ChemoRx.	1	2.2%
	Positive/ Lymphoma/ Chemotherapy	3	6.7%
	Negative inconclusive results	5	11.1%
Complications	Pneumothorax / Chest tube insertion	3	6.7%
	Haemoptysis / self limiting	14	31.1%
	Mild chest pain	13	28.9%

Most patients involved in this study were male with the age distribution towards older age groups. Positive results were obtained in 40 patients (88.9%) of the study group and they were treated as it was presented in the table. Lobectomy was done by the author in three cases (6.7%) while the rest of 37 patients (82.2%) sent for chemotherapy. Regarding Negative result cases the author lose contact with three patients, the fourth patient was proved to be malignant by another attempt of FNAC done by other doctor while the fifth patient proved to be malignant by an open lung biopsy which was also done by another surgeon.

No Mortality from the procedure. Regarding complications which were developed Pneumothorax was seen in three cases, the first patient was 76 year old man and the FNAC was done by the author, he had emphysematous changes on CT scan film and he developed Pneumothorax 15 minutes after procedure and he was admitted to hospital and chest tube was inserted. Regarding the second patient she was 64 year old female the FNAC was done by another Physician and when Pneumothorax was developed they referred her to thoracic department and the chest tube was inserted by the author while the third patient had developed Pneumothorax secondary to FNAC done in another center and he escaped from diagnosis and since the result of FNAC was negative and when he was being prepared for another attempt of FNAC under CT scan guide the author discover presence of pneumothorax, for this patient a chest tube was inserted first and the FNAC was done one hour later under CT scan guide and the result was positive for malignancy. Haemoptysis was developed in 14 patients (31.1%), it lasted for few minutes and patients were treated by lying the FNAC side down and slow I.V infusion of one ampoule Cyclokapron 500mg. Mild local chest pain was developed in 13 patients (28.9%) and it was self-limiting.

Regarding the method of aspiration in 26 (58%) patients they had masses in close contact with chest wall (Sub pleural), therefore; the aspiration was done directly without CT scan guide, of these 26 cases three patients (11.5%) yielded negative or inconclusive results (diagnostic accuracy 88.5%) while the rest of 19(42%) patients the aspiration was done under CT scan guide because their masses were lying deep in pulmonary parenchyma and of these group two of them (10.5%) had negative inconclusive results (diagnostic accuracy 89.5%) (Fig-1 below).

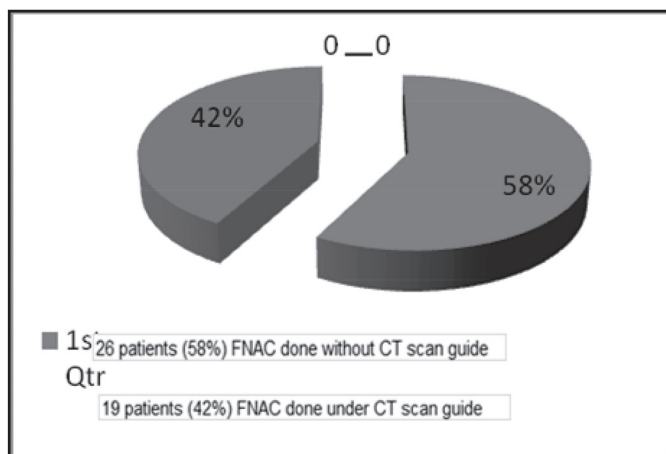


Figure-1: Methods of FNAC. -7-

Discussion:

Pulmonary masses either primary or secondary represent a great health challenge world-wide and FNAC represents one of the valuable method to reach diagnosis and initiate treatment (1-3). Regarding gender distribution in our study 62% of patients were male this is near to the result in other study(1) which is 65% male, another study(2) shows 78% male incidence which is higher than our results and it may be due to social and cultural differences. Peak age incidence in this study was 60-69 year (i.e. the age incidence towards more older age group) while in other studies (1, 2) there were patients included with less than 40 year while the peak age incidence was (50-59 year)(i.e. more younger age group) this can be explained by better health system in other countries which enable them to discover cases at earlier stages. Regarding the results of this study, it yielded 88.9% positive rate for different types of malignancy and it was possible to do curative lobectomy for three patients who were picked up early in the course of their illness while the other cases were diagnosed late, this represent a good results in comparison to other study (Review Article) (4) which consider any success rate above 85% is satisfactory, in other study a diagnostic accuracy of 90% was recorded (5). Regarding inconclusive results the author tried his best to keep contact with those patients to follow up them and two of them were diagnosed to be malignant by other doctors, similar inconclusive results were found in other studies(4,5) but the patients outside continue their follow up in the same center, therefore; no cases were lost. Regarding complications, Pneumothorax was reported in three patients (6.7%) and it was treated by chest tube insertion, of these three cases pneumothorax was developed only in one case from those patients who the author did FNAC for them by himself,

the other two cases of pneumothorax had developed when FNAC were done by other doctors but they were included in the study because their follow up was done by the author, this result is considered good percentage in comparison to other studies were higher percentage of pneumothorax was reported like (54%)(6), (27.2%)(7) and (26% even with the use of different size spinal needles)(8). Another study which is a Review Article(reported that the incidence of pneumothorax is variable from 0-61%, but in experienced hand it must be less than 20%, Chronic Obstructive Pulmonary Diseases, deep or non-pleural based or small lesions were associated with increased incidence of pneumothorax)(4). Haemoptysis was reported in 31% of cases in this study and it was self-limiting and did not associated with major complain but it was higher than what were reported from other studies (2 %(9), 8.8 %(10),2.3%(11)) and may be probably due to the use of bigger diameter needle in this study (FG-18) in comparison to other studies (1-7,9,10) who used smaller diameter spinal needles and the policy to do multiple punctures in non-CT scan guided group of patients.

Local chest pain after FNAC was reported in 28.9% of cases and also it was also self limiting and comparable to what was reported in other studies 18 %(9).Regarding method of aspiration in this study a diagnostic accuracy of FNAC without CT guide was 88.5%, for other study with same condition it was (84.5%) (12). While the diagnostic accuracy of FNAC under CT guide in this study was 89.5% which is comparable to results obtained from other studies (95%) (1), (87.7%) (11). There are other complications were reported in other studies like Haemothorax (6, 13) and dyspnea (14) syncope and recurrent laryngeal nerve palsy (6), but these complications did not occur in this study.

Conclusion:

Fine Needle Aspiration Cytology is relatively safe and valuable method for diagnosis of pulmonary mass lesions that can help doctors to avoid unnecessary operations when chemotherapy is the main stay of treatment as in cases of Lymphoma and Small cell lung carcinoma while in other cases like Primary squamous cell Lung cancer we can establish diagnosis from FNAC and later to plan either to go to curative surgery if the general condition of the patient is satisfactory or send the patient to chemotherapy. Important points that patients must be prepared well regarding their general condition and coagulopathy status, also when any doctor who intend to do FNAC must either be trained well to deal with possible complications which might occur or be backed up with a thoracic unit that can offer help when it is required.

References:

1. Santosh Kumar Mondal, Dipanwita Nag, Rama Das, etal. Computed tomogram guided fine-needle aspiration cytology of lung mass with histological correlation: A study in Eastern India. *South Asian Journal of Cancer*. 2013 Jan; 2(1): 14-18.
2. Moumita Sengupta, Kaushik Saha. Computed tomography guided fine needle aspiration cytology of pulmonary mass lesions in a tertiary care hospital: A two-year prospective study. *Medical Journal of Dr. D.Y. Patil University*. 2014 Mar; 7 (2): 177-81.
3. Shivani Kalhan, Pankaj Sharma, Sonia Sharma, etal. Evaluation of precision of guidance techniques in image guided fine needle aspiration cytology of thoracic mass lesions. *Journal of Cytology*. 2012 Jan; 29 (1): 6-10.
4. Rubens Chojniak, Paula Nicole Vieira Pinto, Chiang Jeng Ting, etal. Computed tomography-guided trans thoracic needle biopsy of pulmonary nodules. *Radiol Bras*. 2011 Sep; 44(5): 315–320.
5. Shrestha MK, Ghartimagar D, Ghosh A. Computed tomogram guided fine-needle aspiration cytology of lung and mediastinal masses with cytological correlation: A study of 257 cases in Western region of Nepal. *Nepal Med Coll J*. 2014; 16(1): 80-83.
6. Michael J. Odell, Kenneth R. Reid. DOES PERCUTANEOUS FINE-NEEDLE ASPIRATION BIOPSY AID IN THE DIAGNOSIS AND SURGICAL MANAGEMENT OF LUNG MASSES?. *CJS*. 1999 August; 42(4): 297-301.
7. Igor Kocijančič and Ksenija Kocijančič. CT-guided percutaneous trans thoracic needle biopsy of lung lesions – 2-year experience at the Institute of Radiology in Ljubljana. *Radiol Oncol* 2007; 41(3): 99-106.
8. ASIM SHAUKAT, YASSER AMIN, AFSHAN QURESHI, etal. PNEUMOTHORAX AFTER CT GUIDED TRANSTHORACIC NEEDLE ASPIRATION BIOPSY OF LUNG MASSES. *Biomedica*. 2006 jul.-Dec; 22 (3): 88-91.
9. SARKER RN, RABBI AF, HOSSAIN A, etal. COMPUTED TOMOGRAPHY GUIDED TRANSTHORACIC FINE NEEDLE ASPIRATION CYTOLOGY IN THE DIAGNOSIS OF SONOGRAPHICALLY NON-APPROACHABLE INTRATHORACIC MASSES – A STUDY OF 100 CASES. *J Dhaka Med Coll*. 2011 April; 20 (1): 25-31.
10. Hakan Solak, Selahattin Ztaß, Semih AÜanoÜlu, etal. Diagnostic Value of Trans thoracic Fine Needle Aspiration Biopsy in Thoracic Lesions. *Turkish Respiratory Journal*. 2001 August; 2(2): 11-15.
11. Jacob Baby, Paul George. Computed tomography guided fine needle aspiration cytology of thoracic lesions: A retrospective analysis of 114 cases. *Journal of Dental and Medical Sciences*. 2014 Jan; 13(1) : 47-52.
12. R. Prasad, R.A.S. Kushwaha, P.K. Mukherjee, etal. ACCURACY AND SAFETY OF UNGUIDED TRANSTHORACIC FINE NEEDLE ASPIRATION BIOPSY IN THE DIAGNOSIS OF INTRATHORACIC LESIONS. *Ind. J. Tub*. 1994; 41:167-170.
13. Manas Madan, Hema Bannur. Evaluation of Fine Needle Aspiration Cytology in the Diagnosis of Lung Lesions. *Turkish Journal of Pathology*. 2010; 26(1): 1-6.
14. Dorthe Ulrik Knudsen, S. Møller Nielsen, J. Hariri, etal. Ultrasonographically Guided Fine-Needle Aspiration Biopsy of Intrathoracic Tumors. *Acta Radiologica*. 1996; 37: 327-331.