

Relieving Symptoms of Chronic Sinusitis in Children By Adenoidectomy

Hussein M. Hassan * C.A.B.M.S/ENT

Summary:

Background: To determine the efficacy of adenoidectomy in relieving symptoms of chronic sinusitis in children.

Patients and methods : A prospective study carried out on 35 patients who underwent adenoidectomy or Adeno-tonsillectomy between May 2004 and October 2005. The patient ages ranged from 3 to 12 years.

Five patients were unavailable for follow-up and did not complete the study so they are excluded from. The pre-operative symptoms were Rhinorrhoea, Nasal congestion, Headache, Postnasal drainage, Cough, Halitosis and Irritability.

Also recorded was Mouth breathing, Fever and Frequent antibiotic use. Telephone interviews with the patient's caregivers were conducted to collect information following the surgery regarding the presence of the same symptoms as well as an estimate of overall improvement. Follow-up ranged from 5 months to 1 year.

Results : The most frequently reported symptoms before surgery were Rhinorrhoea, Nasal congestion, Mouth breathing, and Frequent antibiotic use. (26, 28, 24, 30 patients respectively). These numbers decreased following surgery to (11, 12, 6, 24 patients respectively)

Complete or near complete symptom resolution was reported in 18 (60%) patients. Some improvement was reported in 6 (20%) patients. Minimal or no improvement was reported in another 6 (20%) patients.

Conclusion In the majority of cases, symptoms of chronic sinusitis in children are relieved by adenoidectomy.

Key words : Symptoms of chronic sinusitis, Children, Adenoidectomy

J Fac Med Baghdad
Vol. 49, No. 1, 2007
Received: March 2006
Accepted: June 2006

Introduction:

The adenoids were first described by the Danish physician Meyer. In his 1868 paper "adenoid vegetations in the nasopharyngeal cavity". The adenoid or pharyngeal tonsils form the central part of the ring of lymphoid tissue surrounding the oropharyngeal isthmus. The adenoid is covered by pseudostratified ciliated columnar epithelium that is plicated to form numerous surface folds. The adenoid develops as a mid line structure by the fusion of two lateral primordia that become visible during early fetal life, are fully developed during the seventh month of gestation, and continue to grow until the fifth year of life, often causing some degree of airway obstruction.² Thereafter the adenoid gradually atrophies, the nasopharynx grows, and the airway improves.³

Chronic sinusitis in children remains primarily a clinical diagnosis. The main symptoms of nasal congestion, rhinorrhoea, cough, headache, postnasal drainage, halitosis and irritability as listed in the literature overlap considerably with those of adenoid hypertrophy. Nevertheless, this symptom complex has been labeled by parents and clinicians as chronic sinusitis.

The focus of this study was to determine the efficacy of adenoidectomy in relieving these symptoms in children.

Patients and methods:

This prospective study carried out on 35 pediatric patients. Exclusion criteria included those patients with co-morbid conditions like allergies, asthma, and craniofacial abnormalities in order not to include them in causal of chronic sinusitis.

However some other co-morbidities like chronic otitis media and obstructive sleep apnea which seem to be the results of adenoid itself were included in the selection criteria, they were relatively uncommon. Nevertheless, five of the patients were unavailable for follow-up, so they were excluded from the study, therefore study carried out and completed finally on 30 patients.

The ages of patients ranged from 3 to 12 years with the median age of 6.6 years (figure 1)

These patients underwent adenoidectomy for symptoms of chronic sinusitis between May 2004 and October 2005.

Concurrent tonsillectomy was performed in 8 of these patients for chronic tonsillitis or obstructive sleep apnea.

The operations carried out under general anesthesia at Al Jerahat public Hospital as well as Private Hospital using the classical curettage method.

The most frequently reported symptoms before

* Dep. Of Surgery College of Medicine/Baghdad University

surgery were Rhinorrhoea, Nasal congestion, and Mouth breathing (figure 2) also all of the studied patients were frequent antibiotic users. Long term symptom control and overall improvement were assessed during a telephone interview with each patient's caretaker 5 to 12 months after surgery (mean 6 months).

Lack of documentation of the symptom or unsure response during the interview was recorded as absence of that symptom. A shift of some patients from group 1 and 2 to group 3 between the two time points was evident. Twenty four (80%) of 30 patients experienced at least some long term symptomatic improvement.

Furthermore 24 (80%) patients were able to reduce or completely eliminate their use of antibiotics during the study.

Results:

A marked decrease was seen in each of the symptoms at both of the post-operative time points (2-8 weeks) and (5-12months).

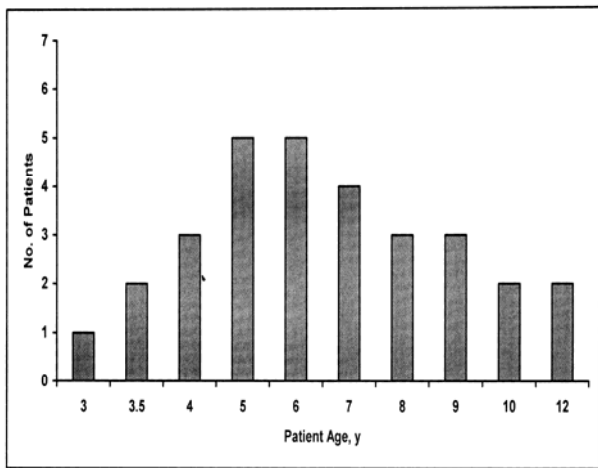


Figure (1): Age distribution of 30 patients undergoing adenoidectomy for treatment of symptoms of chronic sinusitis.

Table 1 shows the significance of adenoidectomy in relieving the main symptoms of chronic sinusitis in children according to Fisher method. Adenoidectomy significantly relieve hallmark symptoms of chronic sinusitis such as rhinorrhea, nasal congestion, and mouth breathing. although the results showed that adenoidectomy was insignificant in relieving headache and postnasal drip during the second postoperative period, presumably because the number of children presented with these symptoms is little, however, the results were significant during the first postoperative time point.

No correlation was found between patient's age and the change in number of symptoms.

To asses overall symptom improvements after adenoidectomy, patients were divided into 3 groups:

Those who experienced complete or near complete symptom resolution (group 1), those with some improvement (group 2), and those with minimal or no improvement (group 3) (figure 3) A majority of patients showed complete or near complete symptom resolution at both postoperative time points.

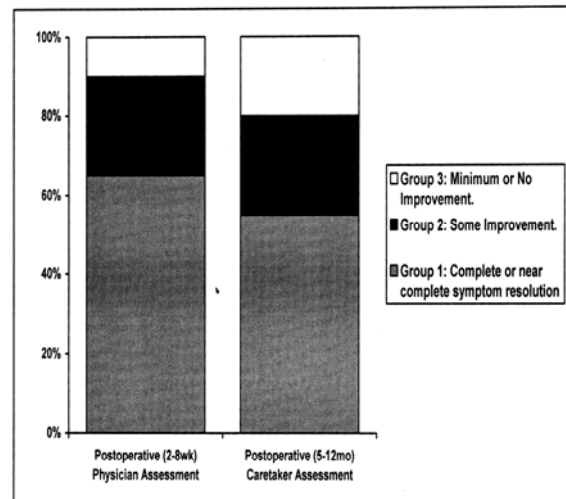


Figure (3): Overall resolution of sino - nasal symptoms after adenoidectomy.

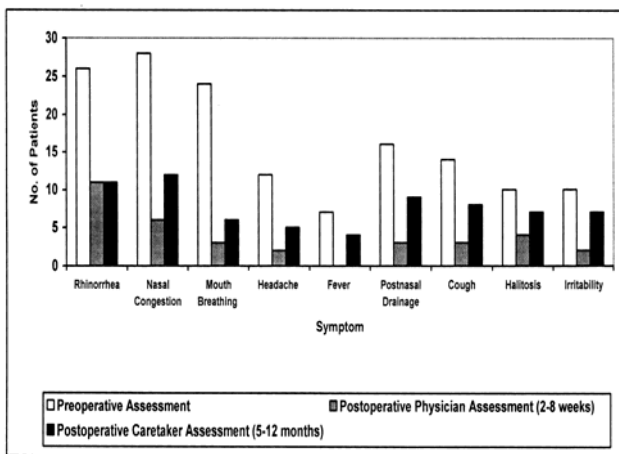


Figure (2): Preoperative and postoperative symptom profiles.

Symptoms	Preoperative	Postoperative (2-8 weeks)	P-value	Postoperative (5-12 months)	p-value
Rhinorrhoea	26	11	0.02	11	0.02
Nasal congestion	28	6	0.001	12	0.02
Mouth breathing	24	3	0.0003	6	0.004
Headache	12	2	0.01	5	0.07 N/S
Postnasal drip	16	3	0.006	9	0.09 N/S

Table (1): The significance of adenoidectomy in relieving the main symptoms of chronic sinusitis in children.

Discussion:

The definition of diagnosis of chronic sinusitis in children is difficult. The most common symptoms of cough, nasal congestion, rhinorrhoea, headach, and irritability overlap considerably with those of adenoid hypertrophy.⁴ In addition; recurrent viral infections of upper respiratory tract and allergic rhinitis may cause these symptoms. Although we did not find that the study patients had irreversible changes in the mucosa of their sinuses, which is the pathologic definition of chronic sinusitis, their symptom complex has been labeled chronic sinusitis. The origin of chronic sinusitis is undoubtedly multifactorial. Factors such as daycare attendance, passive smoking, air pollution, and gastro-esophageal reflux disease may be involved in some children.

The cornerstone of medical therapy for persistent sino-nasal symptoms in children is antibiotic use. The efficacy of adjunct measures, including treatment with nasal saline spray, topical and systemic decongestants, and antihistamines has not been clearly established.⁵ The identification and treatment of coexisting allergies and immunodeficiency are important. If these measures have failed to adequately control symptoms, a number of surgical options are available. Procedures such as antral lavage, inferior nasal antral windows, and the Caldwell-luc operation only address the maxillary sinuses; furthermore, they have not been shown to produce a lasting benefit in children.⁶ Endoscopic sinus surgery is also an option but requires specialized surgical training and carries added serious potential risks, including orbital and intracranial injury.

Adenoidectomy holds promise as a simple, effective, and relatively safe procedure that indirectly affects the sinuses.

A prospective study by Takahashi et al⁷ demonstrates improvement in the sinus films (water view) of 45 children following adenoidectomy compared with 33 controls. Water view of the sinuses, however, are not useful indicators of chronic sinusitis in children, as demonstrated in 2 studies^{8,9} comparing computed tomographic to x-ray film findings in children with symptoms of chronic sinusitis.

In another study by Paul,¹⁰ 100 children presenting with recurrent sino-nasal symptoms were divided randomly into 2 groups of 50 patients each. Eleven patients in the first group responded to medical therapy alone. Eighteen patients in the second group responded to adenotonsillectomy. Non responders in each group were treated with antral lavages and 67 of these patients were relieved of symptoms. No mention was made of the method or time course of evaluation.

Huggill and Ballantyne¹¹ described a series of 55 pediatric patients who underwent adenoidectomy, antral lavage, or a combination of the 2 procedures. Forty three (96%) of 45 patients undergoing adenoidectomy, either alone or in combination with antral lavage, experienced at least some relief of

symptoms, compared with 8 (80%) of 10 treated with antral lavage only.

Steven J. Vandenberg and Diane G. Heatley¹² described a retrospective case series from tertiary care centers, the results showed that adenoidectomy could be an effective treatment for relieving chronic sinusitis in children in the majority of cases.

Rosenfeld RM¹³ stated that patients with history of chronic recurrent sinusitis may benefit from adenoidectomy. Patients with chronic sinusitis and significant adenoid hypertrophy may initially benefit from adenoidectomy rather than undergoing more extensive sinus surgery. In addition, patients with chronic purulent rhinitis secondary to chronic adenoiditis may also respond to adenoidectomy if they have not responded well to appropriate medical therapy.

Two theories have been advanced to explain the relationship between adenoids and symptoms of chronic sinusitis.¹⁴ One theory is based on adenoid hypertrophy causing mechanical obstruction, stasis of nasal secretions, and a cycle of inflammation and infection. The other theory describes the adenoids as a bacterial reservoir that serves as a nidus for chronic infection. Further studies are needed to establish a causal relationship.

Results of this study show that both the number of sino-nasal symptoms and the severity of those symptoms are lessened in children with chronic sinusitis who undergo adenoidectomy. The size of adenoid pad and relative obstruction of the nasopharynx were not controlled for in this series. Part of this observed effect may be because many children experience spontaneous resolution of symptoms with increasing age.¹⁵

Conclusions

The major goal of treatment for symptoms of chronic sinusitis in children is improvement in the quality of life, both for the patient and the patient caretaker. Reduction in the use of antibiotics may also be seen as a benefit this is particularly important as emergence of antibiotic resistant strains of bacteria continues. Twenty four (80%) of the 30 study patients were able to reduce or completely eliminate their use of antibiotics after adenoidectomy. We realize that the remainder of patients who did not experience improvement in symptoms may require another modality of treatment including endoscopic sinus surgery in the future.

Our results indicate that in the majority of cases, adenoidectomy treats effectively the symptoms of chronic sinusitis in children. In the appropriate age group, adenoidectomy is a reasonable surgical first step for children with chronic sinusitis because of the procedures low morbidity rate, relatively low cost, high efficacy, and lack of need for specialized surgical training.

References:

1. Thornval A. Wilhelm Meyer and the adenoids. Arch

- Otolaryngol Head Neck Surg.* 1969; 90:3-83
2. Snook T. The development of the human pharyngeal tonsil. *Am J Anat.* 1934; 55:323
 3. Jeans WD et al. A longitudinal study of the growth of the nasopharynx and its contents in normal children. *Br J Radiol.* 1981; 54:117.
 4. Manning SC. Pediatric sinusitis. *Otolaryngol Clin North Am.* 1993; 26:623-638.
 5. Giebink GS. Childhood sinusitis: pathophysiology, diagnosis and treatment. *Pediatr Infect Dis J.* 1994; 13(suppl):S55-S58.
 6. Lusk RP. Surgical modalities other than ethmoidectomy. *J Allergy Clin Immunol.* 1992; 90:538-542.
 7. Takahashih, Fujita A, Honjo I. Effect of adenoidectomy on otitis media with effusion, tubal function and sinusitis. *Am J Otolaryngol.* 1989; 10:208-213.
 8. Lazar RH, Younis RT, Parvey LS. Comparison of plain radiographs, coronal CT, and intraoperative findings in children with chronic sinusitis. *Otolaryngol Head and Neck Surgery.* 1992; 107:29-34.
 9. Mcalister WH, Lusk R, Muntz HR. Comparison of plain radiographs and coronal CT scans in infants and children with recurrent sinusitis. *AJR Am JRoentgenol.* 1989; 153:1259-1264.
 10. Paul D. Sinus infection and adenotonsillitis in pediatric patients. *Laryngoscope.* 1981; 91:997-1000.
 11. Huggill PH, Ballantyne JC. An investigation into the relationship between adenoids and sinusitis in children. *J Otolaryngol.* 1952; 66:84-91.
 12. Steven J. Vandenberg, Dian G. Heatley. Efficacy of adenoidectomy in relieving symptoms of chronic sinusitis in children, a retrospective study. *Arch Otolaryngol Head Neck Surg.* 1997; 123 :675- 678
 13. Rosenfeld RM. Pilot study of outcomes in pediatric rhino sinusitis. *Arch Otolaryngol Head Neck Surg.* 1995; 121:729
 14. Lusk RP, Lazar RH, Muntz HR. The diagnosis and treatment of chronic sinusitis in children. *Pediatr Clin North Am.* 1989; 36:1411-1421.
 15. Otten FWA, van Aarem A, Grote JJ. Long-term follow-up of chronic maxillary sinusitis in children. *Int J Pediatric Otorhinolaryngol.* 1991; 22:81-84.

