

Esophageal Foreign Bodies

Waleed M. Hussen* MBChB, MS, FIBMS

Summary

Background: The removal of an impacted foreign body in the esophagus is still a common practice in the Thoracic Department of the Medical City Hospital. The objective of this study is to cast a light on this rather a common phenomenon in our country, its risks and its management.

Patients and Methods: This is a retrospective study of 120 patients with foreign bodies in the esophagus managed successfully in our department during five years period 1998 – 2002 inclusive. The study included 65 males and 55 females. Their ages range between 1 year and 75 years. The most common age group was less than 10 years, which constitutes about 30% of our patients. Varieties of foreign bodies were encountered, their ways of presentation, clinical findings and radiological appearances will be prescribe.

Results: Successful removal of the foreign bodies was done in most of the cases. In 4 patients esophageal dilatation was done for an area of stricture on which the foreign body was impacted. Surgery was necessary in two patients for the removal of foreign bodies which were impossible to be removed endoscopically.

Conclusion: Rigid esophagoscopy under general anesthesia is the procedure of choice for foreign body removal and nearly all the cases could be considered preventable.

Key words: Foreign body (FB), Esophagoscopy

Fac Med Baghdad
Vol. 51, No.3, 2009
Received: May.2009
Accepted: June.2009

Introduction:

Foreign bodies impaction in the esophagus is still common in our country partly due to the prevalence of some habits among workers like carpenter, by holding objects such as nails in their mouths during their work, while in children having the natural curiosity of ingesting many types of objects other than food specially while crawling unattended by the mother so the baby will pick up any object he encountered on the ground and introduced it into his mouth so inevitably some of the objects become lodged in the esophagus.

Patients and Methods:

This is a retrospective study of 120 patients admitted to the Department of Thoracic Surgery of the Medical City Teaching Hospital in Baghdad, Iraq during five years period between (January 1998 and December 2002). The study included 65 males and 55 females so male to female ratio was approximately 1:1.2. It included patients as young as 1 year old and as old as 75 years old. The most common age group was less than 10 years, which constituted 30% of our patients. The next most common age group is between (11-20) years which constituted (20%) of this study. The rest of the patients are distributed as shown in Figure (1) and table (1)

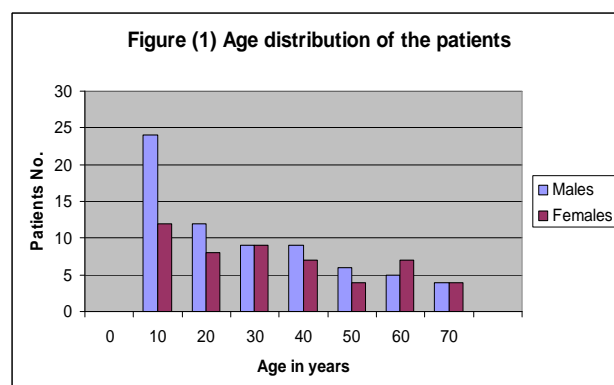


Table (1) : Age distribution of patients with esophageal FB .

Age in years	No.	%
0-10	36	30%
11-20	20	16.6%
21-30	18	15 %
31-40	16	13.3 %
41-50	10	8.3%
51-60	12	10%
61-70	8	6.6 %

Usually the presentation could be as early as possible as the patient seeks immediate medical help or in case of children, the parents will immediately take the sufferer to the nearest hospital or emergency unit fearing of asphyxia and death. On the whole, our patients were presented as early as one hour after the swallowing and as late as one week after. These patients were presented mostly with dysphagia or diffuse salivation from the mouth. Dysphagia is

* Department of Thoracic and Vascular Surgery, College of Medicine, University of Baghdad.

more common in older age group while drooling of saliva is the most common presenting symptoms during the first few years of life .Other symptoms occurring less frequently such as repeated vomiting .Respiratory symptoms due to the presence of a foreign body high in the esophagus with consequent pressure on the trachea leading to air way compression and dyspnea . Pain may occur and it may be cervical or thoracic in location .Symptoms presentation are illustrated in table (2).

Table (2) Symptoms presentation of the patients

Symptoms	No.	%
Dysphagia	84	70%
Drooling	46	38.33%
Repeated Vomiting	30	31.2%
Respiratory Symptoms	20	21.2%
Pain –Cervical ,thoracic	16	13.33%

On arrival of the patient, immediate history taking which is the corner stone of the diagnosis specially in children under 10 years of age particularly in the presence of witness and an immediate X-ray of the soft tissue of the neck and a chest X-ray should be done .The radiological appearance depends on the constituent of the foreign body, still it is very useful in demonstrating a radio-opaque foreign body in 80 patients (66%) .Barium study is not routinely done because it was not always available in our hospital due to the effect of embargo during the period of study still it has been done in few patients and a radiolucent foreign body was nicely demonstrated .The patient was taken to the endoscopy room after being well prepared as regard the initiation of the anesthesia .The endoscopy room is a well equipped theatre designed for the endoscopic procedure.An I.V. line is established and endo tracheal intubation is instituted .

A suitable size esophagoscope, appropriate grasping forceps and adequate sucker are all prepared and checked prior to induction of anesthesia. With the patient is fully relaxed, the procedure is started and completed .The methods of foreign bodies' removal are shown in table (3).

Table (3) Methods of foreign body removal

Methods	No.	%
Esophagoscopy	94	78.33%
Laryngoscopy & McGill's forceps	14	11.6%
Bougenaging	3	2.4%
Folly's catheter	1	0.83%
Descended during induction	6	5%
Surgery	2	1.66%

Methods of foreign bodies' removal

1-Rigid esophagoscopy is mostly used for removal of the foreign body and it gives a chance of having direct look on the mucosa so that we can manage any possible injury .This was successful in 94 (78.33) patients .

2-Magill 's forceps under direct laryngoscopic vision , this is very useful in foreign body specially in coins which is lodge just below the cricopharyngeous muscle in particular when it is visible on plain X-ray to be situated above the level of the clavicle and this was successful in the removal of 14 (11.6%) foreign bodies .

3-In three cases (2.5%) part of the foreign body was removed and the rest was pushed down to the stomach using esophageal dilator (Bougenage). 4-In only one patient a balloon catheter (folly's catheter) introduced trans-orally into the esophagus and a successful removal of a marble was achieved .

5-In 6 (5%) patients, the foreign body was descended into the stomach during the attempt to remove it endoscopically .

6-Surgery was needed in two patients with impacted foreign body that exploration of the cervical esophagus for removal of the impacted denture and right thoracotomy for removal of impacted shaving razor .

7-Few patients were presented with a foreign body that is already descended to the middle or lower esophagus that (temporization) may be an option so that the procedure can be post bond for (12-24) hours later then a new X-ray can be arranged and this end mostly in spontaneous descend of the foreign body down to the stomach so that we need only to observe its emergence with the stool within one to two days (not included in this study).

Sites of foreign bodies impaction: Usually the foreign bodies are commonly lodge in the sites of the naturally occurring narrowing or constriction (¹), that is just below the crico-pharyngeous , broncho – aortic constriction and the cardia .The distribution of the foreign bodies according to the sites of impaction is shown in table (4) .

Table (4) Distribution of foreign bodies according to the sites of impaction

Site	No.	%
Upper third	75	62.5%
Middle third	25	20.8%
Lower third	14	11.6%

After removal of the foreign body a chance is to be taken to have a look on the mucosa and in most of the cases there may mild congestion and edema at the site of impaction which will resolve gradually.

Results:

Successful removal of the foreign bodies was achieved in most of the cases .the types of foreign bodies, their numbers and their percentages are shown in table (5).

Table (5) various kinds of FB removal

Types of F.B.	No. of patients	%
Bones(sheep ,chicken& fish)	52	43.3%
Coins	12	10 %
Bolus of meat	11	9.1%
Denture	10	8.3
Metallic pieces	9	7.5 %
Apricot	3	2.5 %
Button	3	2.5 %
Pins	3	2.5 %
Plastic pieces	3	2.5 %
Safety pin	2	1.6 %
Watch	2	1.6 %
Onion shell	2	1.6 %
Stone	1	0.8 %
Grape skin	1	0.8 %

N.B.:- The remaining 6 cases which constitute (5 %) are either coins (3 cases) or food particles (3 cases also) where descended during induction of anesthesia .

Most of the cases run uneventful course and if every thing went smoothly, the patient can be discharge home .In four patients, the foreign body was impacted at an area of stricture that is already present so dilatation done by bougenage after removal of the foreign body .In three patients the following sequel happened: A foreign body (partial denture) was impacted in the cervical esophagus and manipulation was already done so the area was inflamed , red congested and it was very difficult to remove it endoscopically , so exploration of the cervical esophagus done , esophagotomy , removal of the denture ,repair of the esophagus , draining the area and immediate temporary feeding gastrostomy which used for two weeks until healing occur and a contrast study revealed no leak and the patient discharge home .A foreign body (shaving razor)which was stacked to the middle third of the esophagus in a young female in a suicidal attempt and the esophagoscopy was unsuccessful in removing it so right thoracotomy done , esphagotomy , removal of the foreign body , repair of the esophagus and nasogastric feeding in upright posture started and continued for one week thereafter a contrast study revealed that there is a leak of the contrast material into the chest so a temporary feeding gastrostomy was performed and maintained for two weeks and after that a contrast study fail to demonstrate any leak so that the patient resume oral intake and discharge well .A foreign body (partial denture) was successfully removed by esophagoscopy but the patient was dyspneic after recovery so an immediate chest X-ray was taken and it revealed right sided hydropneumothorax so tube thoracostomy was done to drain the air and the fluid together with heavy antibiotics cover in addition to temporary feeding gastrostomy for two weeks until

complete healing occur as demonstrated by contrast study and the patient discharge well.

Discussion:

Foreign body ingestion is still common in Iraq especially in children below 10 years of age and in particular those below three years of age and it affected males in a slightly greater proportion than females due to probably to increasing activity of the male and this comparable to the study done by Sittitrai et all (2) Varieties of foreign bodies were swallowed by the patients . Bones of different types were the most common, account for (44%) of the foreign bodies while coins which were the most common foreign body removed , it represents only (10%) owing to absence from the market in our country and this different than other studies (3,4).Artificial denture was the most dangerous foreign bodies leading to serious complications , it is most commonly seen in adult and elderly patients and this in agreement with the study done by Vyas et all (4) . Most of the patients came from rural areas representing (60%) of the cases which may reflect poorer education and especially in the presence of big families and over crowding and their children left unattended picking up any object and putting it in their mouths and once the foreign body lodges in the esophagus, the patient or in cases of children the parent will seek immediate medical help.

Diagnosis will depend largely upon the history of the ingestion and the presenting symptoms. Dysphagia was the most common presenting symptom in adult account for (70%) while drooling of the saliva was the most common symptom in children account for (33.3%) which are comparable to other studies (5, 6, 7.) Infants and children may experience choking , coughing from a foreign body lodge in the upper half of the esophagus (21.1%) . Respiratory symptoms that mimicked upper respiratory tract infection or croup proved misleading with long standing foreign body retention (7). Chest pain can occur and in a rare cases can be misleading as cardiac pain (8) . Plain X-ray of the neck and chest X-ray are very useful especially when a radio- opaque foreign body is suspected and this is comparable to other studies (5, 7) . The most common site for foreign body impaction is in the cervical esophagus which constitutes (62.5%) of the cases and this is comparable to other studies (6 , 9) . (8) The second most common site is the middle esophagus which constitutes (20.8%) of the cases and the least common is the cardia which constitutes (11.6%) of the patients. Rigid esophagoscopy under general anesthesia was the treatment modality of choice for the removal of the foreign bodies unless contraindicated by the patient mental state or advanced atherosclerosis of the cervical spine and the procedure was very successful in the removal of 94 foreign bodies (78.3%). Rigid esophagoscopy is safe, quick and very reliable in the process of foreign body removal , it also allows a direct

visualization of the esophageal mucosa so that an immediate assessment of the state of the mucosa and an urgent action can be taken for the management of any possible injury and this is in agreement with other studies (2,5). Other possible methods such as direct laryngoscopy with magill's forceps, bougenaging and folly's catheter were useful but in a very limited number of patients. Surgery was required in only two patients. The 1st. was an impacted foreign body in the cervical esophagus that a cervical esophagotomy was done for its removal and the 2nd. Was a stacked foreign body in the thoracic esophagus that needed a right thoractomy for its removal and in both cases a temporary feeding gastrostomies were required for a short period until complete healing of the esophageal leak was ascertained. Complications may arise which may be due to the foreign body itself causing esophageal injury such as erosion, bleeding or perforation and in one patient tube thoracostomy was needed to relief hydro-pneumothorax complicating denture impacted in the thoracic esophagus. The complications may be due to the instrumentation such as perforation and this is in agreement with the study done by Mato-Ponce et al (10). We keep our patients under observation for (12-24 hrs.), during which nothing per orum was given and a chest X-ray is taken to rule out any possible injury to the esophagus and after that if every thing is fine the patient can be discharge home. The endoscopic removal of upper digestive foreign body with the use of fiber endoscopy was advocated by Korolev et all (11).

Conclusion:

Rigid esophagoscopy under general anesthesia is the procedure of choice for foreign body removal. It allows excellent visualization of the esophagus giving a chance of having a direct look on its mucosa to asses any possible injury in addition to the availability of different types and sizes of foreign bodies forceps. Nearly all the cases could be considered preventable and its recommended that foreign bodies should not be within the reach of children. Kids should be watched carefully. Mothers should pay more care and attention during meals, and workers should avoid putting foreign bodies in their mouths during their works.

References:

- 1- Mark B . Orringer , *The esophagus : historical aspect and anatomy* ,Sabiston *Text book of Surgery* , 1966 , chap 26 , p 655 .
- 2- Sittitrai P , Pattarasakulchi T , Tapatiwong H, *Department of otolaryngology , Faculty of Medicine , Chiang mai University , Thailand , J Med Assos Thai* 2000 : 83 (12) : 1514 -8 .
- 3-Eugene D , Megahren MD ,*Esophageal foreign bodies , pediatric in Review* 1999 ;20 (4) : 129-39

- 4-Vyas K , Sawant P , Rathi P , et al , *Foreign bodies in gut . J Assosc Physicians India* 2000 ; 48 (4) : 394 – 6 .
- 5-Abdulaziz A Ashor , *Foreign bodies of the esophagus ,Annals of Saudi Medicine* 2000 ; 20(2) : 173 -4 .
- 6-Ciriza C , Garcia L , Soares P , et al . *What predictive parameter best indicate the need for emergent gastrointestinal endoscopy after foreign body ingestion ? J Clin Gastroenterol* 2000 ; 31 (1) : 23-8 .
- 7-Macpherson RI , Hill Jg , Othersen HB et al . *Esophageal foreign bodies in children treatment and complications . Am J Roentgenol* 1966 ; 166 (4) : 919- 24 .
- 8-Nakashabendi IM , Maldonado ME , Brady PG , *Chest pain : Overlooked manifestation of unsuspected esophageal foreign body . South Med J* 2001 ; 94 (3) : 333-5 .
- 9-Castellon -Ortega J , Hernandez- Diaz A , Pila – Perez R , et al . *Foreign bodies in the esophagus of adult . Acta Otorrinolaringol Esp* 2000 ; 51 (6) : 511-4 .
- 10-Mato-Ponce M , Munoz- Alcantara M ,Perez-Perez A , et al . *Tension pneumothorax during removal of a foreign body from the esophagus , Rev Esp Anesthesiol Reanim* 2001 ; 48 (3) : 151 – 4 .
- 11-Korolev MP, Antipova MV , Fedotov LE , *Present day endoscopy in the diagnosis and therapeutic tactics in foreign bodies of upper digestive tract . Vestin Khir Im 11 Grek* 1999 ; 158(5) : 12-5 .