

Indonesian Journal of Tropical and Infectious Disease

Vol. 9 No. 2 May–August 2021

Research Article

Manifestations of Acute Pancreatitis in Severe COVID-19 Patients: Is This a Coincidence?

Pradana Zaky Romadhon¹, Satriyo Dwi Suryantoro^{2*}, Choirina Windradi², Bagus Aulia Mahdi¹, Esthiningrum Dewi Agustin², Krisnina Nurul W¹, Dwiki Novendrianto¹

¹Faculty of Medicine, Universitas Airlangga, Surabaya, Indonesia

²Universitas Airlangga Hospital, Surabaya, Indonesia

Received: 27th April 2021; Revised: 20th May 2021; Accepted: 7th June 2021

ABSTRACT

Coronavirus Disease-19 (COVID-19) adalah penyakit yang disebabkan oleh Severe Acute Respiratory Coronavirus-2 (SARS-CoV2) yang berasal dari China, menyebar dengan cepat ke seluruh bagian negara lain yang menyebabkan pandemi dunia. Dengan derajat gejala yang bervariasi yang disebabkan oleh COVID-19, virus ini menyebabkan kerusakan pada beberapa organ, baik karena efek inflamasi tidak langsung maupun efek sitopatik. Data terkait keterlibatan pankreas dalam kasus COVID-19 masih belum jelas. Seorang laki-laki usia 83 tahun dirawat karena gejala COVID-19 berat. Dalam perawatan, pasien memberikan gejala dan tanda pankreatitis akut tanpa diketahui faktor risiko yang terkait. Pada pemeriksaan didapatkan RT-PCR SARS-CoV2 positif dari swab nasofaring, amilase lipase yang meningkat serta gambaran ultrasound khas untuk pankreatitis akut. Tatalaksana pasien tetap berdasar pada kasus SARS-CoV2 dengan isolasi, oksigenasi, pemberian anti virus dan suportif. Pemberian antibiotik juga didasarkan pada terapi empiris yang kemudian disesuaikan hasil sensitivitas kultur. Skor prognosis pankreatitis menunjukkan risiko kematian pada kasus moderate. Pada perjalanan, pasien meninggal karena shock sepsis. Prevalensi pankreatitis akut dan tingkat keparahannya perlu diamati. Dalam artikel ini, kami menyajikan kasus pankreatitis akut yang terjadi pada COVID-19 parah dengan faktor risiko yang tidak diketahui. Diagnosis penyebab kasus pankreatitis masih belum jelas tetapi beberapa bukti autopsi kasus infeksi SARS-CoV2 dengan pankreatitis menyebutkan bahwa infeksi virus ini dapat menyebabkan injuri pada pankreas. Kondisi sepsis dapat diakibatkan infeksi virus SARS-CoV2 (viral sepsis) atau ko-infeksi bakteri. Oleh karena itu, rasionalisasi penggunaan antibiotik juga diperlukan. Kasus ini merupakan kasus yang membutuhkan manajemen holistik dan intensif karena kedua kondisi berpotensi dapat memperberat satu sama lain. Pengenalan awal kegawatan serta terapi tepat merupakan hal yang penting dapat menunjang kesintasan pasien.

Keywords: Pancreatitis, Infectious disease, COVID-19, Organ damage, Sepsis

ABSTRACT

Coronavirus Disease-19 (COVID-19) is a disease caused by Severe Acute Respiratory Syndrome Coronavirus-2 (SARS-CoV2) came from China, this disease is highly infectious causing rapid spread throughout the world. COVID-19 had various of symptoms, manifestation, and also degree to cause multiorgan dysfunctions either due to indirect inflammatory effects or cytopathic effects. Data regarding the involvement of the pancreas in COVID-19 cases is still unclear. An 83-year-old man was being treated for severe COVID-19 symptoms. He had received treatment for severe COVID-19. Unfortunately, during hospitalization, the patient presented the symptoms and signs of acute pancreatitis without any known risk factors. Physical findings supported the diagnosis criteria for acute pancreatitis. Moreover, supporting examination found a positive SARS-CoV2 RT-PCR from a nasopharyngeal swab, increased amylase lipase and a typical ultrasound image for acute pancreatitis. Patient management was remains based on COVID-19 cases with consisting of isolation, oxygenation, antiviral and other supportive medical treatment. Antibiotic administration was also based on empirical therapy which was then adjusted for the results of culture sensitivity. Although the etiology diagnosis of this patient was uncertain, we assumed SARS-CoV2 infection could cause injury to the pancreas.

* Corresponding Author:
satriyo.dwi.suryantoro@fk.unair.ac.id

We did observe patient based on clinical and laboratory findings other than that based on Ranson's Score the patient was in poor prognosis. Eventually patient died due to septic shock. Sepsis conditions in COVID-19 patients could be due to viral sepsis and bacterial co-infection. Therefore, a rationalization of the use of antibiotics is also needed. This case is a case that requires intensive and holistic management because the two conditions can potentially aggravate each other. Early recognition of emergency and appropriate therapy is important to support patient survival.

Kata kunci: pankreatitis, pandemi, COVID-19, kerusakan organ, sepsis

How to Cite: Romadhon, PZ., Suryantoro, SD., WindrAdi, C., Mahdi, BA., Agustin, ED., Nurul, WK., Novendrianto, D. (2021). Manifestations of Acute Pancreatitis in Severe COVID-19 Patients: Is This a Coincidence?. Indonesian Journal of Tropical and Infectious Disease, 9(2), 79-84

INTRODUCTION

SARS-CoV2 causes COVID-19 infection that until now has become a world pandemic¹⁻³. Coronavirus (CoV) is a group of enveloped viruses possibly identified in animals. Some CoV found in animals may precipitate infectious diseases, such as viral gastroenteritis (TGEV), porcine epidemic diarrhea virus (PEDV), avian infectious bronchitis virus (IBV), and swine acute diarrhea syndrome coronavirus (SADS-CoV)⁴⁻⁶. COVID-19 also came with extrapulmonary manifestations which involve the role of the ACE2 receptor. This may include neurological, renal, hepatic, gastrointestinal, thromboembolic, cardiac, endocrine, and dermatology systems^{7, 8}. To date, the most common gastrointestinal manifestations of COVID-19 are nausea, vomiting, diarrhea, abdominal pain⁹⁻¹⁵. However, in our case, the occurrence of acute pancreatitis without an understandable risk factor was the direct injury to the pancreas gland by SARS-CoV2¹⁶.

CASE

Mr. S, 83 years old, came with tightness 2-3 days ago getting more severe for two days. The patient did not previously complain of having fever and runny nose. There are no complaints of nausea or vomiting. Sometimes the patient complains of abdominal pain so that he is merely able to eat half of the usual portion. Daily, the patient can still do activities such as bathing, walking, and wearing clothes. However, since

then, the patient was unable to carry out his activity. He was weak and only able to lie down and sit with assistance. The patient started having a cough 2 days ago, thus the abdominal tightness was getting worse when coughing. The patient self-checks peripheral oxygen saturation at home and turned out only 72-75% room air. The patient did not previously have diabetes mellitus but had a history of hypertension with heart disease. There is no history of drinking alcohol. The patient takes Clopidogrel 75 mg once daily and Bisoprolol 2.5 mg once daily.

Respiratory muscles were found retracted. Neither Ronchi nor wheezing was heard from the lung examination. The apex beat is dilated, which is in line with cardiomegaly figured out on x-ray. Initial examination revealed a positive SARS-CoV2 antigen swab with a chest x-ray showing pneumonia (see Figure 1). Naso-oropharynx polymerase chain reaction (PCR) swab was positive for SARS-CoV2 with CT 27.5.

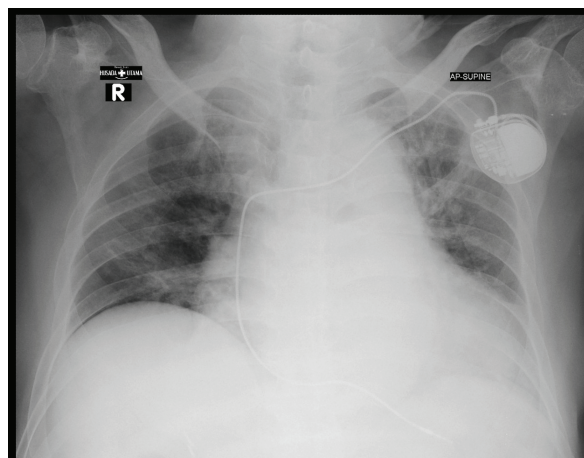


Figure 1. Pneumonia COVID-19 chest x-ray.

Laboratory findings showed Hb 14.2 g/dl, white blood count 6530 u/l, urea 69.8; serum creatinine 2.84, D-dimer 8.54. Blood gas analysis showed moderate to severe hypoxia with pH 7.43; pCO₂ 24, pO₂ 146, BE 17, HCO₃ 16.2, SaO₂ 96. The patient received supportive and symptomatic treatments such as oxygen supplementation, Meropenem, Nebivolol, Codeine, Dexamethasone for ten days, Fondaparinux, and Remdesivir drip for five days.

On the third day of treatment, we found that the patient's right upper abdominal pain was severe. Unfortunately, our abdominal examination found discoloration of the left flank that we suspect as pancreatitis (see Figure 3). Subsequent laboratory tests showed an increase in amylase number 138 U / L and lipase 200 U / L with normal liver function. Serum cholesterol was normal. The inflammatory markers of CRP did not show an increase of 0.7 mg / L while procalcitonin was 0.36 ng / mL. Abdominal ultrasound results showed a slightly enlarged pancreas with a very hypoechoic structure (see Figure 2). At the current examination, we found a positive Ranson prognostic Ranson's score for acute pancreatitis for the variable age 83 years. However, after a 48-hour evaluation, there was a positive Ranson criterion for increased hematocrit, urea, and base excess deficit. Therefore, the prognosis of mortality is around 11-15%.

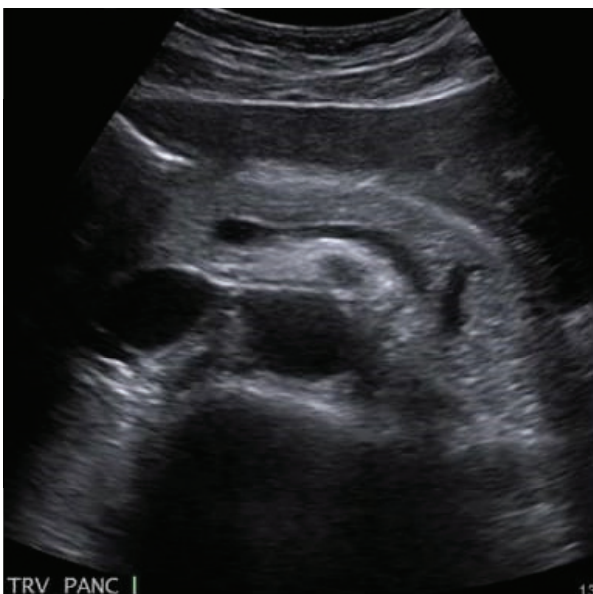

Figure 2. Ultrasonography of Pancreatitis.

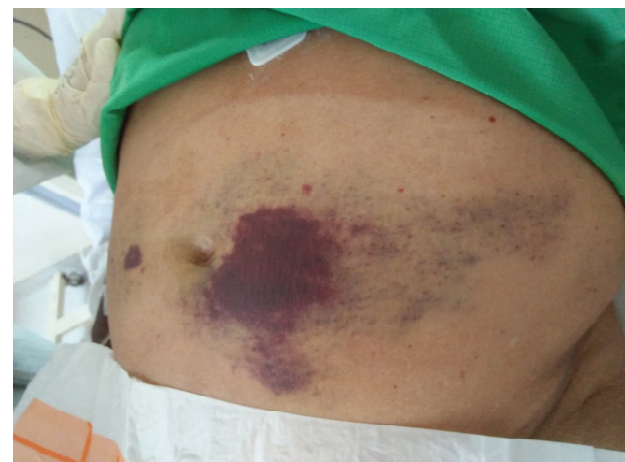

Figure 3. Abdominal appearance indicating suspicious acute pancreatitis.

Based on the results of the examination, the patient was diagnosed with COVID-19 and acute pancreatitis. Some of the most common etiologies of pancreatitis are etiologies such as gallstones, alcohol, pancreatitis-causing drugs such as furosemide, thiazide, sulfa, hypertriglyceridemia, other viral infections, autoimmune, posttraumatic were not found in this patient. Besides, the use of Clopidogrel might considerably be also one of the triggering factors since Lai et al. declared that persons actively consume Clopidogrel were at 8.46-fold increased odds for acute pancreatitis.²⁷ therefore, However, Tthe diagnosis of the cause of acute pancreatitis can be confirmed by autopsy to detect SARS-CoV2 in pancreatic cells. But we could not nt performed it because this examination was not done routinely.

However, we still manage patients according to the management of acute pancreatitis. At the time of the initial diagnosis of pancreatitis, the patient was fasting and receiving parenteral nutritional support, adequate fluid administration, also antibiotics according to culture results. The results of the patient's blood culture showed the growth of staphylococcus sp. then we changed the antibiotic treatment based on the results of the sensitivity test. Meanwhile, the patient has received Remdesivir as the anti-viral agent. Unfortunately, the patient falls into a state of septic shock then the patient died.

DISCUSSION

COVID-19 often manifests as respiratory complaints, but extrapulmonary ones require extra attention. Recent studies show that gastrointestinal symptoms can reach 50% with symptoms such as nausea (17.3%), diarrhea (12.9%), anorexia (12.2%), abdominal pain (5.8%). Meanwhile, in a journal written by Wang et al, in a case series, nine people had acute pancreatitis along with COVID-19 infection. Liu et al wrote that 17% of the 67 cases of severe COVID-19 had acute pancreatitis, although only 7.46% of the pancreatic injury was able to be captured by computed tomography^{14, 16}.

COVID-19 utilizes angiotensin-converting enzyme 2 (ACE2) as a receptor for the entry of viruses into human cells. ACE2 receptors are not only in the lungs but also widely spread in the esophageal, enterocyte, cardiovascular, renal, and pancreatic epithelial cells. Surprisingly, the amount of ACE2 RNA messenger was found more in the pancreas than in the lungs. ACE2 expression took both in the exocrine glands of the pancreas and in the islet cells. The spike protein (S) acts as a support for the ACE2 receptor. Expression of ACE2 and transmembrane serine protease 2 (TMPRSS2) that plays a vital role in the successful fusion of SARS-CoV2 into human cells, is found in β cells of the pancreas⁷.

Acute pancreatitis is a condition when the pancreas is inflamed. This inflammatory process may be confined to the pancreatic or peripancreatic tissue. The causes of this AP vary while severity also is divided to different degrees^{12, 17-19}. The most common risk factors for acute pancreatitis are gallbladder disease (often caused by cholelithiasis) and chronic alcohol consumption. Acute pancreatitis is defined as the presence of typical pancreatic abdominal pain, an increase in serum amylase/lipase more than three times of regular value, and ultrasound, CT, or MRI imaging findings support the diagnosis¹⁹⁻²¹.

In these patients, we found no risk factors that could explain the development of acute pancreatitis. Some of the most common pancreatitis etiologies such as gallstones, alcohol,

pancreatitis-causing drugs such as furosemide, thiazide, sulfa, hypertriglyceridemia, other viral infections, autoimmune, posttraumatic. No medical history of the patient seemed to cause the pancreatitis, but the use of Clopidogrel might possibly trigger it. His past medical history and drugs does not support the variable causes of pancreatitis. Patients with acute pancreatitis often have positive blood culture results when a systemic infection is found, especially in patients who have previously undergone intra-biliaer procedures. The results of blood culture in the most common acute pancreatitis patients were *Escherichia coli* and *Klebsiella* sp. Those systemic infection could be fatal. In this patient we found his blood culture positive for *Staphylococcus* sp meaning the source of infection could be anywhere that precipitate the septic state. Therefore, it is consistent with several similar case reports that it is possible to injury the pancreas in a patient with COVID-19^{12, 19}. In fact, in several observational case-control studies on pancreatic injury, there was an increase in serum amylase/lipase as a marker of pancreatic damage in 8.5-17.3% of cases. Interestingly, pancreatic abnormalities have been more frequently noted in the sub-group of patients having severe COVID disease^{17-19, 22}.

Several hypotheses suggest the occurrence of pancreatitis in COVID-19, namely the expression of ACE2 in the pancreatic ductal, acinar, and islet cells so that the virus can easily spread from the duodenal epithelium to the pancreatic gland^{17, 23, 24}. Other studies have shown that SARS-CoV-2 is able to infect pancreatic-induced pluripotent stem cells (iPSC) thus they produce proinflammatory cytokines such as CXCL12, IL-6, IL-8, IL-10¹². They observed that the SARS-CoV-2 hijacked the ribosomal machinery in the pancreatic cells and also increased the expression of some pancreatic ductal stress response genes. Prominently, the genes CXCL12, NFKB1, and STAT3 showed significant upregulation as compared to the control. The researchers report that the transcriptional analysis of SARS-CoV-2 infected iPSC-derived pancreatic cultures demonstrated active viral replication and pancreas-specific COVID-19 associated disease signatures. The SRP-protein targeting processes were upregulated, indicating

that host cell machinery was being repurposed for viral replication^{25,26}.

From RNA-sequencing studies, they established that the pancreas, specifically the exocrine compartment (acinar and ductal cells), has a high expression of ACE2. Gender and age present no difference in the expression of the ACE2 receptors. The researchers demonstrated that the iPSC-derived pancreatic cells used in this study exhibit ACE2 and TMPRSS2 expression. Both the receptors are present in the pancreas, especially in the exocrine portion²⁶.

Despite the many published cases of both the coincidence of acute pancreatitis with COVID-19, acute pancreatitis caused by COVID-19 is still unproven. However, if there is a case of acute pancreatitis with COVID-19, the occurrence of idiopathic acute pancreatitis due to COVID-19 cannot be neglected¹².

CONCLUSION

Cases of acute pancreatitis with COVID-19 can be a coincident or idiopathic. Thus far, diagnostic tool of this case is necrosis autopsy and SARS-CoV2 PCR. Through our observation, COVID-19 has raised suspicions of acute idiopathic pancreatitis in severe COVID-19. Therapy and monitoring in patients are still carried out according to the management of COVID-19 and pancreatitis.

ACKNOWLEDGEMENTS

We thank you to one of the private hospital in Surabaya for providing proper care for the patient

CONFLICT OF INTEREST

The authors declare that there is no conflict of interest

REFERENCES

1. Kumar M, Taki K, Gahlot R, Sharma A, Dhangar K. A chronicle of SARS-CoV-2: Part-I -Epidemiology, diagnosis, prognosis, transmission and treatment. *Science of The Total Environment*. 2020;734:139278.
2. Worldometer. COVID-19 Coronavirus Pandemic Data 2020 [cited 2020 01-02-2021]. Available from: <https://www.worldometers.info/coronavirus/>.
3. Liu Y, Ning Z, Chen Y, Guo M, Liu Y, Gali NK, et al. Aerodynamic analysis of SARS-CoV-2 in two Wuhan hospitals. *Nature*. 2020;582(7813):557–60.
4. Zhan M, Qin Y, Xue X, Zhu S. Death from Covid-19 of 23 Health Care Workers in China. *N Engl J Med*. 2020.
5. Hu Y, Deng H, Huang L, Xia L, Zhou X. Analysis of Characteristics in Death Patients with COVID-19 Pneumonia without Underlying Diseases. *Acad Radiol*. 2020;27(5):752.
6. Zhang B, Zhou X, Qiu Y, Feng F, Feng J, Jia Y, et al. Clinical characteristics of 82 death cases with COVID-19. *medRxiv*. 2020:2020.02.26.20028191.
7. Gupta N, Ish P, Kumar R, Dev N, Yadav SR, Malhotra N, et al. Evaluation of the clinical profile, laboratory parameters and outcome of two hundred COVID-19 patients from a tertiary centre in India. *Monaldi Archives for Chest Disease*. 2020;90.
8. Gupta S, Parker J, Smits S, Underwood J, Dolwani S. Persistent viral shedding of SARS-CoV-2 in faeces - a rapid review. *Colorectal Dis*. 2020;22(6):611–20.
9. Guo YR, Cao QD, Hong ZS, Tan YY, Chen SD, Jin HJ, et al. The origin, transmission and clinical therapies on coronavirus disease 2019 (COVID-19) outbreak - an update on the status. *Military Medical Research*. 2020;7(1):11.
10. Seeliger B, Philouze G, Cherkaoui Z, Felli E, Mutter D, Pessaux P. Acute abdomen in patients with SARS-CoV-2 infection or co-infection. *Langenbeck's Archives of Surgery*. 2020;405:861-6.
11. Huang JT, Ran RX, Lv ZH, Feng LN, Ran CY, Tong YQ, et al. Chronological Changes of Viral Shedding in Adult Inpatients With COVID-19 in Wuhan, China. *Clin Infect Dis*. 2020;71(16):2158–66.
12. de-Madaria E, Capurso G. COVID-19 and acute pancreatitis: examining the causality. *Nat Rev Gastroenterol Hepatol*. 2021;18(1):3–4.
13. Ahmed A, Fisher JC, Pochapin MB, Freedman SD, Kothari DJ, Shah PC, et al. Hyperlipasemia in absence of acute pancreatitis is associated with elevated D-dimer and adverse outcomes in COVID 19 disease. *Pancreatology : official journal of the International Association of Pancreatology (IAP) [et al]*. 2021.

14. Rotar O, Khomiak I, Nazarchuck M, Rotar V, Khomiak A, Taneja K, et al. Utility of Presepsin for Diagnosis of Infected Acute Necrotizing Pancreatitis. *Journal of the Pancreas*. 2019;21(6):167–71.
15. Kariyawasam JC, Jayarajah U, Riza R, Abeysuriya V, Seneviratne SL. Gastrointestinal manifestations in COVID-19. *Transactions of the Royal Society of Tropical Medicine and Hygiene*. 2021.
16. Wifi M-N, Nabil A, Awad A, Eltatawy R. COVID-induced pancreatitis: case report. *The Egyptian Journal of Internal Medicine*. 2021;33(1):10.
17. Kumar V, Barkoudah E, Souza DAT, Jin DX, McNabb-Baltar J. Clinical course and outcome among patients with acute pancreatitis and COVID-19. *Eur J Gastroenterol Hepatol*. 2021;33(5):695–700.
18. Bulthuis MC, Boxhoorn L, Beudel M, Elbers PWG, Kop MPM, van Wanrooij RLJ, et al. Acute pancreatitis in COVID-19 patients: true risk? *Scand J Gastroenterol*. 2021;56(5):585–7.
19. AlHarmi RAR, Fateel T, Sayed Adnan J, AlAwadhi K. Acute pancreatitis in a patient with COVID-19. *BMJ Case Rep*. 2021;14(2).
20. Sandhu H, Mallik D, Lokavarapu MJ, Huda F, Basu S. Acute Recurrent Pancreatitis and COVID-19 Infection: A Case Report with Literature Review. *Cureus*. 2021;13(2):e13490.
21. Wifi MN, Nabil A, Awad A, Eltatawy R. COVID-induced pancreatitis: case report. *Egypt J Intern Med*. 2021;33(1):10.
22. Narang K, Szymanski LM, Kane SV, Rose CH. Acute Pancreatitis in a Pregnant Patient With Coronavirus Disease 2019 (COVID-19). *Obstet Gynecol*. 2021;137(3):431–3.
23. Rasch S, Herner A, Schmid RM, Huber W, Lahmer T. High lipasemia is frequent in Covid-19 associated acute respiratory distress syndrome. *Pancreatology : official journal of the International Association of Pancreatology (IAP) [et al]*. 2021;21(1):306–11.
24. Troncone E, Salvatori S, Sena G, De Cristofaro E, Alfieri N, Marafini I, et al. Low Frequency of Acute Pancreatitis in Hospitalized COVID-19 Patients. *Pancreas*. 2021;50(3):393–8.
25. Samanta J, Gupta R, Singh MP, Patnaik I, Kumar A, Kochhar R. Coronavirus disease 2019 and the pancreas. *Pancreatology : official journal of the International Association of Pancreatology (IAP) [et al]*. 2020;20(8):1567–75.
26. Müller JA, Groß R, Conzelmann C, Krüger J, Merle U, Steinhart J, et al. SARS-CoV-2 infects and replicates in cells of the human endocrine and exocrine pancreas. *Nature Metabolism*. 2021;3(2):149–65.
27. Lai S-W, Lin C-L, Liao K-F. Actively using clopidogrel correlates with an increased risk of acute pancreatitis in Taiwan. *Int J Cardiol*. 2015 Mar;183:263–6.