

SEQUENTIAL APPLIED BENZALKONIUM CHLORIDE AND INSULIN EYE DROPS REDUCES OCULAR CENTRAL MACULAR THICKNESS AND IMPROVES VISION OF DIABETICS AND NON-DIABETICS

Herman C.I. Themen¹, Jerry R. Toelsie², Jerrel C. Pawiroredjo¹, Dinesh Jiawan¹, Robbert Bipat²

¹ Suriname Eye Center, Academic Hospital of Paramaribo and Department of Ophthalmology, Faculty of Medical Science, Anton de Kom University of Suriname

² Department of Physiology, Faculty of Medical Science, Anton de Kom University of Suriname

ABSTRACT

Introduction: Macular Edema is a rather disabling condition that can be the consequence of several disorders of the eye. Most of the time it occurs in patients suffering from diabetic retinopathy. The exact pathophysiological mechanism of this condition is not clear, but it is probably the result of inflammatory processes or structural and mechanical disturbances of the vitreomacular tissue. Due to this obscure pathophysiological mechanism, a targeted efficient treatment is still lacking. However, accumulating evidence is suggesting that local application of insulin might reduce the structural and functional defects of this disorder. The aim of this study is to assess the effects of sequential applied benzalkonium chloride and Insulin eye drops on the visual acuity and central macular thickness of eyes suffering from macular edema.

Methods: Patients refractive to or refusing treatment with anti-VEGF agents were selected. Their visual acuity and central macular thickness were measured immediately before and until six months after treatment. The treatment consisted of twice a day application of specially prepared benzalkonium chloride and Insulin eye drops. Results are expressed as mean \pm SD. The procedures followed were all in line with the guides for ethics of the hospital and were not in conflict with the declaration of Helsinki.

Result: After six months, the mean visual acuity increased significantly from 0.28 ± 0.17 to 0.53 ± 0.27 ($p = 0.002$) and the central macular thickness decreased from $393 \pm 122 \mu\text{m}$ to $250 \pm 72 \mu\text{m}$ ($p = 0.0005$).

Conclusion: Sequential applied benzalkonium chloride and insulin eye drops improve visual acuity and reduce central macular thickness in eyes suffering from macular edema. Large scale studies to confirm and to elucidate the exact mechanism of action are necessary. Apart from this, the use of these drops may prove to be a cheaper and more efficient method to treat the rather disabling condition.

Keywords: Macular edema, Insulin, visual acuity, central macular thickness

Cite This Article: THEMEN, Herman C.I. et al. Sequential applied Benzalkonium Chloride and Insulin Eye Drops Reduces Ocular Central Macular Thickness and Improves vision of Diabetics and Non-Diabetics. International Journal of Retina, [S.l.], v. 3, n. 2, sep. 2020. ISSN 2614-8536. Available at: <https://www.ijretina.com/index.php/ijretina/article/view/105>

INTRODUCTION

Macular edema is a consequence of a number of ocular diseases which include, but is not limited to diabetic retinopathy, retinal vascular occlusions, postsurgical conditions, and uveitic diseases.¹ The main pathophysiological mechanism is an accumulation of fluid in the various layers of the central retina.² The disabling disorder allegedly starts with a disturbance in the blood-retinal-barrier and is probably the result of inflammatory processes, surgical and nonsurgical vitreomacular structural and

*Correspondence to:

Herman C.I. Themen,
Suriname Eye Care Center
hcithemen48@gmail.com

and mechanical disturbances frequently accompanied by visible macular adhesion of posterior hyaloid, and an increase in capillary permeability³⁻⁵. This rather complex pathophysiologic mechanism makes it difficult to treat the disorder.

Current therapeutic strategies include primarily the application of non-steroidal anti-inflammatory eye drops, corticosteroids and inhibitors of carbonic anhydrase especially in patients with diabetes^{6,7}. In refractory cases photo-coagulation of retinal tissues and intra-vitreous injection of agents like crystalline steroids, VEGF antagonists, ocriplasmin with or without cannulation of occluded retinal vein and surgical vitreo-retinal release of traction are applied. Apart from the maintenance of a well-controlled blood glucose level being the main approach up till now, the last mentioned options are all invasive measures that may accompany a range of collateral tissue damage, which may lead to a significant formation of scar in healthy retinal tissues⁶⁻⁹. In addition frequent anti-VEGF injections may block the physiologic actions of VEGFA on normal neural and retinal cells and thus prevent adequate functional wound healing and visual function in time^{10,11}. Finally, intra-vitreous crystalline steroid harbors the potential to damage the optic nerve through steroid-induced glaucoma if not treated adequately.¹²

Consequently, the search for a less invasive, safe and overall long-term effective drug strategy with the main goal of preservation and maintenance of adequate central vision is ongoing^{13,14}.

Local application of insulin to the eye and skin of both animals as well as humans showed healing of corneal epithelial defects and skin wounds in both diabetics and non-diabetics¹⁵⁻¹⁷. Moreover, sequentially applied surfactant and insulin eye drops were currently tested in animals and humans for systemic regulation of blood glucose.^{18,19} A decrease of insulin receptors and glucose transporters in ocular tissue of diabetics^{20,21}, might hint towards a chronic local ocular insulin deprivation, perhaps even before the development of systemic diabetes mellitus. These reasons justify the evaluation of early started insulin eye drops sequentially applied after a surfactant to address the affliction of the blood-retinal barriers in the pigment epithelium and retina in macular edema. Since the effect of insulin eye drops in humans on macular edema has not yet been evaluated, we aimed

to evaluate the effects of insulin eye drops sequentially applied after a surfactant (0.01% Benzalkonium chloride eye drops) on macular edema found in patients with ocular disorders in this study.

METHODS

Patient selection

Patients were selected from subjects reporting at the department of ophthalmology of the Academic Hospital of Paramaribo in Suriname in the period of January 2016 until August 2016. They had been diagnosed with macular edema. A number of 30 patients initially reported with macular edema with or without macular hole on OCT. Out of this group, only patients who had been treated previously with anti VEGF (Bevacizumab) and had shown no long term regression of the edema and patients who had refused treatment with anti VEGF were selected. A number of 15 patients met these criteria. Six patients refused to participate in the study mostly because they had minimal macula edema and still a good visual acuity.

The remaining 9 patients participated with 12 eyes suffering from macular edema of which 4 also had a macular hole. One subject was refractory to intra-vitreous anti-VEGF, in both eyes. The remaining 8 subjects had no intra-vitreous anti-VEGF, retinal laser, pharmacological vitreolysis or cannulation of occluded retinal vein or surgical release of vitreo-macular traction immediately before or during the study. Seven of these were diabetics, while the remaining two did not suffer from this metabolic disorder. Of all 9 subjects 7 had diabetes and 2 were nondiabetic. All patients were informed that they could withdraw at any moment from the study without consequences.

Procedure

The ophthalmologist meticulously informed the participants about the procedures, possible adverse effects and outcomes and supplied them with all necessary data before receiving their oral and written consent to participate in this study. The departments of Ophthalmology and the emergency room of the hospital were available for 24/7 in case of emergency and unexpected adverse effects until three months after completion of the study. All procedures were in line with the hospital's policy on ethics and

complied with the declaration of Helsinki. The Board of Executives of the Faculty of Medicine of the University gave approval for publication of the results.

Immediately before the treatment was started, visual acuity and central macular thickness were classically determined with the Snellen eye chart and Optical coherence tomography (ZEISS Cirrus HD OCT model 5000) respectively. This was considered as the pretreatment baseline value.

Patients regularly received supplies of Benzalkonium chloride 0.01% and Mixtard insulin (Novolin 70/30, 100 IU/ml) eye drops for at least three months. These had been prepared by the hospital pharmacist. In brief the insulin was transferred from the flacons to a dropper bottle under sterile conditions in a laminar flow hood. Under the same conditions benzalkonium chloride was diluted from the available stock to the appropriate concentration and then titrated into a dropper bottle. The benzalkonium and insulin were both sequentially applied with a gap of 30 minutes twice a day to the affected eyes.

Participants were monitored for a period of up to one year. Visual acuity and central macular thickness were assessed every month during the treatment. Three of the subjects in this study had binocular macular edema of which in the first month the most affected eye was treated. They asked to treat the second eye accordingly in the second month.

Statistics

Obtained raw data were processed with Graphpad Prism 8.4.2. Data of individual eyes are graphically presented. For the pretreatment and treatment, the best visual acuity and the thinnest central macular thickness were registered. Because of the small sample size, Wilcoxon matched-pairs signed rank test was used to assess the difference. When $p < 0.05$, they were considered significantly different. The power of the studies was calculated with an on-line tool (http://onlinestatbook.com/2/calculators/power_calc.html) and was 0.77 for the visual acuity and 0.95 for the central macular thickness.

RESULTS

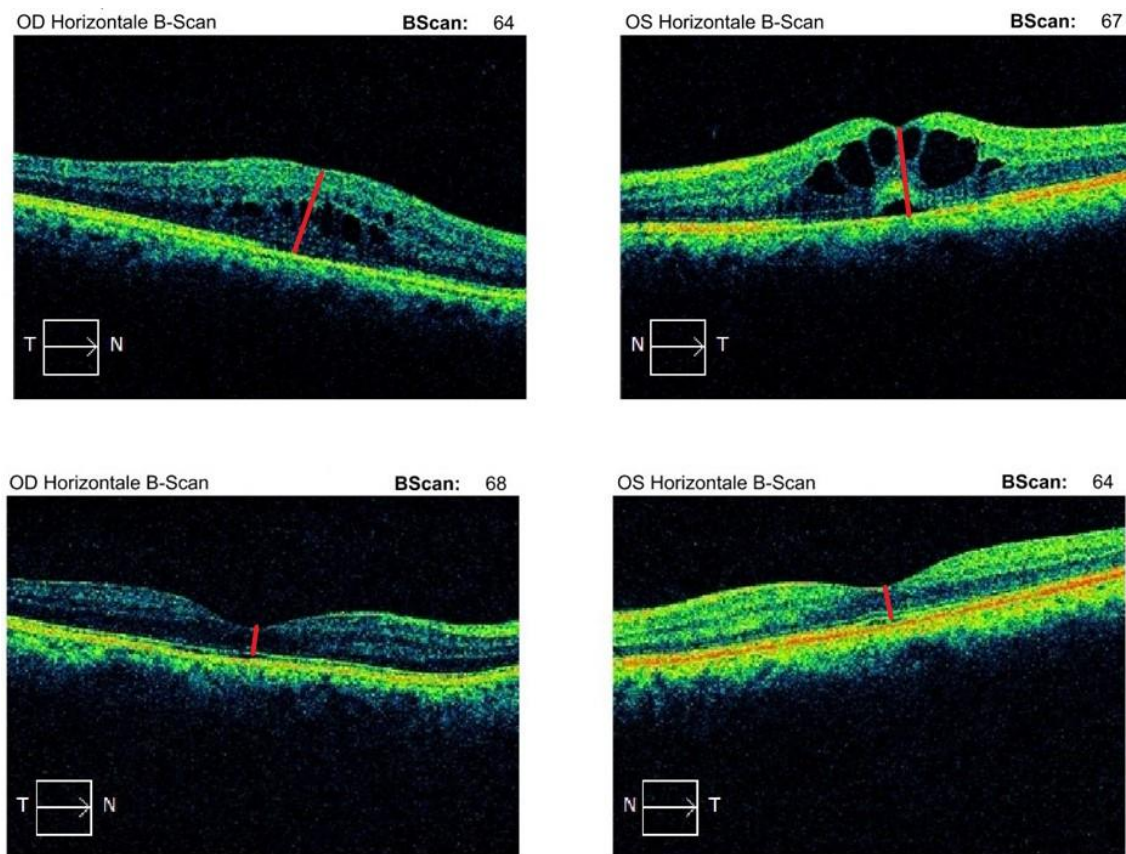


Figure 1. optical coherence tomography of the macular area of representative patient with Diabetes. A decrease of central macular thickness was observed after treatment of both eyes.

Figure 1 shows a scan of the retina before and after treatment. Figure 2 presents the maximum obtained visual acuity within 6 months after treatment was started. The mean visual acuity increased significantly from 0.28 ± 0.17 to 0.53 ± 0.27 ($p = 0.002$). Figure 3 presents the smallest thickness of central macula that had been obtained in the same period. The mean central macular thickness decreased from $393 \pm 122 \mu\text{m}$ to $250 \pm 72 \mu\text{m}$ ($p = 0.0005$). Thus, a clear improvement of both visual acuity and central macular thickness in the post-treatment period were observed.

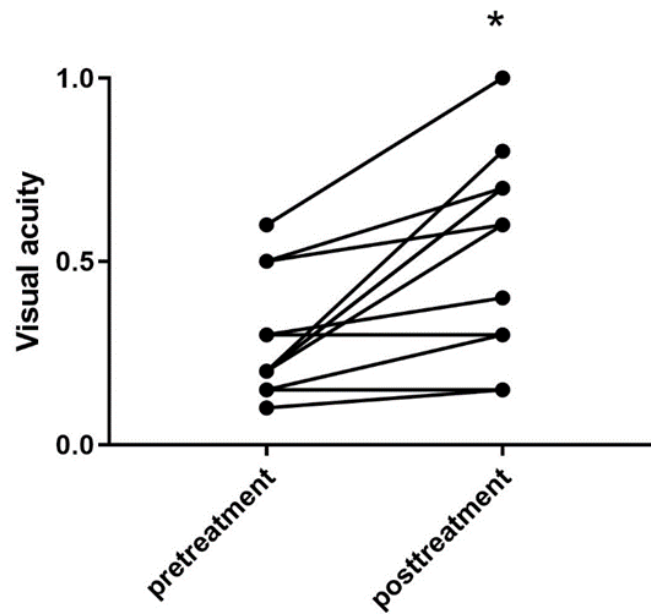


Figure 2. Visual acuity of individual eyes before and after treatment with insulin. * $p = 0.001$ vs pretreatment

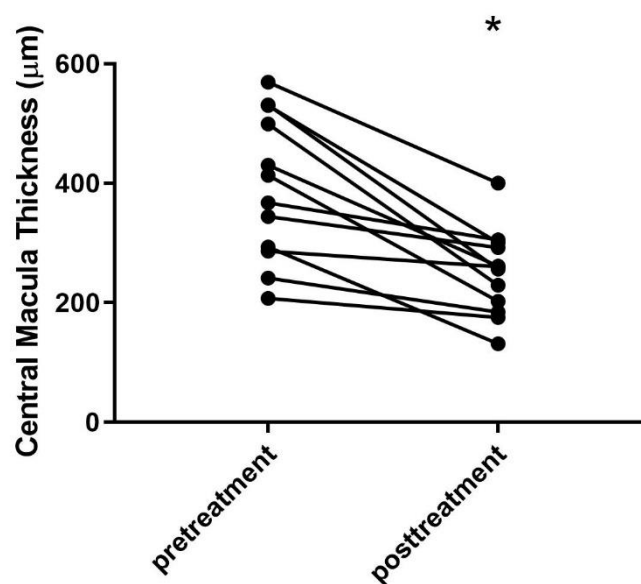


Figure 3. minimum thickness of central macula area before and after treatment with insulin. * $p = 0.0001$ vs pretreatment

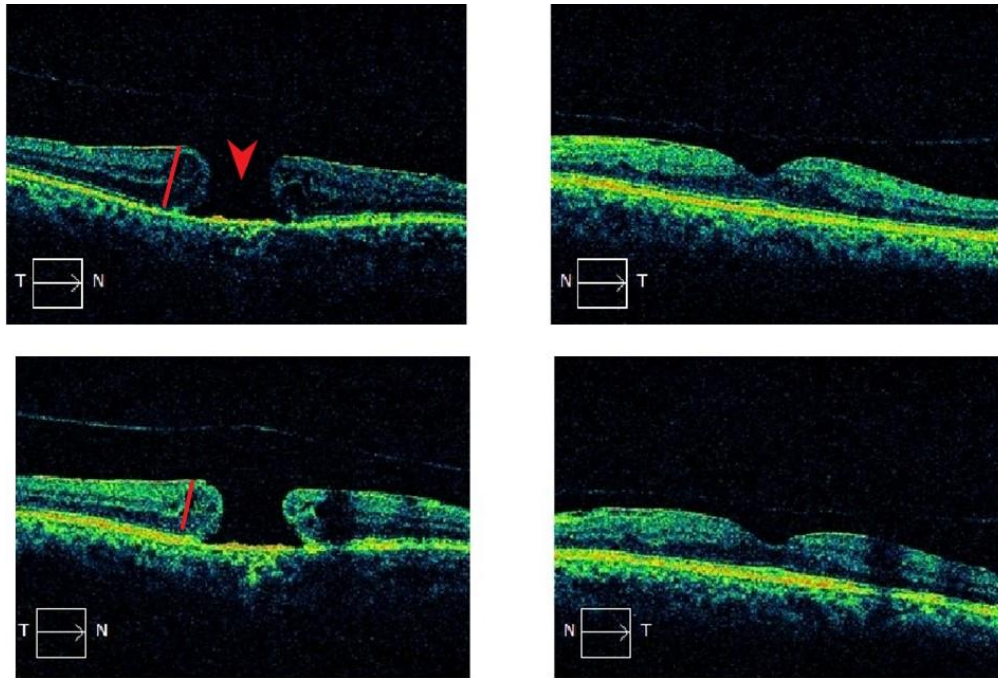


Figure 4: optical coherence tomography of binocular macular edema in a patient with a defect (arrow) in the central macula of the right eye. There is a clear reduction of thickness after treatment in both eyes, however, the visual acuity of the right eye did not improve significantly.

Figure 4 shows a scan of a patient with macular edema of both eyes and a clear defect in the central macula of the right eye. This is one of the four eyes with macular holes showing a significant decrease of macular thickness, however without significant improvement of visual acuity. For this reason, in this small number of cases, the mean improvement of macular thickness was allegedly better than the observed improvement of visual acuity. However, in the 8 remaining eyes without macular hole, the main visual acuity was better than the main edema reduction in all 12 eyes. Figure 5 is a representative scan of a non-diabetic with macular edema before and after treatment with the insulin.

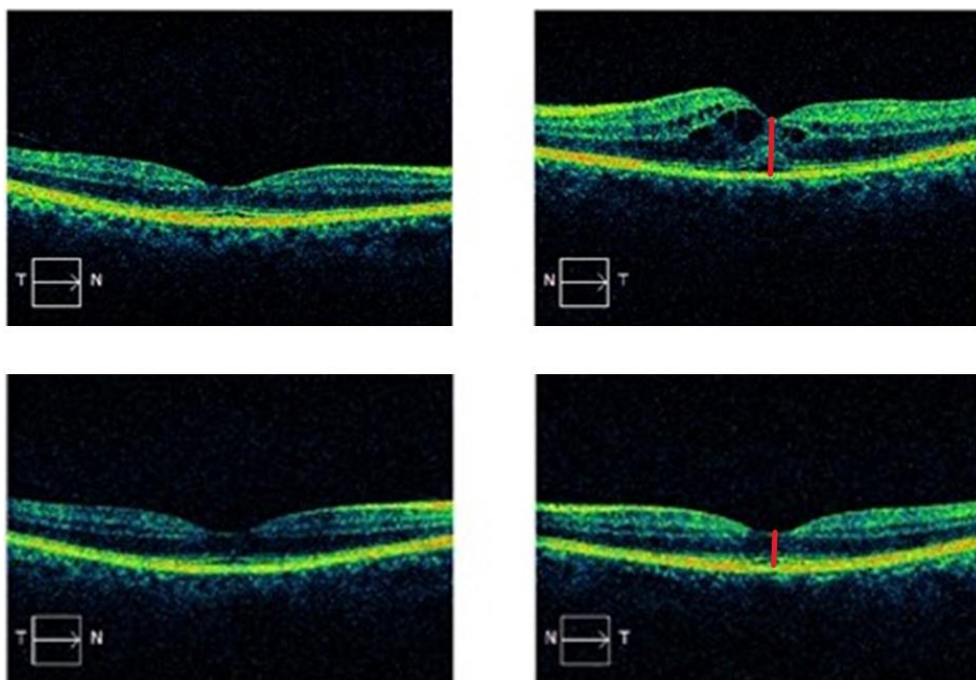


Figure 5: optical coherence tomography of a non-diabetic patient with macular edema in the left eye before and after treatment, also showing improvement of the central macular thickness.

DISCUSSION

This study shows that sequentially applied surfactant and insulin eye drops reduces central retinal thickness and improves visual acuity in eyes of patients suffering from macular edema. This observation is peculiar, since systemic insulin probably does not affect glucose metabolism of retinal nerve tissue directly.^{22,23}

Therefore, the effects observed in this study can be the result of other local actions of this hormone. For instance, it has been shown that the function of sodium potassium ATPase in the retinal tissue is reduced in eyes of diabetic animals and might be one of the pathophysiologic mechanism leading to macular edema.^{24,25} Insulin stimulates the action of the abovementioned ion-pump in murine corneal endothelial cells.²⁶ The resulting volume reduction with stimulation of this ion pump can explain a reduction in retinal thickness and hence an improved visual acuity.

Another study showed that insulin stabilizes the microvascular endothelial barrier.²⁷ Since disruption of the blood retinal barrier plays a role in the development of macular edema²⁸, this action of insulin may contribute to the reduction of macular thickness and improvement of visual acuity.

CONCLUSION

An additional mechanism could also be the stimulation of glucose uptake by the surrounding tissue near the external blood retinal barrier or pigment epithelium. The resultant reduction of glucose in the retinal tissue cells will lead to a reduced cell volume through osmotic processes.²³

Finally, as mentioned before, insulin inactivates the endothelial contractile machinery and enhances cell-cell adhesions in rat coronary microvascular endothelial monolayers.²⁷

Regardless of the abovementioned mechanisms, this study shows both a reduction of macular thickness and improvement of visual acuity.

Whatever the mechanism, the observations in this study warrant further investigation in large scale preclinical and clinical studies and eventually may lead to an alternative, less invasive early started therapeutic strategy, not only for macular edema but also in diabetics as a preventive strategy for DRP, in an effort to

treat the metabolic pathway upstream, next to downstream consequences.

REFERENCES

- Scholl S, Augustin A, Loewenstein A, et al. General pathophysiology of macular edema. *European journal of ophthalmology* 2011; 21 Suppl 6:S10-9.
- Scholl S, Kirchhof J, Augustin AJ. Pathophysiology of Macular Edema. *Ophthalmologica* 2010; 224:8-15.
- Das A, McGuire PG, Rangasamy S. Diabetic Macular Edema: Pathophysiology and Novel Therapeutic Targets. *Ophthalmology* 2015; 122:1375-94.
- Romero-Aroca P, Baget-Bernaldiz M, Pareja-Rios A, et al. Diabetic Macular Edema Pathophysiology: Vasogenic versus Inflammatory. *Journal of Diabetes Research* 2016:1-17.
- Kaiser PK, Riemann CD, Sears JE, et al. Macular traction detachment and diabetic macular edema associated with posterior hyaloidal traction. *American journal of ophthalmology* 2001; 131:44-9.
- Kessel L, Tendal B, Jørgensen KJ, et al. Post-cataract Prevention of Inflammation and Macular Edema by Steroid and Nonsteroidal Anti-inflammatory Eye Drops. *Ophthalmology* 2014; 121:1915-1924.
- Wolfensberger TJ. (1999) *The role of carbonic anhydrase inhibitors in the management of macular edema*. Kluwer Academic Publishers.
- Schatz H, Madeira D, McDonald HR, et al. Progressive enlargement of laser scars following grid laser photocoagulation for diffuse diabetic macular edema. *Archives of ophthalmology (Chicago, Ill.: 1960)* 1991; 109:1549-51.
- Maeshima K, Utsugi-Sutoh N, Otani T, et al. Progressive enlargement of scattered photocoagulation scars in diabetic retinopathy. *Retina (Philadelphia, Pa.)* 2004; 24:507-11.
- Nishijima K, Ng YS, Zhong L, et al. Vascular endothelial growth factor-A is a survival factor for retinal neurons and a critical neuroprotectant during the adaptive response to ischemic injury. *American Journal of Pathology* 2007; 171:53-67.
- Galiano RD, Tepper OM, Pelo CR, et al. Topical Vascular Endothelial Growth Factor Accelerates Diabetic Wound Healing through Increased Angiogenesis and by Mobilizing and Recruiting

- Bone Marrow-Derived Cells. *The American Journal of Pathology* 2004; 164:1935–1947.
12. Phulke S, Kaushik S, Kaur S, et al. Steroid-induced Glaucoma: An Avoidable Irreversible Blindness. *Journal of current glaucoma practice* 2017; 11:67–72.
 13. Gaudana R, Ananthula HK, Parenky A, et al. Ocular drug delivery. *The AAPS journal* 2010; 12:348–60.
 14. Abcouwer SF, Gardner TW. Diabetic retinopathy: loss of neuroretinal adaptation to the diabetic metabolic environment. *Annals of the New York Academy of Sciences* 2014; 1311:174–90.
 15. Bastion MLC, Ling KP. Topical insulin for healing of diabetic epithelial defects?: A retrospective review of corneal debridement during vitreoretinal surgery in Malaysian patients. *The Medical journal of Malaysia* 2013; 68:208–16.
 16. Xuan B, McClellan DA, Moore R, et al. Alternative Delivery of Insulin via Eye Drops. *Diabetes Technology & Therapeutics* 2005; 7:695–698.
 17. Wang AL, Weinlander E, Metcalf BM, et al. Use of Topical Insulin to Treat Refractory Neurotrophic Corneal Ulcers. *Cornea* 2017; 36:1426–1428.
 18. Liu SX, Chiou GC. Feasibility of insulin eyedrops for human use. *Journal of ocular pharmacology* 1994; 10:587–90.
 19. Pillion DJ, Wang P, Yorks J, et al. Systemic Absorption of Insulin and Glucagon Applied Topically to the Eyes of Rats and a Diabetic Dog. *Journal of Ocular Pharmacology and Therapeutics* 1995; 11:283–295.
 20. Naeser P. Insulin receptors in human ocular tissues. Immunohistochemical demonstration in normal and diabetic eyes. *Upsala journal of medical sciences* 1997; 102:35–40.
 21. Kumagai AK, Glasgow BJ, Pardridge WM. GLUT1 glucose transporter expression in the diabetic and nondiabetic human eye. *Investigative ophthalmology & visual science* 1994; 35:2887–94.
 22. Fort PE, Losiewicz MK, Reiter CEN, et al. Differential Roles of Hyperglycemia and Hypoinsulinemia in Diabetes Induced Retinal Cell Death: Evidence for Retinal Insulin Resistance. Lo ACY, ed. *PLoS ONE* 2011; 6:e26498.
 23. de Moraes G, Layton CJ. Therapeutic targeting of diabetic retinal neuropathy as a strategy in preventing diabetic retinopathy. *Clinical & Experimental Ophthalmology* 2016; 44:838–852.
 24. MacGregor LC, Matschinsky FM. Altered retinal metabolism in diabetes. II. Measurement of sodium-potassium ATPase and total sodium and potassium in individual retinal layers. *The Journal of biological chemistry* 1986; 261:4052–8.
 25. Ottlecz A, Garcia CA, Eichberg J, et al. Alterations in retinal Na^+ , K^+ -ATPase in diabetes: Streptozotocin-induced and zucker diabetic fatty rats. *Current Eye Research* 1993; 12:1111–1121.
 26. Hatou S, Yamada M, Akune Y, et al. Role of insulin in regulation of Na^+ -/ K^+ -dependent ATPase activity and pump function in corneal endothelial cells. *Investigative Ophthalmology and Visual Science* 2010; 51:3935–3942.
 27. Gündüz D, Thom J, Hussain I, et al. Insulin Stabilizes Microvascular Endothelial Barrier Function via Phosphatidylinositol 3-Kinase/Akt-Mediated Rac1 Activation. *Arteriosclerosis, Thrombosis, and Vascular Biology* 2010; 30:1237–1245.
 28. Shin ES, Sorenson CM, Sheibani N. Diabetes and retinal vascular dysfunction. *Journal of ophthalmic & vision research* 2014; 9:362–73.



This work licensed under Creative Commons Attribution