

A Case Report of Hereditary Angioedema: Challenges in Diagnosis and Management

*Alvina Widhani**, Suzy Maria, Rifky Yulian, Anshari Saifuddin Hasibuan, Sukamto Koesnoe

Division of Allergy and Clinical Immunology, Department of Internal Medicine, Faculty of Medicine Universitas Indonesia – Cipto Mangunkusumo Hospital, Jakarta, Indonesia.

***Corresponding Author:**

Alvina Widhani, MD. Division of Allergy and Clinical Immunology, Department of Internal Medicine, Faculty of Medicine Universitas Indonesia – Cipto Mangunkusumo Hospital. Jl. Diponegoro no. 71, Jakarta 10430, Indonesia. Email: alvina.widhani@gmail.com.

ABSTRACT

Hereditary angioedema (HAE) is a rare autosomal dominant genetic disorder which causes bradykinin mediated angioedema. Although it can be life threatening, HAE may be underdiagnosed due to a lack of awareness of the disease and limited access to laboratory testing. Here, we report a case of HAE which was diagnosed only after the patient was referred for COVID-19 vaccination even though he had been experiencing recurrent angioedema for the past 30 years.

Keywords: Hereditary, angioedema, diagnosis, management.

INTRODUCTION

Hereditary angioedema (HAE) is a genetic disorder manifests as intermittent swelling of the skin or mucosal tissue of the upper respiratory and gastrointestinal tracts which can be life-threatening but cannot be predicted. This rare disease has autosomal dominant inheritance.¹ In Indonesia, there are difficulties in the diagnosis and treatment of HAE. Not only is awareness of the disease lacking, but there is also limited access to the laboratory test that can confirm a diagnosis and first line medication for HAE management is unavailable.

CASE ILLUSTRATION

A 48-year-old male was referred to Cipto Mangunkusumo Hospital for evaluation of eligibility for a COVID-19 vaccination. He had a history of recurrent swelling in the face, hands, and feet (**Figure 1**) which had been triggered by fatigue or cold weather ever since he was in

senior high school. His symptoms worsen in the first 24 hours of an attack and then disappear within 3-5 days. They do not improve with an antihistamine or oral corticosteroid. During his most severe attack, he felt shortness of breath which brought him to an emergency ward. The attending doctor told him that he had airway swelling. The first attack he ever experienced was as a teenager.

There has never been any urticaria or other skin lesions. The man had no history of taking an angiotensin-converting enzyme (ACE) inhibitor or non-steroidal anti-inflammatory drugs (NSAIDs) and also no history of food or drug allergy. His mother and siblings also had histories of the same attack (**Figure 2**). When the patient came to the outpatient clinic, his physical examination was normal. Laboratory results showed a normal peripheral blood count, C4 level 4 mg/dL (10–40 mg/dL), and C1 inhibitor 4 mg/dL (21-39 mg/dL). The patient

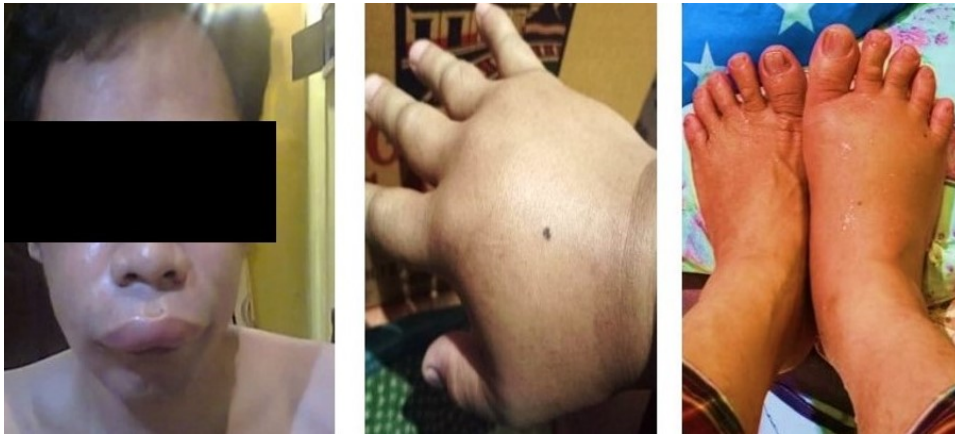


Figure 1. Recurrent angioedema experienced by the patient.

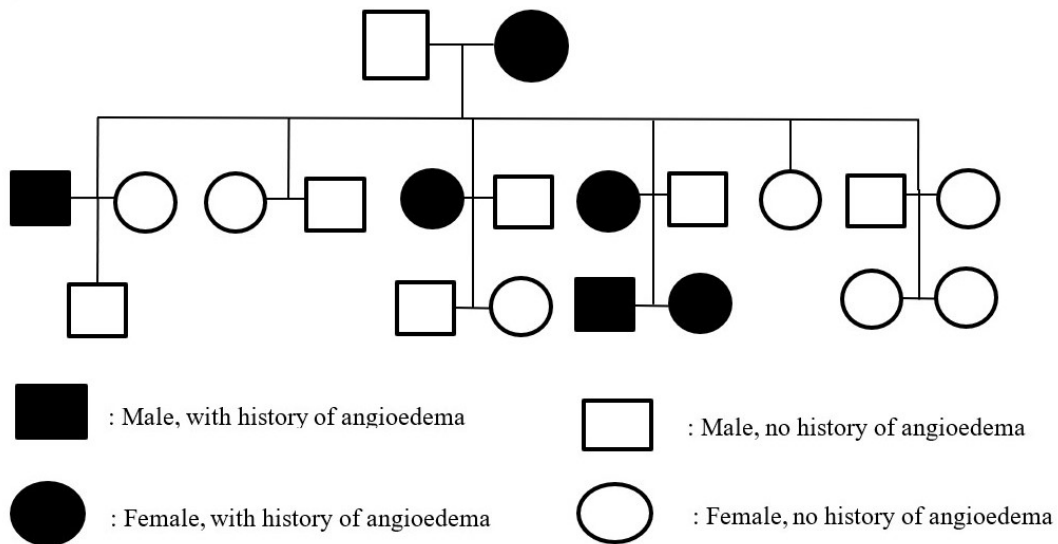


Figure 2. Patient's family tree.

was assisted financially by a foundation to check for C1 inhibitor (INH) as this is not covered by the Indonesia National Insurance because a sample must be sent to a laboratory in the United States by a private laboratory in Indonesia. We diagnosed the patient with type 1 HAE. For long term prophylaxis, we have administered tranexamic acid. After he was given prophylaxis, the patient rarely had angioedema attack (Figure 3). The COVID-19 vaccine, Coronavac, was safely administered in this patient without adverse event following vaccination.

DISCUSSION

Prevalence of HAE globally is approximately 1 in 10,000 to 1 in 50,000 people.² Even though



Figure 3. After prophylaxis, the patient rarely had angioedema attack.

it is rare, the mortality rate from laryngeal edema is about one death for every 20 patients.³ Prevalence of the disease in Indonesia is unknown and possibly underdiagnosed. This case shows a patient that had symptoms for a long time before visiting our clinic for diagnostic work up. He also has family members with similar symptoms who have not planned to visit a doctor because they don't consider it a serious problem. Underdiagnosis of the disease is not only due to a lack of awareness, but there are also problems related to diagnostic tests of C1-INH and C1-INH function because samples must be sent to laboratories outside Indonesia.

Hereditary angioedema is one of the bradykinin mediated angioedema. Angioedema - tissue swelling caused by regional increased in the permeability of blood vessels - can be mediated by bradykinin and/or mast cell mediators including histamine.⁴ Histamine has important role in angioedema associated with wheals, while bradykinin is the most important mediator in angioedema not associated with wheals.²

Bradykinin mediated angioedema can be hereditary or acquired.⁴ Acquired bradykinin mediated angioedema might be caused by drugs, such as ACE inhibitors, angiotensin II receptor blockers (ARB), tissue plasminogen activators, neprilysin inhibitors or gliptins.^{2,4} ACE inhibitor inhibits degradation of bradykinin. Other acquired causes are lymphoma or autoimmune diseases.²

Two types of HAE make up the majority of HAE cases. Type 1 HAE is caused by C1-INH deficiency which lead to decrease of C1-INH level and function. Meanwhile, type 2 HAE has normal or elevated C1-INH level, but low C1-INH function. Type 1 and type 2 HAE are caused by a mutation in gene which code C1-INH (SERPING1). C1-INH is the main inhibitor of mannose binding lectin-associated serine protease, C1s, and C1r (complement proteases). It also inhibits contact-system proteases (coagulation factor XIIa and plasma kallikrein) and plasmin, a protease which dissolves fibrin blood clot.⁴ Mutations in SERPING1 gene for type 1 and type 2 HAE are different. In type 1 HAE, C1-INH cannot be secreted because it is

misfolded. It is caused by insertion, nonsense, deletion, missense, or frameshift in SERPING1 gene. Low C1-INH function seen in type 2 HAE is caused by mutant C1-INH.⁸

Other types of HAE are the result of known or unknown mutation. They show normal C4 and C1-INH levels and functions. The mutations are mutations of the factor XII gene, angiotensin-1 gene, plasminogen gene, kininogen 1 gene, myoferlin gene, or heparan sulfate 3-O-sulfotransferase 6 gene. Deficiency or dysfunction of C1-INH cause increase of bradykinin level then it will activate bradykinin B2 receptors. This condition increases vascular permeability which manifests as angioedema.^{1,4}

Typical manifestation of HAE is swelling of the lips, hands, feet, eyes, or genitals. HAE attack can also cause life-threatening laryngeal edema and abdominal pain.² The attack which can be triggered by procedure, trauma, infection, or stress, lasts for 2-5 days which can resolve without treatment.⁸ Clinicians should suspect for type 1 or type 2 HAE when they find angioedema without wheals which do not improve with antihistamine or steroid.^{2,4} Another supporting data are onset of manifestations in childhood or adolescence, a positive family history, and prodromal signs or symptoms before swellings. To confirm the diagnosis, measurements of C4 and C1-INH level and function are needed.⁴ Our patient had history of swelling in his lips, hands, feet, and upper air way without wheals since adolescence which was not responsive to antihistamines or corticosteroids. This manifestation, with a positive family history and low C4 and C1-INH levels, supports the diagnosis of type 1 HAE in our patient. In one case report, a patient with type 1 HAE can present with atypical manifestation limited to gastrointestinal system (severe abdominal pain with bowel wall oedema and colitis). The patient had a family history for HAE and the laboratory work up showed low C4 level and C1q esterase inhibitor.⁵

Clinicians should know how to manage HAE patients during acute attacks and how to give prophylaxis before procedure or for long term.^{2,6} Medications for treatment or prophylaxis that target the pathway in bradykinin mediated

angioedema include C1-INH replacement, inhibition of the bradykinin B2 receptor, and inhibition of kallikrein which decrease bradykinin production (**Figure 4**).^{1,2,6,7} Low or dysfunctional C1-INH can be treated with plasma-derived or recombinant C1-INH which has similar target with endogenous C1-INH. Bradykinin-mediated angioedema cannot be treated with antihistamine, steroid, and epinephrine.^{1,4}

First line medication for long time prophylaxis is plasma-derived C1-INH. Other choices are lanadelumab and berotralstat. Lanadelumab is a fully human antiactive plasma kallikrein monoclonal antibody which can be given subcutaneously. Meanwhile berotralstat is an oral plasma kallikrein inhibitor. Attenuated androgens (danazol) have also been used for long-term prophylaxis, but there are dose-related side effects related to its androgenic and anabolic effects.⁴ The dose of danazol varies between 100 mg every other day and 200 mg three times daily (2.5-10mg/kg/d, max 600mg).^{4,6} Due to side effects, danazol more than 200 mg daily is not recommended for long term treatment. Danazol increases C1-INH produced by the liver and C1-INH messenger RNA expression in circulating monocytes. It is not useful for acute attack because danazol takes 1-2 days to have

effect.¹ When first-line prophylactic treatment is not available and androgens are contraindicated, antifibrinolytics, such as tranexamic acid, can be used.⁴ Antifibrinolytic inhibits plasminogen conversion to plasmin. This condition decrease activation of FXII.¹ Contraindications/precautions for antifibrinolytics are high thrombotic risk, thrombophilia, or acute thrombosis. Dosage of tranexamic acid is between 30 and 50 mg/kg of body weight daily, which can be divided into two or three doses with a maximum of 6 g per day.⁴ In the case of this study, because the first-line medication for long term prophylaxis is not available in Indonesia, we chose to administer tranexamic acid rather than attenuated androgen because of its fewer side effects.

We also educated the patient about the preparations he would need to do if he planned to undergo a procedure involving the upper aerodigestive tract. For preprocedural short-term prophylaxis in procedures related to the upper aerodigestive tract, the first line recommendation is intravenous plasma-derived C1-INH (pdC1-INH). If intravenous pdC1-INH cannot be given, recombinant human C1-INH (rhC1-INH) can be considered. If this medication is also unavailable, fresh frozen plasma (FFP) is an alternative option. Attenuated androgens (eg, danazol) can also be

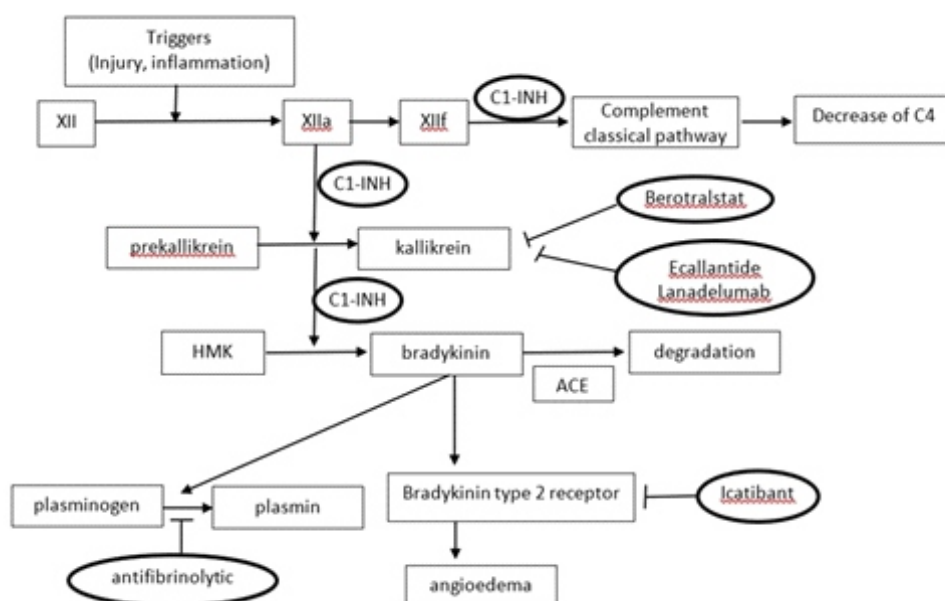


Figure 4. Bradykinin mediated angioedema pathway and treatment modalities in hereditary angioedema. C1-INH: C1 inhibitor; ACE: angiotensin converting enzyme.

used for scheduled preprocedural prophylaxis as it is given 5 days before the procedure and 2–3 days post procedure. In the past, tranexamic acid has been used for preprocedural prophylaxis, however it is not recommended by most guideline experts.⁴ Because first line short time prophylaxis is not available in Indonesia, the alternatives are FFP and attenuated androgen.

For acute attack, especially one affecting the upper airway, the treatments of choice are icatibant (bradykinin-receptor antagonist), ecallantide (kallikrein inhibitor), and intravenous C1-INH. If these first-line options are not available, solvent detergent-treated plasma (SDP) can be given for acute attack. If SDP is also not available, FFP is the alternative.⁴ The available treatment option in Indonesia for acute attack is FFP.

Educating patients about HAE is also an important part of HAE management. Although most HAE attacks are unpredictable, the patient should be informed about avoiding triggers and consider long term prophylaxis. HAE attacks can be triggered by trauma, estrogen-containing oral contraceptive agents, estrogen hormone replacement therapy, ACE inhibitors, fatigue, menstrual cycle, febrile illness, and psychological stress. It is also important to educate family members displaying similar symptoms and encourage them to visit a doctor for HAE work up. It is recommended that family members of type 1 and type 2 HAE patients are screened for C4 level and C1-INH level and function because this medical condition has autosomal dominant inheritance.⁴

There is concern that COVID 19 vaccine can trigger angioedema attack because it shows more side effects (fatigue, pain, fever) than other vaccine. Study by Fijen et al.⁹ reported that of the 111 doses of COVID 19 vaccine administered, there were 11 angioedema attacks with nine attacks happened after first dose. All attacks were mild or moderate and no hospitalization or laryngeal edema. One attack happened in patient that was already given pre procedural prophylaxis with danazol. Four attacks happened in patient that were taking long term prophylaxis with intravenous C1-INH. Eight attacks were treated with intravenous C1-INH. In this study,

COVID 19 vaccine platform given were mRNA-1273 (Moderna), BNT162b2 (Pfizer-BioNTech), ChAdOx1 nCov-19 (AstraZeneca), and Ad26.COV2-S (Janssen). There were 8 attacks from 38 patients who got Pfizer-BioNTech vaccine, 2 attacks from 10 patients with Moderna vaccine, 1 attack from 6 patients with Jansen vaccine, and none from 9 patients with AstraZeneca vaccine. Our patient got Coronavac vaccine, an inactivated COVID 19 vaccine, which has different platform with COVID-19 vaccine given in the study by Fijen et al. Although our patient did not report any adverse event following vaccination, more data is needed to know whether inactivated vaccine is safer than other COVID 19 vaccine platform for patient with HAE.

CONCLUSION

Although HAE is a rare genetic disease, it can be life threatening. To improve its detection and management, awareness and knowledge of physicians needs to be increased. HAE might be underdiagnosed because of limited access to the required laboratory test, which is an issue that should be addressed by health care providers. Until now, first line treatment and prophylaxis for HAE are not available in Indonesia, probably because of unknown demand due to limited detection.

REFERENCES

1. Wilkerson RG, Moellman JJ. Hereditary angioedema. *Emerg Med Clin North Am.* 2022;40:99–118.
2. Jindal AK, Bishnoi A, Dogra S. Hereditary angioedema: Diagnostic algorithm and current treatment concepts. *Indian Dermatol Online J.* 2021;12(6):796–804.
3. Minafra FG, Goncalves TR, Alves TM, Pinto JA. The mortality from hereditary angioedema worldwide: A review of the real-world data literature. *Clin Rev Allergy Immunol.* 2022; 62(1):232-9.
4. The international WAO/EAACI guideline for the management of hereditary angioedema—The 2021 revision and update. *World Allergy Organ J.* 2022; 15(3):100627.
5. Soni P, Kumar V, Alliu S, Shetty V. Hereditary angioedema (HAE): a cause for recurrent abdominal pain. *BMJ Case Rep.* 2016; 2016: bcr2016217196.
6. Zafra H. Hereditary angioedema: a review. *WMJ.* 2022;121(1):48-53.
7. Kaplan AP, Joseph K. Complement, kinins, and hereditary angioedema: mechanisms of plasma instability when C1 inhibitor is absent. *Clinic Rev Allerg Immunol.* 2016;51:207–15.

8. Abdulkarim A, Craig TJ. Hereditary angioedema. In: StatPearls [Internet]. Treasure Island (FL): StatPearls Publishing; 2022.
9. Fijen LM, Levi M, Cohn DM. COVID-19 vaccination and the risk of swellings in patients with hereditary angioedema. *J Allergy Clin Immunol Pract* 2021;9(11):4156-8.