

Adult-onset Still's Disease as a Differential Diagnosis in Prolonged Fever: Diagnosis and Treatment Experience

Felix F. Widjaja¹, Diah Martina¹, Soroy Lardo², Suryo A. K. Wibowo¹

¹ Department of Internal Medicine, Faculty of Medicine Universitas Indonesia - Cipto Mangunkusumo Hospital, Jakarta, Indonesia.

² Department of Internal Medicine, Indonesia Army Central Hospital Gatot Soebroto, Jakarta, Indonesia.

Corresponding Author:

Suryo Anggoro Kusumo Wibowo, MD. Division of Rheumatology, Department of Internal Medicine, Faculty of Medicine Universitas Indonesia - Cipto Mangunkusumo Hospital. Jl. Diponegoro no. 71, Jakarta 10430, Indonesia. email: dr.suryoipd@gmail.com; felixfw@gmail.com.

ABSTRAK

Adult onset Still's disease merupakan penyakit sistemik jarang yang melibatkan berbagai organ serta menyerupai penyakit lain seperti infeksi, penyakit autoimun dan juga keganasan. Diagnosis dan pengobatan belum terlalu baik karena penyakit ini jarang. Meskipun demikian, sudah terdapat beberapa kriteria diagnosis yang dapat membantu. Kami memaparkan suatu kasus, pria berusia 36 tahun datang dengan demam tinggi terus menerus yang pertama kali dianggap sebagai infeksi. Pasien juga mengalami nyeri sendi pergelangan tangan dan lutut unilateral disertai ruam makulopapular. Pemeriksaan laboratorium menunjukkan leukosit tinggi dengan hitung jenis netrofil polimorfonuklear tinggi, trombosit tinggi, feritin tinggi, dan berbagai penanda infeksi negatif (antibodi tifoid, prokalsitonin, malaria, kultur darah, kultur urin, IgM pneumonia, ASTO, tes sifilis, antiHIV, HBsAg, antiHCV dan sebagainya). Rontgen dada, rontgen sendi, ultrasonografi, dan ekokardiografi menunjukkan hasil normal. Pasien ini kemudian didiagnosis adult onset Still's disease dan diberikan metilprednisolon intravena dan demam hilang dalam tiga hari. Enam bulan kemudian pasien mengeluhkan nyeri sendi dan diberikan metotretksat, kemudian nyeri membaik.

Kata kunci: *adult onset Still's disease, demam berkepanjangan, diagnosis, penatalaksanaan.*

ABSTRACT

Adult onset Still's disease is a rare systemic disease that may involve many organs and may mimic many disease such as infection, autoimmune disease, and also malignancy. The diagnostic approach and treatment strategies have not been well established due to its rarity; however, there are some diagnostic criteria that may help. We present a case of 36-year old man who experienced high prolonged fever which firstly thought as infection. He also had unilateral wrist and knee joint pain and maculopapular rash. Laboratory examination showed high leukocytes count with elevated polymorphonuclear neutrophil count, high platelet count, high ferritin levels, and negative results of many infection markers (typhoid antibody, procalcitonin, malaria test, blood culture, urine culture, IgM pneumonia, ASTO, syphilis test, antiHIV, HBsAg, antiHCV, etc). Chest X-ray, joint X-ray, ultrasonography, and echocardiography showed normal result. The patient was then diagnosed with Adult-onset Still's disease and received intravenous methylprednisolone and the fever was disappeared in 3 days. Six months later the arthralgia appeared again, methotrexate was administered and the pain was then relieved.

Keywords: *adult onset Still's disease, prolonged fever, diagnosis, treatment.*

INTRODUCTION

Adult-onset Still's disease (AOSD) is a rare rheumatic disease which involves systemic inflammation in young adults.¹ The disease may be tricky to diagnose and can be mistakenly thought as infectious disease. Fever with high levels of leukocytosis, a hallmark of AOSD, may also suggest the diagnosis of infection. Therefore, AOSD should also be included in the differential diagnosis of prolonged fever or fever of unknown origin.²

AOSD is a complex autoinflammatory disorder.³ It could not be included as pure autoinflammatory disease that affect mostly in innate immune system; meanwhile it may be triggered by autoimmune.⁴ Thus, it is not an autoinflammatory nor autoimmune disease, but it has been put in the middle of autoinflammatory and autoimmune disease.³

The difficulty in the diagnosis of AOSD may lead to mistreatment and in further context, it can make both patients and physicians become desperate since the true cause of the fever remains unknown due to the wide spectrum of the clinical features.⁵ The estimated incidence of AOSD from the literature ranges from 0.16 to 0.44 per 100,000 persons worldwide.^{3,6} The main characteristics of AOSD are triad of high spiking fever, salmon-colored skin rash, and joint pain.^{4,5} Viral infection may cause similar clinical picture of rash called viral exanthem with different characteristics. Hence, AOSD is still a diagnosis of exclusion and a definitive diagnosis should only be made after we rule out infection, autoimmune disease, and malignancy.⁴

In this article, we present a patient with AOSD that at first was wrongly thought as typhoid fever. The symptom of arthralgia may disappear by itself and may relapse, which reduces patient's quality of life. We would also like to share our treatment strategies and good treatment response of our patient.

CASE ILLUSTRATION

A 36-year-old man came to our hospital because of fever for a week before hospital admission. He felt higher grade of fever at night with duration of three to five hours and felt better after taking acetaminophen. He also

experienced joint pain on his right shoulder and then the pain was spreading to right knee. It was also heavier when the joint was moved. There was no other complaint and the patient had no history of other illness. On physical examination, we found increased body temperature at night and it reached 40°C, but then for the rest of the day the temperature returned to normal. There was no palpable lymph node enlargement. In the affected joint, there was tenderness and limited range of motion with no swollen joint and redness. Physical examination of other organs revealed normal results.

In the early days of hospital admission, the laboratory examination revealed leukocytosis, high levels of platelet counts, and high levels of erythrocyte sedimentation rate (ESR). The liver and renal function as well as glucose levels were normal. Examinations on rheumatoid factor, ASTO, and urinalysis showed normal results. Results of radiographic examinations of the chest, left and right knee joint were normal (**Figure 1**). Infection was firstly suspected as the source of the fever since the patient had fever accompanied with leukocytosis; however, the source of infection was assumed to be unknown. Third-generation of cephalosporin antibiotic was given as empiric treatment along with acetaminophen.

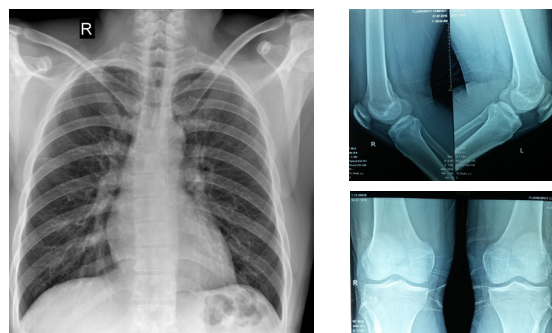


Figure 1. X-ray examination of thorax and right knee at admission showed no abnormality.

On the fourth day, the patient's leukocyte count was still high, CRP levels was high, typhoid antibody test revealed negative results and procalcitonin levels was normal; but the fever still persisted. Blood culture was performed and the antibiotic treatment was continued. Urinalysis and feces analysis was repeated and

the results were normal. New rash was found on his back and it was consulted to dermatologist and he was diagnosed as viral exanthema. The patient was given topical corticosteroid.

On the seventh day, CRP was still high and platelet count was elevated again. Evaluations on the possibility of hepatitis B, hepatitis C, and HIV infection revealed negative results. There was new joint pain on the patient's left wrist without any visible swollen joint. Diclofenac at a dose of 25 mg twice daily was given and the pain was relieved. The rash on his back resolved (**Figure 2**). Results of malaria test were also negative. Abdominal ultrasonography revealed no abnormality. Blood culture showed negative result on ninth day.

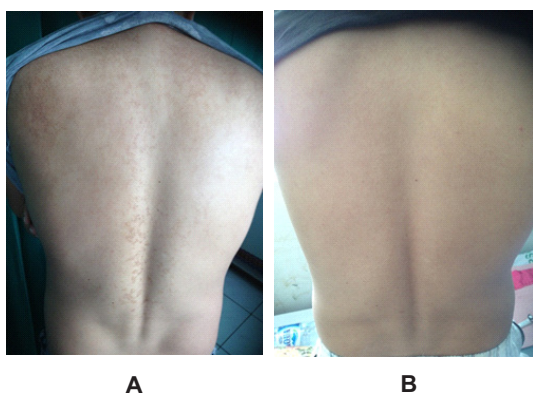


Figure 2. Rash at the back two days after administration of topical corticosteroid (A). Rash completely dissolved after four days administration (B).

On the tenth day, there was a new rash on lower trunk (**Figure 3**). After we had ruled out several infections, AOSD was suspected. Ferritin levels was high (>1200 ng/mL) and ANA was negative. Serum iron and TIBC were normal. Thus, we gave intravenous methylprednisolone at the dose of 62.5 mg daily (approximately 1mg/kgBB/day) and we found that the duration of fever was shorter. After three days, the fever disappeared. Leukocyte and platelet counts were within normal limit.

The patient then underwent another examination outside of our center for seeking a second opinion. Additional laboratory examinations such as syphilis antibody, anti CCP, antibody O tsutsugamushi, IgM chingkungunya, and IgM leptospira revealed negative results and free T4, TSH were within normal limit.

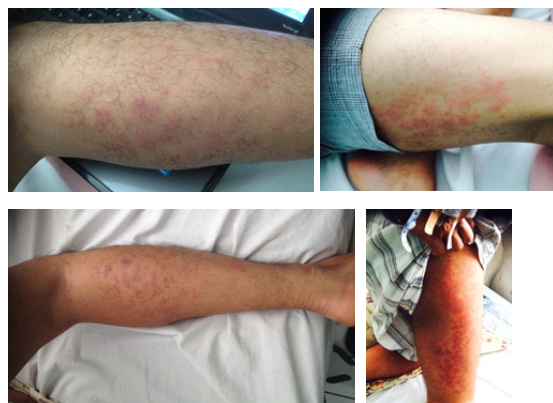


Figure 3. Salmon skin rash at back thigh.

Gamma-glutamyl transpeptidase levels was 140U/L, ALT/AST levels were high (425/274 U/L). Examinations on SS-A, SS-B, RNP, Sm, Scl-70, Jo 1 also showed negative results. Echocardiography was also normal. Urine culture also showed negative result. Evaluations on ANCA and IgM *M. pneumoniae* also revealed negative results.

In the second month, the patient underwent bone marrow aspiration and showed normal morphologic findings with no suggestive result for any primary marrow disorder. In that center, this patient was treated with low dose corticosteroid but the patients had only consumed it for three months because he felt better and decided to stop the medication himself. Fever was only felt once over two months period after the first injection of methylprednisolone was given. **Table 1** shows results of the laboratory examinations till the second month.

In the third month, he started to complain of bilateral wrist joint pain, but the pain had a good response to NSAID treatment. In the sixth month, the patient came back to our center and the pain had got much better, but it still relapsed occasionally. At this time, the laboratory examination revealed following results: leukocyte count of 8990 cells/ μ L, platelet count of 492000 cells/ μ L, ESR of 34 mm/hour, CRP levels of 44.5 mg/L, ferritin levels of 442 ng/mL. The radiographic examination also showed no abnormality (**Figure 4**). Considering his condition, methotrexate was given at the dose of 7.5 mg weekly to overcome his joint pain and he had good response to the treatment. After two

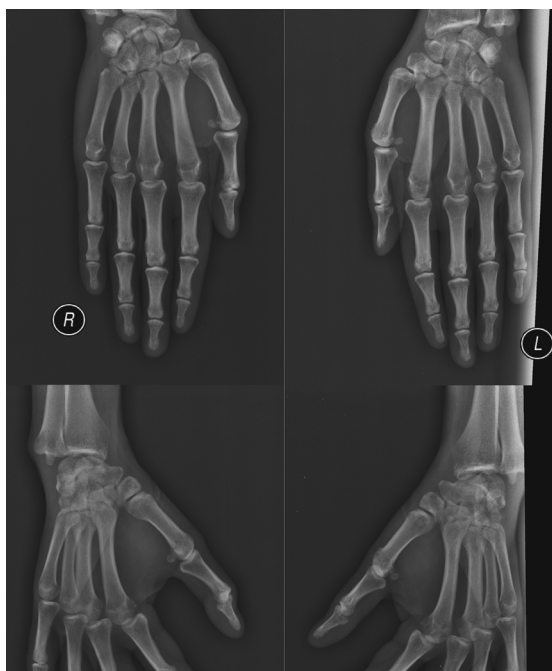

Figure 4. X-ray of wrist joint showed no abnormality.

weeks of treatment, the joint pain got better and his ferritin levels became 216 ng/mL with CRP levels of 14.7mg/L and ESR of 25 mm/hour.

DISCUSSION

AOSD mainly occurs in young adults with a peak incidence in subjects at thirties age group as our patient who was at his 41 years of age; however, it also may occur in older age up to 83 years.³ The rare incidence made this disease is often mistakenly regarded as other disease. It has been stated that woman predominates AOSD.^{3,6}

There are four clues that can help us in diagnosing the disease: spiking fever, neutrophilic leukocytosis, joint pain, and salmon-pink-colored maculopapular rash.⁶ Approach

to patients with prolonged fever and fever of unknown origin may help us in considering AOSD.² There are some criteria that can be used to establish the diagnosis of AOSD: Cush criteria,⁷ Yamaguchi criteria,⁸ and Fautrel criteria.⁹ The criteria can be seen in **Table 2**.

Our patient has fulfilled the Cush diagnostic criteria of AOSD (fever of $\geq 39^{\circ}\text{C}$, arthralgia, negative rheumatoid factor, negative ANA, salmon-colored skin rash, and leukocytosis of $\geq 15,000$ cells/ mm^3). The later findings of high AST/ALT levels may also be ruled in the Yamaguchi criteria. Although we did not examine glycosylated ferritin levels of our patient, but he also fulfilled the Fautrel criteria (major criteria: spiking fever $\geq 39^{\circ}\text{C}$, arthralgia, transient erythema, PMN $\geq 80\%$; minor criteria: maculopapular rash, leukocytes $> 10,000$ cells/ μL).

Spiking fever means very high temperature at evening and becomes normal in the morning.¹⁰ It is a typical symptom of AOSD that had been found in our patient. Moreover, the rash found in our patient was transient, which was suggestive of AOSD (**Figure 2**).⁶ Our patient also had a unique macular salmon-colored rash, which involved common area (trunk and limbs).^{3,11}

Acute rheumatic fever as differential diagnosis should be kept in mind when dealing with patient complaining fever and arthralgia. Using the revised Jones criteria,¹² this patient had fulfilled one major criterion (migratory polyarthralgia) and two minor criteria (fever and abnormality of ESR and/or CRP). Although it often happens in children, but there is a case report of 45-year-old woman with acute rheumatic fever.¹³ Our patient had negative results of ASTO and blood culture examinations

Table 1. Laboratory examination

	D-1	D-3	D-5	D-7	D-9	D-10	D-15	D-16	D-19	D-40
Hb (g/dL)	14.8	12.7	13	12.5	12.2	12.3	12.2	12.9		11.7
Leukocyte count (cells/ μL)	27420	20440	20760	21060	16940	20490	10080	7130		20300
Neutrophil	87%	87%			90%		93%	53%		89%
Lymphocyte	8%	8%			6%		5%	19%		8%
Platelet (1000cells/ μL)	462	387	410	448	440	437	350	323		640
ESR (mm/hour)	92							64	82	100
CRP (mg/L)		318		348				47.9	167.5	156.4
PCT (ng/mL)		0.24							0.28	0.14

Hb: hemoglobin; ESR: erythrocyte sedimentation rate; CRP: C-reactive protein; PCT: procalcitonin; D: day

and his echocardiography revealed no evidence of carditis.

Procalcitonin (PCT) measurement may help to differentiate bacterial infection. Patients with AOSD usually have extremely high CRP levels and high leukocyte count with low PCT, which similar to our findings in our patient. The same features can also be seen in patients with crystal arthritis or in malignancy. In patients with malaria, PCT may increase significantly; while in those with tuberculosis, their PCT may be normal. Unfortunately, endocarditis may also give normal PCT value; therefore, normal PCT measurement could not be used to exclude acute rheumatic fever, but it can rule out the possibility of systemic bacterial infection.¹⁴

High ferritin is also a hallmark for the diagnosis of AOSD. It is also suggested for evaluating prolonged fever when there is no clue for specific diagnosis.² Ferritin with a cut-off of five times normal value is suggestive of AOSD with specificity (41 to 46%).³ Glycylated ferritin (GF) is said to be more specific; and therefore, Fautrel put it as one of the diagnostic

criteria. GF $\leq 20\%$ has higher specificity of 64% and when it is combined with hyperferritinemia, the specificity becomes 84%.⁶

High ferritin is also related with macrophage activation syndrome (MAS) associated with AOSD; therefore, it should be addressed cautiously.¹ Meanwhile, serum vitamin B12 levels may also be a marker for MAS in AOSD.¹⁵ This patient had ferritin levels of at least three times normal limit. Such findings may occur due to the limited capacity of the laboratory that could only report result of ferritin levels of more than 1200 ng/mL. Unfortunately, the glycylated ferritin and vitamin B12 levels could not be performed in this patient due to limited facility.

Patient with higher ferritin has worse prognosis.¹⁶ A literature review has suggested that patients with high ferritin levels (20,000 ng/mL) had worse outcome than those with lower levels (4100 ng/mL); however, it may return to normal levels.⁵ Moreover, ferritin measurement may also be used to monitor treatment response and it may be normal in patients with remission,¹⁷ which was shown in this patient, in which he had

Table 2. Some criteria of adult-onset Still's disease

Criteria	Cush ⁷	Yamaguchi ⁸	Fautrel ⁹
Major	<ul style="list-style-type: none"> - Fever $\geq 39^{\circ}\text{C}$ - Arthralgias and/or arthritis - RF titer $<1:80$ - ANA titer $<1:100$ 	<ul style="list-style-type: none"> - Fever $\geq 39^{\circ}\text{C}$ lasting ≥ 1 week - Arthralgia lasting ≥ 2 weeks - Typical skin rash - Leukocytosis $\geq 10,000/\text{mm}^3$ with PMN $\geq 80\%$ 	<ul style="list-style-type: none"> - Spiking fever $\geq 39^{\circ}\text{C}$ - Arthralgia - Transient erythema - Pharyngitis - PMN $\geq 80\%$ - Glycylated ferritin $\leq 20\%$
Minor	<ul style="list-style-type: none"> - Leukocytosis ($>15,000$ cells/mm^3) - Juvenile rheumatoid arthritis rash - Serositis (pleuritis or pericarditis) - Evidence of RES involvement 	<ul style="list-style-type: none"> - Pharyngitis or sore throat - Liver enzyme abnormalities (aminotransferase) - Negative for RF or ANA 	<ul style="list-style-type: none"> - Maculopapular rash - Leukocytosis $\geq 10,000/\text{mm}^3$
Exclusion criteria	None	<ul style="list-style-type: none"> - Absence of infection, especially sepsis and Epstein-Barr viral infection - Absence of malignant diseases, especially lymphomas - Absence of inflammatory disease, especially polyarteritis nodosa 	None
Diagnosis	Four major criteria with two minor criteria	At least five criteria, including two major criteria and no exclusion criteria	Four major criteria OR three major and two minor criteria
Sensitivity	None	96.2%	80.6%
Specificity	None	92.1%	98.5%

RF: rheumatoid factor; ANA: antinuclear antibody; RES: reticuloendothelial system (hepatomegaly, splenomegaly, generalized lymphadenopathy); PMN: polymorphonuclear neutrophil; Typical rash: maculopapular, non-pruritic, salmon-pink rash with concomitant fever spikes

lower ferritin when the fever subsided.

Since the diagnosis of AOSD should be made by exclusion, 18F-FDG PET/CT, PET scanner may aid the diagnosis to exclude lymphoma, tuberculosis, or sarcoidosis and increased uptake is found in patients with arthritis.¹⁸ Unfortunately, PET scan was not performed to this patient due to limited facilities.

AOSD may be treated with aspirin, NSAIDs, corticosteroids, DMARDs (methotrexate, azathioprine, naproxen, mycophenolate mofetyl, intravenous immunoglobulin), biologic agents (TNF-inhibitor (infliximab, etanercept), anti B-cell agents, IL-1 receptor antagonist (anankira), anti-IL-6 receptor monoclonal antibody.¹⁷ Several reviews have recommended that the main treatment of AOSD is corticosteroid.^{3,6,19} The dose should be at 0.5-1mg/kg/day and intravenous administration will give quick result within a couple of hours or a few days.^{3,6} In this patient, the fever resolved only in three days after corticosteroid treatment had been initiated. The treatment should be given at the dose of 0.5-1mg/kg/day for 4 to 6 weeks and then tapered off.³ Unfortunately, this patients did not comply with the prescription. Three months after stopping corticosteroid treatment, he felt a joint pain again and when he got back to our center, corticosteroid was given for the induction again plus low dose of methotrexate as the second line treatment.⁶

As the patient got another joint pain, DMARD may be used for refractory period in addition to the combination of NSAIDs and prednisone. It was used to suppress joint destruction and methotrexate at the dose of 7.5 mg/week could lower the use of steroid, which provides successful outcome for at least a year.¹⁷ Methotrexate also works systemically as AOSD is a systemic disease. Another study has reported that methotrexate at the dose of 7.5 to 17.5 mg/week can control AOSD in more than 60% patients who are steroid-dependent. The presence of abnormal liver enzyme levels should not be a contraindication for methotrexate treatment, but the patients should be monitored closely.³ Another DMARDs that may be used in AOSD, but with lower success are cyclosporine A, hydroxychloroquine, azathioprine, cyclophosphamide, penicillamine, and gold.¹⁷

Biological agents may become an option for refractory AOSD.^{4,6,17,19} Unfortunately, there is no uniform definition for refractory AOSD; therefore, when considering biological agents, the treatment should be individualized for each patient and depends on clinical experience of each center.

CONCLUSION

AOSD is a rare rheumatic disease with the triad classical symptoms of high-spiking fever, salmon-colored skin rash, and joint pain. AOSD should be considered in the differential diagnosis of prolonged fever or fever of unknown origin. The diagnosis is mainly diagnosis of exclusion; however, high ferritin levels may aid the diagnosis. The treatment is mainly steroid and DMARD, as well as methotrexate whenever necessary.

REFERENCES

1. Ruscitti P, Cipriani P, Di Benedetto P, et al. Increased levels of H-ferritin and its imbalance with L-ferritin, in bone marrow and liver of patients with adult onset Still's disease, developing macrophage activation syndrome, correlate with the severity of the disease. *Autoimmun Rev.* 2015;14:429-37.
2. Hersch EC, Oh RC. Prolonged febrile illness and fever of unknown origin in adults. *Am Fam Physician.* 2014;90:91-6.
3. Gerfaud-Valentin M, Jamilloux Y, Iwaz J, Seve P. Adult-onset Still's disease. *Autoimmun Rev.* 2014;13:708-22.
4. Maria AT, Le Quellec A, Jorgensen C, Touitou I, Riviere S, Guilpain P. Adult onset Still's disease (AOSD) in the era of biologic therapies: dichotomous view for cytokine and clinical expressions. *Autoimmun Rev.* 2014;13:1149-59.
5. Narula N, Narula T, Abril A. Seizing the clinical presentation in adult onset Still's disease. An extensive literature review. *Autoimmun Rev.* 2015;14:472-7.
6. Fautrel B. Adult-onset Still disease. *Best Pract Res Clin Rheumatol.* 2008;22:773-92.
7. Cush JJ, Medsger TA, Jr., Christy WC, Herbert DC, Cooperstein LA. Adult-onset Still's disease. Clinical course and outcome. *Arthritis Rheum.* 1987;30:186-94.
8. Yamaguchi M, Ohta A, Tsunematsu T, et al. Preliminary criteria for classification of adult Still's disease. *J Rheumatol.* 1992;19:424-30.
9. Fautrel B, Zing E, Golmard JL, et al. Proposal for a new set of classification criteria for adult-onset still disease. *Medicine (Baltimore).* 2002;81:194-200.

10. Bywaters EG. Still's disease in the adult. *Ann Rheum Dis.* 1971;30:121-33.
11. Mahroum N, Mahagna H, Amital H. Diagnosis and classification of adult Still's disease. *J Autoimmun.* 2014;48-49:34-7.
12. Gewitz MH, Baltimore RS, Tani LY, et al. Revision of the Jones criteria for the diagnosis of acute rheumatic fever in the era of Doppler echocardiography: a scientific statement from the American Heart Association. *Circulation.* 2015;131:1806-18.
13. Oba Y, Watanabe H, Nishimura Y, et al. A Case of Adult-Onset Acute Rheumatic Fever With Long-Lasting Atrioventricular Block Requiring Permanent Pacemaker Implantation. *Int Heart J.* 2015;56:664-7.
14. Delevaux I, Andre M, Colombier M, et al. Can procalcitonin measurement help in differentiating between bacterial infection and other kinds of inflammatory processes? *Ann Rheum Dis.* 2003;62:337-40.
15. Kalyoncu U, Buyukasik Y, Akdogan A, et al. Increased serum vitamin B12 levels are associated with adult-onset Still's disease with reactive macrophage activation syndrome. *Joint Bone Spine.* 2010;77:131-4.
16. Colina M, Zucchini W, Ciancio G, Orzincolo C, Trotta F, Govoni M. The evolution of adult-onset Still disease: an observational and comparative study in a cohort of 76 Italian patients. *Semin Arthritis Rheum.* 2011;41:279-85.
17. Efthimiou P, Georgy S. Pathogenesis and management of adult-onset Still's disease. *Semin Arthritis Rheum.* 2006;36:144-52.
18. Roy SG, Karunanithi S, Dhull VS, Bal C, Kumar R. (1)(8)F-FDG PET/CT aids the diagnosis of adult onset Still's disease in a patient with fever of unknown origin. *Rev Esp Med Nucl Imagen Mol.* 2014;33:392-3.
19. Pouchot J, Arlet JB. Biological treatment in adult-onset Still's disease. *Best Pract Res Clin Rheumatol.* 2012;26:477-87.