

# Giant Recurrence Pituitary Adenoma After Three Times Transphenoidal Removal Surgery, One Craniotomy Procedure, and 30 Doses of External Radiotherapy

*Laurentius A. Pramono<sup>1,2</sup>, Em Yunir<sup>1</sup>, Tri Juli E. Tarigan<sup>1</sup>, Syntia Nusanti<sup>3</sup>, Renindra A. Aman<sup>4</sup>, Indrati Suroyo<sup>5</sup>*

<sup>1</sup>Department of Internal Medicine, Faculty of Medicine Universitas Indonesia – Cipto Mangunkusumo Hospital, Jakarta, Indonesia.

<sup>2</sup>Department of Public Health and Nutrition, School of Medicine and Health Sciences Universitas Katolik Indonesia Atma Jaya – Department of Internal Medicine St Carolus Hospital, Jakarta, Indonesia.

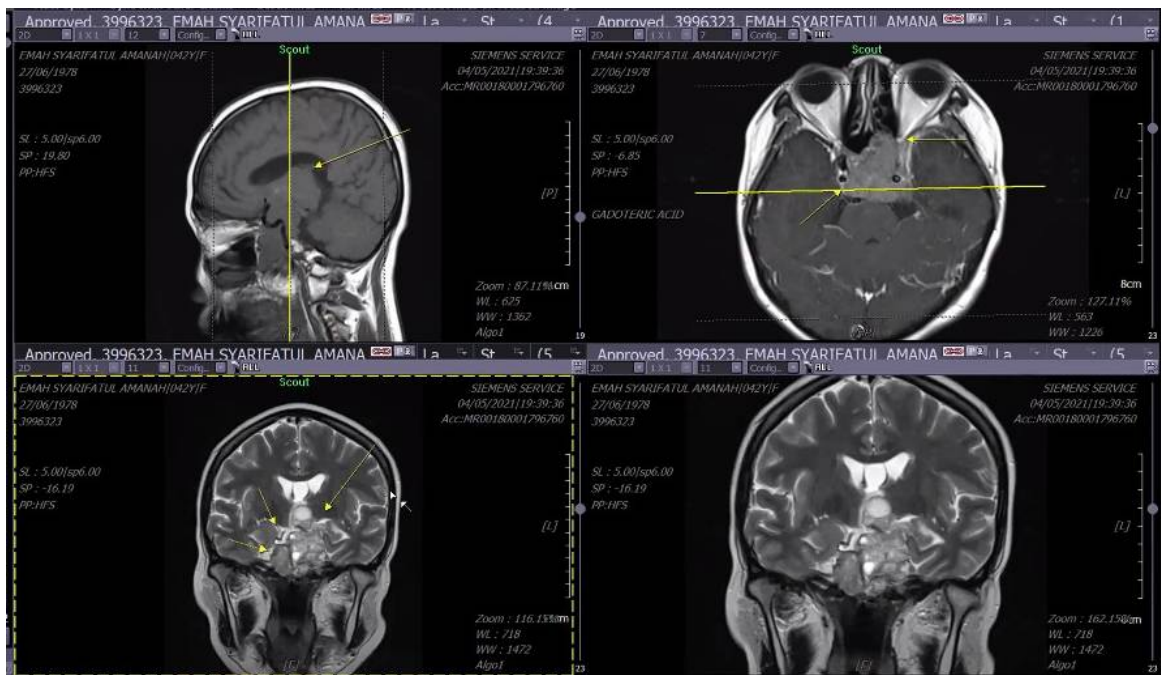
<sup>3</sup>Department of Ophthalmology, Faculty of Medicine Universitas Indonesia – Cipto Mangunkusumo Hospital, Jakarta, Indonesia.

<sup>4</sup>Department of Neurosurgery, Faculty of Medicine Universitas Indonesia – Cipto Mangunkusumo Hospital, Jakarta, Indonesia.

<sup>5</sup>Department of Radiology, Faculty of Medicine Universitas Indonesia – Cipto Mangunkusumo Hospital, Jakarta, Indonesia.

**Corresponding Author:**

*Em Yunir, MD., PhD. Division of Endocrinology and Metabolism, Department of Internal Medicine, Faculty of Medicine Universitas Indonesia – Cipto Mangunkusumo Hospital. Jl. Diponegoro no. 71, Jakarta 10430, Indonesia. email: l\_aswin@hotmail.com*



**Figure 1.** Dynamic pituitary MRI revealed giant recurrence pituitary adenoma after four times surgery and 30 doses of external radiotherapy.

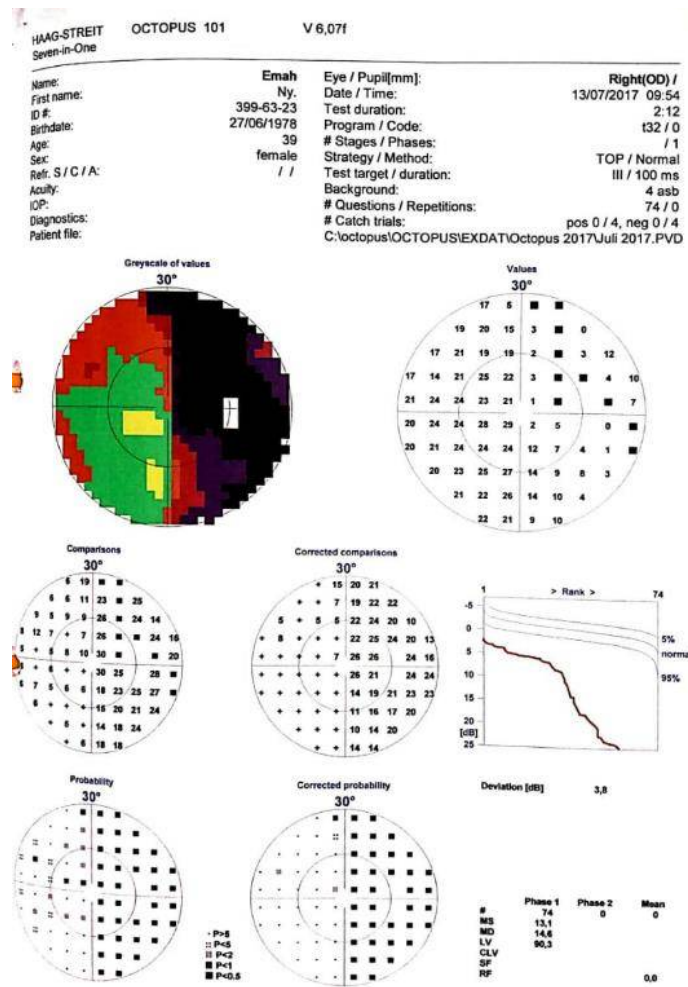


Figure 2. Campimetry assessment revealed bilateral temporal hemianopia.

This is a case of 42<sup>nd</sup> year-old woman with history of sight loss in her both eyes. She experienced headache and visual field decrease gradually since 2014. After several laboratory and imaging examinations, from her dynamic pituitary magnetic resonance imaging (MRI), it is concluded that she had a giant adenoma of the pituitary gland which compressed to her optic chiasm. From her pituitary laboratory hormone panel, it is revealed that the tumor is a non-functioning pituitary adenoma. From the neuro-ophthalmology (campimetry) examinations, she had papillae atrophy in her both eyes and also bilateral temporal hemianopia.

The patient underwent transphenoidal removal surgery in June 2016, followed by laboratory and imaging evaluations afterward. The surgery was repeated three times due to recurrence detected by headache and worsening

visual field and imaging; in November 2006 and April 2017 (both transphenoidal removal surgery) and the last surgery was done in November 2019 with craniotomy removal surgery techniques. All of the histopathology of the pituitary gland is benign pituitary adenoma. Since the pituitary mass still reside and recur, pituitary team decided to radiate the recurrence pituitary adenoma with 30 doses of external beam radiotherapy (EBRT) at the department of oncology radiation in March 2020.

After 30 doses of external radiation, from the hormonal examinations, the morning cortisol serum was 0.9 mcg/dL (normal 3.7 – 19.4 mcg/dL) and Adrenocorticotrophic Hormone (ACTH) was < 0.1 pg/mL (normal 7.2 – 63.3 pg/mL), indicate that she had a secondary adrenal insufficiency. This condition was treated by substitution of oral steroid. Other pituitary

hormones i.e. Luteinizing Hormone (LH), Follicle Stimulating Hormone (FSH), Thyroid Stimulating Hormone (TSH) were at the normal range.

Right now, the patient still complaining for her visual field loss, but no severe or extraordinary headache was perceived. Dynamic pituitary magnetic resonance imaging (MRI) 6 months and 1 year after external radiotherapy revealed that the size of the tumor is growing larger than before. Pituitary MRI explained there is a solid mass (size 6.4 x 6.3 x 4.2 cm) in axial and extra-axial of sella and parasella region, filled the sphenoidal sinus to left spatial and exert to surrounding intracranial structures. This condition is diagnosed with recurrence giant pituitary adenoma after four times surgery and optimal dose of external radiotherapy. It is a very rare, difficult, yet challenging case to resolve.

Prevalence of pituitary tumors is 80-100 cases per 100,000 with incidence 4 new cases in 100,000 each year. Generally, pituitary tumors are common and easily treated by surgery and medical treatments. But, a small subset of pituitary tumors is classified as aggressive based on resistance to medical treatment and multiple recurrences despite standard therapies such as surgery, pharmacology, and external radiotherapy.<sup>1</sup> At least 50% of surgically resected non-functioning pituitary adenomas will recur.<sup>2</sup> About 30% of patients will show tumor regrowth 0.4-37 years after surgery. The risk of progression is higher in the case of residual tumor and extrasella region.<sup>1</sup>

Our patient experienced recurrence detected by sign and symptom of worsening of her visual field and by the evaluation of imaging study (MRI) which done every 6 months after surgery. After four times of surgery (one of which by craniotomy procedure) and 30 doses of external radiotherapy, the tumor still regrowth in a not so long-time evaluation.

There are some options for recurrence and aggressive non-functioning pituitary adenoma, such as surgery revision, external radiotherapy, and medical treatments. Surgical revision is eventually needed in 30-50% of non-functioning pituitary adenomas after surgery.<sup>3</sup> However, this is not an option for our patient because we have

done four removal surgeries before. External radiotherapy may look a good option since the efficacy is doubtless and late radiotherapy seems as effective as early treatment for local control.<sup>3</sup> But again, our patient has undergone 30 doses of radiotherapy last year. So, in our pituitary team meeting, panel experts suggest the patient will not undergo surgery and external radiotherapy anymore. Medical and palliative therapy is the treatment of choice at this point.

Clinical Practice Guidelines from European Society for Endocrinology (ESE) has published recommendations for medical treatments for aggressive and recurrence pituitary adenoma. They recommend the use of temozolomide as first line chemotherapy. The standard dose regimen is 150-200 mg/m<sup>2</sup> for 5 consecutive days every 28 days. First evaluation of treatment response must be done after 3 cycles.<sup>1</sup> If radiological progression is demonstrated, temozolomide treatment should be ceased. It has been suggested to examine MGMT status by immunohistochemistry by an expert neuropathologist. Low expression of MGMT content in immunohistochemistry correlate with more positive response to temozolomide.<sup>4</sup> However, a trial of temozolomide may be considered in patients with high MGMT expression. Combination of temozolomide and other chemotherapy drugs such as capecitabine, thalidomide, and bevacizumab is also being reported in case reports, but the efficacy is still need to study further.<sup>1</sup>

Another drug which can be used is cabergoline, a dopamine agonist usually used for treating prolactinoma. In difficult and recurrence pituitary tumors, cabergoline can be an option.<sup>3</sup> Recently, researcher have conducted a randomized clinical trial which showed cabergoline as an effective drug for treating residual non-functioning pituitary adenoma. Cabergoline shows 70% efficacy for shrinking non-functioning pituitary adenomas.<sup>5</sup> Since medical treatment was the only option for our patient at this point, we give cabergoline and plan to carry out immunohistochemistry (MGMT staining) for the patient as a requirement for our patient to get temozolomide from our national health insurance.

**REFERENCES**

1. Raverot G, Burman P, McCormack A, et al. European Society of Endocrinology Clinical Practice Guidelines for the management of aggressive pituitary tumours and carcinomas. *Eur J Endocrinol.* 2018;178:G1-24.
2. Delgado-Lopez PD, Pi-Barrio J, Duenas-Polo MT, Gordon-Bolanos MC. Recurrent non-functioning pituitary adenomas: a review on the new pathological classification, management guidelines and treatment options. *Clin Transl Oncol.* 2018;20(10):1233-45.
3. Hayhurst C, Taylor PN, Lansdown AJ, Palaniappan N, Rees DA, Davies JS. Current perspectives on recurrent pituitary adenoma: The role and timing of surgery vs adjuvant treatment. *Clin Endocrinol (Oxf).* 2020;92(2):89-97.
4. Kontogeorgos G, Thodou E. Is MGMT the best marker to predict response of temozolomide in aggressive pituitary tumors? Alternative markers and prospective treatment modalities. *Hormones (Athens).* 2019;18(4):333-7.
5. Lin S, Zhang A, Zhang X, Wu ZB. Treatment of pituitary and other tumours with cabergoline: new mechanisms and potential broader applications. *Neuroendocrinology.* 2020;110(6):477-88.