

Obstructive Jaundice as a Complication of Macrocystic Serous Cystadenoma of the Pancreas

Hendra Koncoro, I Komang W. D. Putra, I Dewa N. Wibawa

Department of Internal Medicine, Faculty of Medicine, University of Udayana - Sanglah Hospital, Denpasar, Bali, Indonesia.

Corresponding Author:

Hendra Koncoro, MD. Division of Gastroentero-hepatology, Department of Internal Medicine, Faculty of Medicine, University of Udayana - Sanglah Hospital. Jl. Sanglah, Denpasar 80114, Bali, Indonesia. email: hendra_koncoro@yahoo.com.

ABSTRAK

Kistadenoma serosa makrokistik merupakan tumor pankreas yang jarang dijumpai dan umumnya jinak. Pada laporan kasus ini, dilaporkan wanita berusia 40 tahun yang didiagnosis kistadenoma serosa makrokistik dengan keluhan ikterus obstruktif. Lesi kistik pada bagian caput dan corpus pankreas ditunjukkan dengan CT abdomen. Aspirasi kista pankreas intraoperatif menyingkirkan neoplasma kistik musinosa yang memiliki potensi ganas. Sitologi cairan kista pankreas menunjukkan bahan amorf basofilik yang disimpulkan sebagai lesi kistik jinak. Drainase internal dilakukan alih-alih reseksi pankreas yang menunjukkan hasil yang baik. Obstruksi bilier merupakan komplikasi yang jarang dijumpai pada kistadenoma serosa. Kasus ini menggambarkan tampilan klinis tidak lazim dari kistadenoma serosa makrokistik.

Kata kunci: *kistadenoma serosa makrokistik, pankreas, ikterus obstruktif.*

ABSTRACT

Macrocystic serous cystadenoma is an unusual and essentially benign pancreatic tumor. Herein, we report on a 40-year-old woman diagnosed with macrocystic serous cystadenoma who presented with obstructive jaundice. A cystic lesion in the head and body of the pancreas was revealed by abdominal computed tomography. Intraoperative pancreatic cyst aspiration ruled out mucinous cystic neoplasm which has a malignant potential. The pancreatic cyst fluid cytology was basophilic amorph materials concluded as benign cystic lesion. Internal drainage was performed instead of pancreatic resection which showed good outcome. Biliary obstruction is a rare complication of serous cystadenoma. This case describes an unusual clinical presentation of macrocystic serous cystadenoma.

Keywords: *macrocystic serous cystadenoma, pancreas, obstructive jaundice.*

INTRODUCTION

Cystic neoplasms of the pancreas are uncommon, representing approximately 10-15% of all pancreatic cystic lesions and account for 1% of pancreatic malignancy.^{1,2} In 1978, Compagno and Oertel issued an histopathologic classification of cystic neoplasms of the pancreas

identifying two different types of cyst. The first type is serous cystadenoma (SCA) with benign behavior.³ Mucinous cystic neoplasms of the pancreas are the other type of lesions and possess the more frequent ability to transform into malignant condition.⁴ Previously, SCA were also known as microcystic adenomas. However,

in 1992 Lewandowski et al reported a variant coined as macrocystic SCA.⁵ The macrocystic subtype of SCA has been reported only on rare occasions.⁵⁻⁷ Preoperative diagnosis of macrocystic SCA by physical examination and radiologic studies is difficult.^{7,8} The imaging of a macrocystic SCA may resemble a pseudocyst or a mucinous cystadenoma.⁷⁻⁹ Thus, it is often difficult to make a correct diagnosis. Biliary obstruction is a rare complication of SCA and only a few cases have been reported.¹⁰ We herein report a case of pancreatic SCA causing obstructive jaundice, which we treated successfully by an internal drainage procedure.

CASE ILLUSTRATION

A 40-year-old Balinese female who had suffered from jaundice since mid-January 2012, was hospitalized in our department on February 9, 2012. The complaint was accompanied by intense itching, dark urine and fatigue. She reported anorexia with waxing and waning upper abdominal pain for about 1 year. Abdominal pain was felt on her epigastrium and not penetrated to her back. The patient had no history of alcohol consumption nor abdominal trauma. Physical examination revealed the following: height 165 cm; body weight 55 kg; body temperature 37.2°C; blood pressure 120/84 mmHg. Her skin and conjunctiva were jaundiced. There was upper abdominal mass palpable sized 8 x 9 cm. There was no ascites or leg edema.

Blood and biochemical test on admission showed the following abnormalities: white blood cells 9800/mm³; total bilirubin 11.85 mg/dl; direct bilirubin 11.55 mg/dl; amylase 145 U/l; alkaline phosphatase 706 U/l; gamma-glutamyl transferase 349 IU/l; aspartate aminotransferase 69,7 IU/l; alanine aminotransferase 113.9 IU/l. The serum tumor markers, carcinoembryogenic antigen (CEA) and carbohydrate antigen (CA) 19-9 were not elevated. Abdominal ultrasonography (US) showed dilation of the intrahepatic bile duct and common bile duct (CBD) and multiple hypoechoic mass in the pancreas (**Figure 1**). An abdominal CT scan showed multiple well-defined hypodense cystic lesion of pancreas with the largest cyst sized 6.7 x 9 cm. Gallbladder enlargement was also

shown (**Figure 2**). These findings were highly suggestive of pancreatic cystic lesion causing stenosis of the CBD and obstructive jaundice. Swelling of the pancreatic cysts around the CBD had caused severe stenosis and sludge of bile had formed, resulting in obstructive jaundice.

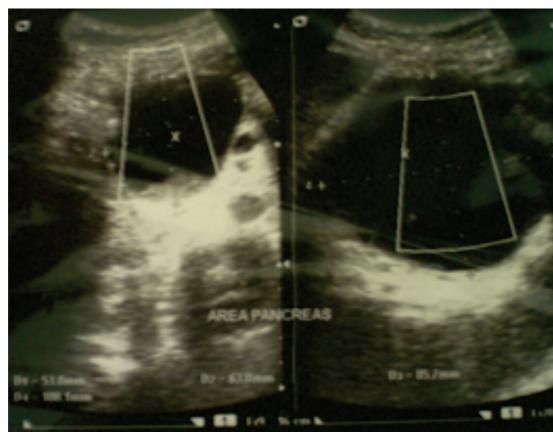


Figure 1. Transabdominal ultrasonography revealed pancreatic cysts.

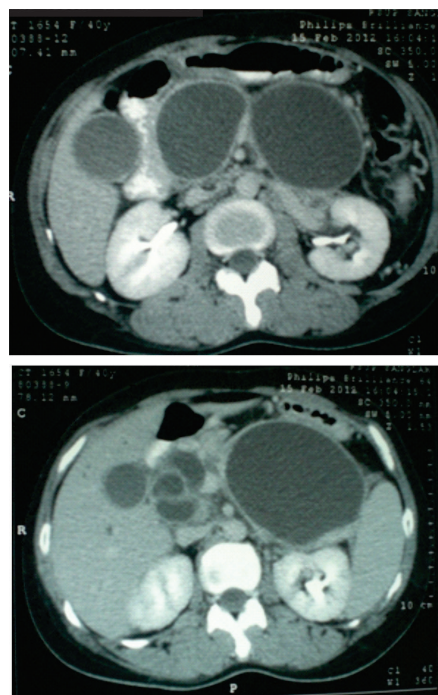


Figure 2. Abdominal CT (axial section) with contrast showing multiple well-defined hypodense, cystic lesion in the pancreas.

Laparotomy showed a multicystic tumor arising from the head and body of the pancreas, with no evidence of metastatic disease. Intraoperative pancreatic cyst aspiration

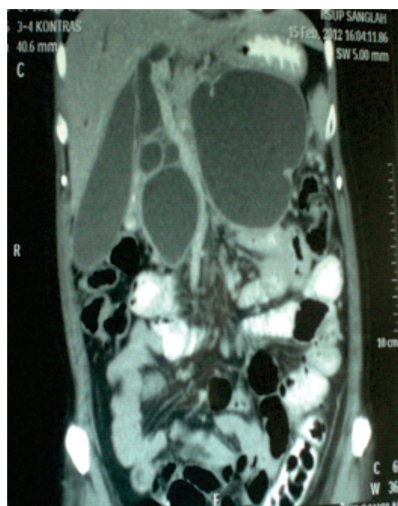


Figure 3. Findings on CT (coronal section). Gallbladder seen greatly distended and multiple cystic lesion in the pancreas.

was performed and caused them to shrink and improved the compressive effect on choledochal duct. Internal drainage was done by cystojejunostomy. Aspiration revealed a clear watery fluid. Microscopically, pancreatic cyst fluid cytology was basophilic amorph material without any mucinous columnar epithelial cells concluded as benign cystic lesion (**Figure 4**). Therefore, the tumor was diagnosed to be a macrocystic serous cystadenoma of the pancreas. The postoperative course was uneventful. At last follow-up 1 year post-operatively, the patient is doing well without clinical or radiographic evidence of recurrent disease.

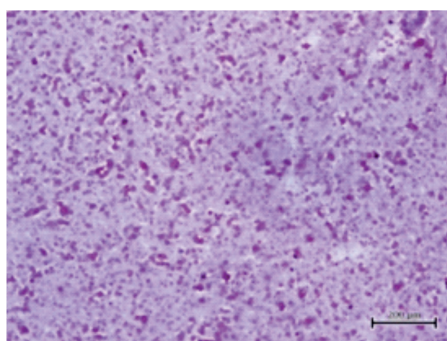


Figure 4. Basophilic amorph materials concluded as benign cystic lesions.

DISCUSSION

Pancreatic cystic lesions contribute to 10% of all pancreatic cysts.^{2,3} In 1978, Compagno et al.⁴

classified cystic neoplasms of pancreas as serous cystadenomas and mucinous cystic neoplasms.^{3,4} SCA of the pancreas is an uncommon and essentially benign tumor. It consists of a predominantly microcystic architecture lined by a layer of cuboidal epithelium with rounded and uniform nuclei, and clear cytoplasm containing a large amount of glycogen.³ SCA has macrocystic variant which consists of six cysts or less with diameter sized more than 2 cm (unilocular, oligocystic).⁵

Pancreatic macrocystic SCA has to be differentiated with other pancreatic cystic lesions such as pseudocysts or mucinous cystic neoplasms.¹ Cysts in other sites need to be explored to rule out the possibility of Von Hippel Lindau disease.¹¹

It is important to establish a correct diagnosis before surgery so that appropriate surgical management can be done.⁹ However, it seems difficult to make the distinction by imaging studies preoperatively, and almost all cases are diagnosed after surgery by histologic examination.¹² Borgne reviewed 389 cases of cystadenoma of the pancreas based on their imaging findings and concluded that correct diagnosis of macrocystic SCA by preoperative imaging was only 20%.¹³ Lewandrowski et al also found that the radiological features of their 5 cases of macrocystic SCA were indistinguishable from those of mucinous cystic neoplasms, and when unilocular, could be confused with pseudocysts.⁵ Pseudocyst may be diagnosed by a history of pancreatitis with unilocular cyst appearance on computed tomography scan and typical fluid cyst analysis.^{12,14}

SCA also had to be differentiated from mucinous cystic neoplasms. Mucinous cystic neoplasms should always be resected due to tendency towards malignancy. Management of SCA was not as radical as mucinous cystic neoplasms since SCA were considered to be tumors with no potential for malignant transformation. Multilocular cyst and pancreatic cyst fluid analysis which showed no inflammatory cells and low amylase content were common occurrences in SCA and mucinous cystic neoplasms. Differences between both type of cysts are viscosity and cytologic analysis of

cyst fluid. The cyst fluids of mucinous cystic neoplasms were mucoid and viscous on gross inspection with cytologic preparations showed mucinous columnar epithelial cells with high content of mucin.^{12,14-16}

In our case, from clinical appearance there was jaundice with recurrent abdominal pain without history of pancreatitis and mass in epigastrium. Radiologic findings showed well-defined multiple hypodens cystic lesions in pancreas with largest cyst sized 6.7 x 9 cm. Clinical appearance and radiologic findings supported the diagnosis of a pancreatic cystic lesion. Pseudocysts may be ruled out due to negative findings of abdominal pain which penetrated to back typical of pancreatitis with radiologic findings of multilocular cysts. Therefore, diagnosis may be tighten into pancreatic cystic lesion with differential diagnosis of macrocystic SCA and mucinous cystic neoplasm.

Laparotomy was done on this patient followed by intraoperative pancreatic cyst fluid aspiration. Aspiration caused the cysts to shrink and relieved the compressive effect on the choledochal duct. Pancreatic cyst aspiration showed clear fluid with watery consistency. Intraoperative diagnosis lead to possibility of macrocystic SCA, therefore pancreatic resection was not done in this case. Pancreatic resection carries a much higher risk of complications and mortality especially in centers with low experience with pancreatic surgery.^{17,18} If pseudocysts or SCA are considered, often other modalities are better than resection.¹⁵ Therefore, we performed the cyst aspiration, did internal drainage and continued with cystojejunostomy. The histologic examination showed neither malignant cells nor mucinous epithelial cells which concluded the findings as SCA. Amylase content and tumor marker of the fluid was not done due to limited facilities. Low level of fluid amylase, CA 19-9, and CEA might confirm the diagnosis of SCA.^{14,16,17}

Neither clinical findings of cystic swelling nor obstructive jaundice have been found by radiology or laboratory data for more than 1 year follow-up. Cyst aspiration followed by internal drainage may be a better palliative option for treating benign compressive tumors such as macrocystic SCA of the pancreas causing

obstructive jaundice since chances of malignancy in SCA are no more than 1%.^{19,20} Watanabe described a case of macrocystic SCA causing obstructive jaundice successfully managed by cystic fenestration. No recurrence of SCA has been detected in that case for more than 2 years since the cystic fenestration.¹⁹

CONCLUSION

We reported a case of rare presentation of biliary obstruction caused by pancreatic serous cystadenoma. Although very rare, serous macrocystic adenoma might appear with complication of obstructive jaundice and has to be taken into consideration in differential diagnosis of cystic lesions of the pancreas. The patient had surgical treatment to perform treated surgically, underwent cyst aspiration and internal drainage (cystojejunostomy) without resection of the pancreas. The patient had a great improvement during follow-up after the surgery.

REFERENCES

1. Sharma A. Tumors of the pancreas. In: Greenberger NJ, Blumberg RS, Burakoff R, eds. Current diagnosis and treatment gastroenterology, hepatology, and endoscopy. New York: McGraw-Hill; 2009. p. 310-20.
2. Ros PR, Hamrick-Turner JE, Chiechi MV, Ros LH, Gallego P, Burton SS. Cystic masses of the pancreas. *Radio Graph*. 1992;12:673-86.
3. Compagno J, Oertel JE. Microcystic adenomas of the pancreas (glycogen-rich cystadenomas). A clinicopathologic study of 34 cases. *Am J Clin Pathol*. 1978;69:289-98.
4. Compagno J, Oertel J. Mucinous cystic neoplasms of the pancreas with overt and latent malignancy (cystadenocarcinoma and cystadenoma): a clinicopathologic study of 41 cases. *Am J Clin Pathol*. 1978;69:573-80.
5. Lewandrowski K, Warshaw A, Compton C. Macrocystic serous cystadenoma of the pancreas. A morphologic variant differing from microcystic adenoma. *Hum Pathol*. 1992;23:871-5.
6. Egawa N, Maillet B, Schroder S, Mukai K, Kloppel G. Serous oligocystic and ill-demarcated adenoma of the pancreas: a variant of serous cystic adenoma. *Virchows Arch*. 1994;424:13-7.
7. Gouhiri M, Soyer P, Barbagelatta M, Rymer R. Macrocystic serous cystadenoma of the pancreas: CT and endosonographic features. *Abdom Imaging*. 1999;24(1):72-4.
8. Khadaroo R, Knetman N, Joy S, Nguyen GK. Macrocystic serous adenoma of the pancreas. *Pathol*

- Res Pract. 2002;198:485-8.
9. Hsieh YY, Hsueh S, Chen RJ, Hsueh C. Macrocystic serous cystadenoma of the pancreas in a young patient resembling a pseudocyst: Case report and literature review. *Chang Gung Med J.* 2003;26(8):602-6.
 10. Horaguchi J, Fujita N, Kobayashi G, Noda Y, Kimura K, Ito K, et al. Serous cystadenoma of the pancreas associated with obstructive jaundice. *J Gastroenterol.* 2003;38(5):501-6.
 11. Jakhere SG, Yeragi B, Jain DG. Von Hippel Lindau (VHL) disease: Magnetic resonance imaging spectrum in a single patient. *Acta Med Indones.* 2012;44(4):324-6.
 12. Bhutani MS, Gupta V, Gusha S, Gheonea DI, Saffoiu A. Pancreatic cyst fluid analysis – a review. *J Gastrointestinal Liver Dis.* 2011;20:175-80.
 13. Le Borge J, de Calan L, Partensky C. Cystadenoma and cystadenocarcinomas of the pancreas: A multiinstitutional retrospective study of 398 cases. *Ann Surg.* 1999;230:152-61.
 14. Lewandrowski KB, Southern JF, Pins MR, Compton CC, Warshaw AL. Cyst fluid analysis in the differential diagnosis of pancreatic cysts. *Ann Surg.* 2003;217(1):41-7.
 15. Park WG. Screening for pancreatic cancer: what can cyst fluid analysis tell us? *F1000 Med Rep.* 2011;3:3.
 16. Ng DZ, Goh BK, Tham EH, Young SM, Ooi LL. Cystic neoplasms of the pancreas: Current diagnostic modalities and management. *Ann Acad Med Sing.* 2009;38:251-9.
 17. Goldsmith JD. Cystic neoplasms of the pancreas. *Am J Clin Pathol.* 2003;119(1):S3-16.
 18. Pyke CM, Van Heerden JA, Colby TV, Sarr MG, Weaver AL. The spectrum of serous cystadenoma of the pancreas: Clinical, pathologic, and surgical aspects. *Ann Surg.* 1992;215(2):132-9.
 19. Watanabe H, Ohtsubo K, Yamaguchi Y, Mouri H, Motoo Y, Noto M, et al. Successful cystic fenestration for macrocystic serous cystadenoma of the pancreas causing obstructive jaundice: report of a case. *Surg Today.* 2006;36(1):89-93.
 20. Tseng JF, Warshaw AL, Sahani DV, Lauwers GY, Rattner DW, Castillo CF. Serous cystadenoma of the pancreas: tumor growth rates and recommendations for treatment. *Ann Surg.* 2005;242:413-21.